

AGENDA

A REGULAR MEETING OF THE BOARD OF RETIREMENT
LOS ANGELES COUNTY EMPLOYEES RETIREMENT ASSOCIATION
300 N. LAKE AVENUE, SUITE 810, PASADENA, CA
9:00 A.M., WEDNESDAY, OCTOBER 7, 2015

- I. CALL TO ORDER
- II. PLEDGE OF ALLEGIANCE
- III. APPROVAL OF MINUTES
 - A. Approval of the Minutes of the Regular Meeting of September 2, 2015
- IV. REPORT ON CLOSED SESSION ITEMS
- V. PUBLIC COMMENT
- VI. CONSENT AGENDA
 - A. Ratification of Service Retirement and Survivor Benefit Application Approvals.
 - B. Requests for an administrative hearing before a referee.
(Memo dated September 24, 2015)
 - C. Recommendation as submitted by Ricki Contreras, Division Manager, Disability Retirement Services: That the Board dismiss with prejudice the appeal for service-connected disability retirement in the case of **Arnecy L. Hall**.
(Memo dated September 17, 2015)

VI. CONSENT AGENDA (Continued)

D. Recommendation as submitted by Vivian H. Gray, Chair, Disability Procedures & Services Committee: That the Board approve Roger Sohn, M.D. – Board Certified Orthopedist to the LACERA Panel of Physicians for the purpose of examining disability retirement applicants.
(Memo dated September 17, 2015)

E. For information only as submitted by Ricki Contreras, Division Manager, Disability Retirement Services regarding the Application Processing Time Snapshot Reports.
(Memo dated September 22, 2015)

VII. GOOD OF THE ORDER
(For information purposes only)

VIII. DISABILITY RETIREMENT APPLICATIONS ON CONSENT CALENDAR

IX. DISABILITY RETIREMENT CASES TO BE HELD IN CLOSED SESSION

A. Applications for Disability

B. Referee Reports

C. Staff Recommendations

1. Recommendation as submitted by JJ Popowich, Assistant Executive Officer: That the Board approve the service provider invoice for Gutierrez, Preciado & House, LLP.
(Memo dated September 23, 2015)

2. Recommendation as submitted by Francis J. Boyd, Senior Staff Counsel, Legal Division: That the Board reject Steven K. Christensen's request to file a late appeal of the Board of Retirement's August 16, 2013 decision because the Board has no legal authority to consider or reopen this decision.
(Memo dated September 25, 2015)

October 7, 2015

Page 3

X. EXECUTIVE SESSION

A. Conference with Legal Counsel - Pending Litigation
(Pursuant to Paragraph (1) of Subdivision (d) of California
Government Code Section 54956.9)

1. Marina Wingenbach v. LACERA, et al.
Los Angeles Superior Court Case No. BC 593615
2. Gloria Arellanes v. Board of Retirement

XI. ADJOURNMENT

Documents subject to public disclosure that relate to an agenda item for an open session of the Board of Retirement that are distributed to members of the Board of Retirement less than 72 hours prior to the meeting will be available for public inspection at the time they are distributed to a majority of the Board of Retirement Members at LACERA's offices at 300 N. Lake Avenue, Suite 820, Pasadena, CA 91101, during normal business hours of 9:00 a.m. to 5:00 p.m. Monday through Friday.

Persons requiring an alternative format of this agenda pursuant to Section 202 of the Americans with Disabilities Act of 1990 may request one by calling Cynthia Guider at (626) 564-6000, from 8:30 a.m. to 5:00 p.m. Monday through Friday, but no later than 48 hours prior to the time the meeting is to commence. Assistive Listening Devices are available upon request. American Sign Language (ASL) Interpreters are available with at least three (3) business days notice before the meeting date.

MINUTES OF THE REGULAR MEETING OF THE BOARD OF RETIREMENT

LOS ANGELES COUNTY EMPLOYEES RETIREMENT ASSOCIATION

300 N. LAKE AVENUE, SUITE 810, PASADENA, CA

9:00 A.M., WEDNESDAY, SEPTEMBER 2, 2015

PRESENT: Shawn R. Kehoe, Chair

 Alan Bernstein, Vice Chair

 William de la Garza, Secretary

 Anthony Bravo

 Yves Chery

 Vivian H. Gray (Arrived at 9:02 a.m.)

 Joseph Kelly

 David L. Muir (Alternate Retired)

 Ronald A. Okum

 William Pryor (Alternate Member) (Arrived at 9:02 a.m.)

ABSENT: Les Robbins

STAFF ADVISORS AND PARTICIPANTS

Gregg Rademacher, Chief Executive Officer

Dr. Vito Campese, Medical Advisor

Steven Rice, Chief Counsel

Ricki Contreras, Division Manager
Disability Retirement Services

Tamara Caldwell, Specialist Supervisor
Disability Retirement Services

STAFF ADVISORS AND PARTICIPANTS (Continued)

Francis J. Boyd, Senior Staff Counsel
Legal Division

Steven Tallant, Senior Staff Counsel
Disability Litigation

Allison E. Barrett, Senior Staff Counsel
Disability Litigation

Thomas J. Wicke, Attorney at Law
Lewis, Marenstein, Wicke & Sherwin, LLP

Thomas L. Hoegh, Attorney at Law

I. CALL TO ORDER

The meeting was called to order by Chair Kehoe at 9:00 a.m., in the Board Room of Gateway Plaza. Chair Kehoe shared that Mr. Robbins is on vacation.

II. PLEDGE OF ALLEGIANCE

Chair Kehoe led the Board Members and staff in reciting the Pledge of Allegiance.

III. APPROVAL OF MINUTES

A. Approval of the Minutes of the Regular Meeting of August 5, 2015

Mr. de la Garza made a motion, Mr. Muir seconded, to approve the minutes of the regular meeting of August 5, 2015. The motion passed with Mr. de la Garza and Chair Kehoe abstaining.

IV. REPORT ON CLOSED SESSION ITEMS

There was nothing to report.

V. PUBLIC COMMENT

There were no requests from the public to speak.

VI. CONSENT AGENDA (Ms. Gray and Mr. Pryor arrived at 9:02 a.m.)

Mr. Chery made a motion, Mr. Bernstein seconded, to approve the following agenda items. The motion passed unanimously.

- A. Ratification of Service Retirement and Survivor Benefit Application Approvals.
- B. Requests for an administrative hearing before a referee.
(Memo dated August 20, 2015)
- C. Recommendation as submitted by Ricki Contreras, Division Manager, Disability Retirement Services: That the Board dismiss with prejudice the appeal for service-connected disability retirement in the case of **Narcisso K. Flores-Bassinger**. (Memo dated August 18, 2015)
- D. Recommendation as submitted by Vivian H. Gray, Chair, Disability Procedures & Services Committee: That the Board approve Peter Gleiberman, M.D. – Board Certified Orthopedist to the LACERA Panel of Physicians for the purpose of examining disability retirement applicants. (Memo dated August 18, 2015)
- E. For information only as submitted by Ricki Contreras, Division Manager, Disability Retirement Services regarding the Application Processing Time Snapshot Reports. (Memo dated August 20, 2015)

VII. GOOD OF THE ORDER

(For information purposes only)

The Board congratulated Chair Kehoe and his wife on the birth of their twins.

Mr. Kelly shared his experience in attending the CALAPRS Principles of Pension

VII. GOOD OF THE ORDER (Continued)

Management in Malibu, CA.

VIII. DISABILITY RETIREMENT APPLICATIONS ON CONSENT
CALENDAR

Safety Law Enforcement
Service-Connected Disability Applications

On a motion by Chair Kehoe, seconded by Mr. Okum, the Board of Retirement approved a service-connected disability retirement for the following named employees who were found to be disabled for the performance of their duties and have met the burden of proof:

<u>APPLICATION NO.</u>	<u>NAME</u>
372C*	RICHARD A. HARTLEY
373C**	GERALD A. HOLT, JR.
374C	MINDY A. JEFFERY
375C	SALVADOR VELASQUEZ
376C	MICHAEL C. WALDMAN
377C*	ANTHONY J. HAWKINS
378C	STEVEN V. ESCHAGARY
379C	ALAN L. BASH
380C**	THOMAS E. DOBIS
381C	THOMAS L. ECKERT

*Granted SCD – Retroactive

** Granted SCD – Employer Cannot Accommodate

VIII. DISABILITY RETIREMENT APPLICATIONS ON CONSENT
CALENDAR

Safety-Fire, Lifeguard
Service-Connected Disability Applications

On a motion by Mr. Okum, seconded by Mr. Bernstein, the Board of Retirement approved a service-connected disability retirement for the following named employees who were found to be disabled for the performance of their duties and have met the burden of proof:

<u>APPLICATION NO.</u>	<u>NAME</u>
1700A	FRED A. BLAND
1701A*	WILLIAM J. REIMER, JR.
1702A	LINCOLN S. LUCERO
1703A	ADRIAN L. MEADOWS

General Members
Service-Connected Disability Applications

On a motion by Mr. Chery, seconded by Mr. Kelly, the Board of Retirement approved a service-connected disability retirement for the following named employees who were found to be disabled for the performance of their duties and have met the burden of proof:

<u>APPLICATION NO.</u>	<u>NAME</u>
2547B*	ROBERT T. TOSH

* Granted SCD – Employer Cannot Accommodate

VIII. DISABILITY RETIREMENT APPLICATIONS ON CONSENT
CALENDAR

General Members (Continued)
Service-Connected Disability Applications

<u>APPLICATION NO.</u>	<u>NAME</u>
2548B	MIRTHA R. TUCKLER
2549B*	ELVIA CORONEL
2550B	LUISA A. DIAZ
2551B	KENNETH W. WASHINGTON
2552B**	ANTHONY A. MATHIS
2553B***	JAMES A. LOPEZ
2554B***	KENYETTA V. DAVIS
2555B**	ANTHONY D. PORTER
2556B*	DENISE M. NAPIWOCKI
2557B	VIRGINIA A. LEON

*Granted SCD – Retroactive

** Granted SCD – Employer Cannot Accommodate

*** Granted SCD – Salary Supplement

VIII. DISABILITY RETIREMENT APPLICATIONS ON CONSENT CALENDAR

Safety Members

Non-Service Connected Disability Applications

On a motion by Chair Kehoe, seconded by Mr. Bernstein, the Board of Retirement approved a non-service connected disability retirement for the following named employees who were found to be disabled for the performance of their duties and have met the burden of proof:

APPLICATION NO.

NAME

3011

JAMES R. BLAKE

IX. DISABILITY RETIREMENT CASES TO BE HELD IN CLOSED SESSION

A. Applications for Disability

APPLICATION NO. & NAME

BOARD ACTION

6837A – REBECCA S. MADERA*

Mr. de la Garza made a motion, Mr. Okum seconded, to grant a non-service connected disability retirement pursuant to Government Code Sections 31720 and 31724. The motion passed unanimously.

6838A – DORIE P. MELLO

Mr. Bernstein made a motion, Mr. de la Garza seconded, to deny a service connected disability retirement and find the applicant not permanently incapacitated.

* Applicant Present

IX. DISABILITY RETIREMENT CASES TO BE HELD IN CLOSED SESSION

A. Applications for Disability (Continued)

APPLICATION NO. & NAME

BOARD ACTION

6838A – DORIE P. MELLO (Continued)

Ms. Gray made a substitute motion, Mr. Chery seconded, to refer back to staff for additional information. The motion failed (roll call) with Messrs. Bravo, Chery, and Ms. Gray voting yes; and Messrs. Kelly, Bernstein, Okum, de la Garza and Kehoe voting no.

The motion to deny a service connected disability retirement and find the applicant not permanently incapacitated passed with Ms. Gray voting no.

6839A – MICHELLE R. HAGGARD*

Mr. Okum made a motion, Ms. Gray seconded, to grant a non-service connected disability retirement pursuant to Government Code Sections 31725.5 and 31720. The motion passed unanimously.

6840A – MICHAEL J. LEINWEBER

Mr. Okum made a motion, Mr. de la Garza seconded, to grant a non-service connected disability retirement pursuant to Government Code Section 31720. The motion passed unanimously.

* Applicant Present

IX. DISABILITY RETIREMENT CASES TO BE HELD IN CLOSED SESSION

A. Applications for Disability (Continued)

<u>APPLICATION NO. & NAME</u>	<u>BOARD ACTION</u>
6841A – CYRIL H. LEGENDRE	Ms. Gray made a motion, Mr. Chery seconded to grant a service connected disability retirement. Mr. Bernstein made a substitute motion, Mr. Kelly seconded, to refer back to staff for additional information. The motion passed unanimously.
6842A – JERRY BROWN	Chair Kehoe made a motion, Mr. Bernstein seconded, to refer back to staff for additional information. The motion passed unanimously.
2302B – YOLANDA R. BELL	Mr. Kelly made a motion, Ms. Gray seconded, to continue the service connected disability retirement. The motion passed unanimously.
6688A – JOSEPH P. RUGGIERO, JR.*	Chair Kehoe made a motion, Ms. Gray seconded, to grant a service connected disability retirement pursuant to Government Code Section 31720. The motion passed unanimously.
6736A – MALISSA J. APODACA	Chair Kehoe made a motion, Mr. Chery seconded, to deny a service connected disability retirement without prejudice and find the applicant not permanently incapacitated. The motion passed unanimously.

* Applicant Present

IX. DISABILITY RETIREMENT CASES TO BE HELD IN CLOSED SESSION

A. Applications for Disability (Continued)

APPLICATION NO. & NAME

BOARD ACTION

6827A – BERTHA F. LUNA

Mr. Bernstein made a motion, Mr. Kelly seconded, to grant a non-service connected disability retirement pursuant Government Code Section 31720. The motion passed unanimously.

6815A – N4102DRAC

Mr. Muir made a motion, Mr. Kelly seconded, to deny a service connected disability retirement since the employer can accommodate. The motion passed unanimously.

B. Referee Reports

APPLICATION NO. & NAME

BOARD ACTION

Henry W. Jansen III – Thomas J. Wicke for applicant
Steven Tallant for respondent

Mr. Bernstein made a motion, Mr. Okum seconded, to deny a service connected disability retirement and find the applicant not disabled.

Mr. Bravo made a substitute motion, Ms. Gray seconded, to refer back to staff for additional information. The motion failed (roll call) with Messrs. Kehoe, Bravo, Chery, and Ms. Gray voting yes; and Messrs. Kelly, Bernstein, Okum, and de la Garza voting no.

Chair Kehoe made a motion, Mr. Muir seconded, to deny a service connected

IX. DISABILITY RETIREMENT CASES TO BE HELD IN CLOSED SESSION

B. Referee Reports (Continued)

APPLICATION NO. & NAME

BOARD ACTION

Henry W. Jansen III (Continued)

disability retirement. The motion failed (roll call) with Messrs. Kelly, Bernstein, Okum, and de la Garza voting yes; and Messrs. Kehoe, Bravo, Chery, and Ms. Gray voting no.

This appeal will be placed on next month's Board agenda.

Linda M. Hagstrom – Thomas L. Hoegh for applicant
Allison E. Barrett for respondent

Mr. Chery made a motion, Mr. Kelly seconded, to deny a non-service connected disability retirement and service connected disability retirement since the employer can accommodate. The motion passed with Ms. Gray voting no.

C. Staff Recommendations

1. Recommendation as submitted by Ricki Contreras, Manager, Disability Retirement Services: That the Board adopt the Proposed Findings of Fact and Conclusions of Law granting **Irene Muro (Valencia/Sauers)** a service-connected disability retirement. (Memo dated August 18, 2015)

Mr. Muir made a motion, Chair Kehoe seconded, to approve the recommendation. The motion passed unanimously.

IX. DISABILITY RETIREMENT CASES TO BE HELD IN CLOSED SESSION

C. Staff Recommendations (Continued)

2. Recommendation as submitted by Allison E. Barrett, Senior Staff Counsel, Disability Litigation: That the Board find the service-connected disability retirement application of **Bruce Arvizu** be deemed filed on the day after the last day of regular compensation in accordance with Government Code Section 31724.
(Letter dated August 12, 2015)

Mr. de la Garza made a motion, Mr. Okum seconded, to approve the recommendation. The motion passed unanimously.

3. Recommendation as submitted by Vincent A. Lim, Chief Counsel, Disability Litigation: That the Board find the service-connected disability retirement application of **Victoria Restrepo** be deemed filed on the day after the last day of regular compensation in accordance with Government Code Section 31724.
(Letter dated August 17, 2015)

Mr. Okum made a motion, Ms. Gray seconded, to approve the recommendation. The motion passed unanimously.

X. EXECUTIVE SESSION

- A. Conference with Legal Counsel - Existing Litigation
(Pursuant to Paragraph (1) of Subdivision (d) of California Government Code Section 54956.9)

1. Michael Furman v. LACERA

The Board met in Executive Session pursuant to Government Code Section 54956.9. The Board voted unanimously to pay the attorney and court fees in this case.

September 2, 2015

Page 13

Green Folder Information (Information distributed in each Board
Members Green Folder at the beginning of the meeting)

1. Retirement Board Listing dated September 2, 2015

XI. ADJOURNMENT

There being no further business to come before the Board, the meeting was adjourned at 11:05 a.m.


WILLIAM DE LA GARZA, SECRETARY

SHAWN R. KEHOE, CHAIR



DATE: September 24, 2015

TO: Each Member
Board of Retirement

FROM: Ricki Contreras, Division Manager
Disability Retirement Services 

SUBJECT: **APPEALS FOR THE BOARD OF RETIREMENT'S MEETING
OF OCTOBER 7, 2015**

IT IS RECOMMENDED that your Board grant the appeals and requests for administrative hearing received from the following applicants and direct the Disability Retirement Services Manager to refer each case to a referee:

1698A	Eric L. Buege	Thomas J. Wicke	Grant SCD - Appealing retroactive effective date only
6810A	Adela C. Campbell	In Pro Per	Deny SCD – Not disabled
6831A	Shari Altmark	Tanya R. Garza	Deny SCD – Not disabled
6815A	Charlotte S. Nakhla	Danny T. Polhamus	Deny SCD – Employer can accommodate
6840A	Michael J. Leinweber	Mark E. Singer	Deny SCD – Grant NSCD



September 17, 2015

TO: Each Member
Board of Retirement

FROM: Ricki Contreras, Manager 
Disability Retirement Services Division

FOR: October 7, 2015 Board of Retirement Meeting

SUBJECT: **DISMISS WITH PREJUDICE THE APPEAL OF ARNECY L. HALL**

Ms. Arnecy L. Hall applied for service-connected disability retirement on December 3, 2013. On February 4, 2015, the Board denied her application for service-connected disability retirement.

Ms. Arnecy L. Hall filed a timely appeal. On July 16, 2015, Ms. Hall signed a voluntary withdrawal letter advising LACERA that she does not wish to proceed with her appeal.

IT IS THEREFORE RECOMMENDED THAT YOUR BOARD:


Dismiss with prejudice Arnecy L. Hall's appeal for service-connected disability retirement.

FJB: RC: sc

Hall, Arnecy L.doc

Attachment

NOTED AND REVIEWED:



Francis J. Boyd, Sr. Staff Counsel

Date: 9/21/15

September 17, 2015

TO: Each Member
Board of Retirement

FROM: Disability Procedures & Services Committee
Vivian H. Gray, Chair
William de la Garza, Vice Chair
William R. Pryor
Les Robbins
Yves Chery, Alternate

FOR: October 7, 2015 Board of Retirement Meeting

SUBJECT: **CONSIDER APPLICATION(S) FOR LACERA PANEL OF EXAMINING
PHYSICIAN(S)**

On September 2, 2015, the Disability Procedures & Services Committee reviewed the attached application for the LACERA Panel of Examining Physicians.

The application package has been reviewed by the Committee. After discussion, the Committee voted to accept the application of the following physician and submit to the Board of Retirement for approval to the LACERA panel.

IT IS THEREFORE RECOMMENDED THAT the Board approve the following physician to the LACERA Panel of Physicians for the purpose of examining disability retirement applicants.

Roger Sohn, M.D. - Board Certified Orthopedist

Attachments

VG:RC/sc



August 21, 2015

TO: Disability Procedures & Services Committee
Vivian H. Gray, Chair
William de la Garza, Vice Chair
William R. Pryor
Les Robbins
Yves Chery, Alternate

FROM: Ricki Contreras, Manager 
Disability Retirement Services Division

FOR: September 2, 2015, Disability Procedures and Services Committee Meeting

SUBJECT: **CONSIDER APPLICATION OF ROGER SOHN, M.D., AS LACERA
PANEL PHYSICIAN**

On July 30, 2015, Debbie Semnanian interviewed Roger Sohn, M.D., a physician seeking appointment to the LACERA Panel of Examining Physicians.

Attached for your review and consideration are:

- Staff's Interview Summary and Recommendation
- Panel Physician Application
- Curriculum Vitae
- Sample Report(s).

IT IS THEREFORE RECOMMENDED THAT THE COMMITTEE accept the staff recommendation to submit the application of Roger Sohn, M.D., to the Board of Retirement for approval to the LACERA Panel of Examining Physicians.

Attachments

JJ:RC/sc

NOTED AND REVIEWED:



JJ Poppwich, Assistant Executive Officer

Date: 8/24/15



August 3, 2015

TO: **Ricki Contreras, Division Manager**
Disability Retirement Services

FROM: **Debbie Semnanian, WCCP** OS
Supervising Disability Retirement Specialist

SUBJECT: **INTERVIEW OF ORTHOPEDIC SURGEON APPLYING FOR
LACERA PHYSICIAN'S PANEL**

On July 30, 2015, I interviewed **Roger Sohn**, M.D. at his office at 2080 Century Park East #305, Los Angeles, Ca 90067. The office space is in a well-maintained high rise with underground parking for a fee located under the building.

Dr. Sohn is a board certified orthopedic surgeon who has been in private practice for over thirty years. Dr. Sohn shares office space with another orthopedist. The office has 7 complete examination rooms. Dr. Sohn estimates that 20 percent of his practice is devoted to patient treatment, while the other 80 percent of his time is devoted to IME and AME evaluations primarily within the workers' compensation systems.

As referenced in his Curriculum Vitae, Dr. Sohn graduated from the University of Southern California with his medical degree in 1977. He completed internships at Cedars-Sinai Hospital in Los Angeles in 1979, and at Tufts University in Boston in 1983, where he served as chief resident in orthopedic trauma. He was an instructor in orthopedic surgery at Harvard University School of Medicine from 1985 - 1986. Dr. Sohn has published 3 scientific articles, as well as contributed to the book, The Lower Extremity and Spine in Sports Medicine.

Dr. Sohn's office was clean with adequate seating. The office and restrooms are handicap accessible and he has a staff of six employees.

Staff reviewed the LACERA Disability Retirement procedures and expectations in its evaluation of County Employees applying for both service-connected and nonservice-connected disability retirements. The importance of preparing impartial and non-discriminatory reports that are clear and concise and address issues of causation and incapacity were discussed with the doctor. He understood that he would adhere strictly to the HIPAA laws that would also apply for LACERA reports. Staff reviewed with Dr. Sohn the Panel Physician Guidelines for evaluating LACERA applicants and defined the relationship between workers' compensation and disability retirement. Staff discussed the need to rely on his

own objective and subjective findings rather than the opinions of previous physician reports and/or comments.

Dr. Sohn agreed to adhere to LACERA's standard of having his evaluation reports sent to us within 30 days of examination. Staff confirmed that Dr. Sohn is agreeable with accepting payment per the Official Medical Fee Schedule (OMFS). Dr. Sohn was informed that if he is approved by the Board to be on our panel of physicians, he is required to contact the specialist assigned to the case for approval of any special tests or extraordinary charges. He was also informed that a Quality Control Questionnaire is sent to each applicant regarding their visit.

RECOMMENDATION

LACERA has a pressing need to add orthopedic physicians and Dr. Sohn expressed not only a willingness to be on our panel, but also an enthusiasm for building a relationship with LACERA.

Based on our interview and the need for his specialty, staff recommends Dr. Sohn's application be presented to the Board for approval as a LACERA Panel Physician.



300 N. Lake Ave., Pasadena, CA 91101 ■ Mail to : PO Box 7060, Pasadena, CA 91109-706 626/564-2419 • 800/786-6464

GENERAL INFORMATION		Date <u>6-1-15</u>
Group Name: <u>ROGER SOHN, M.D.</u>	Physician Name: <u>ROGER SOHN, H.D.</u>	
I. Primary Address: <u>2080 CENTURY PARK EAST #305 L.A., CA. 90067</u>		
Contact Person <u>MARILYN CATCHON</u>	Title <u>OFFICE MGR.</u>	
Telephone: <u>(310) 203-0870</u>	Fax <u>(310) 553-3204</u>	
II. Secondary Address		
Contact Person	Title	
Telephone	Fax	

PHYSICIAN BACKGROUND		
Field of Specialty <u>ORTHOPAEDIC</u>	Subspecialty	
Board Certification <input checked="" type="checkbox"/> Yes <input type="checkbox"/> No	License # <u>G38112</u>	Expiration Date

EXPERIENCE
Indicate the number of years experience that you have in each category.

Evaluation Type		
I. Workers' Compensation Evaluations		
<input type="checkbox"/> Defense How Long? _____	<input checked="" type="checkbox"/> IME How Long? <u>20</u>	
<input type="checkbox"/> Applicant How Long? _____	<input checked="" type="checkbox"/> QME How Long? <u>23</u>	
<input checked="" type="checkbox"/> AME How Long? <u>20</u>		
II. <input type="checkbox"/> Disability Evaluations How Long? <u>N/A</u>		
For What Public or Private Organizations?		

Currently Treating? <input type="checkbox"/> Yes <input checked="" type="checkbox"/> No
Time Devoted to: Treatment <u>20</u> % Evaluations <u>80</u> %


Estimated Time from Appointment to Examination <input type="checkbox"/> 2 weeks <input checked="" type="checkbox"/> 3-4 Weeks <input type="checkbox"/> Over a month	Able to Submit a Final Report in 30 days? <input checked="" type="checkbox"/> Yes <input type="checkbox"/> No
---	---


LACERA's Fee Schedule	
Examination and Initial Report by Physician	\$1,500.00 flat fee
Review of Records by Physician	\$350.00/hour
Review of Records by Registered Nurse	\$75.00/hour
Supplemental Report	\$350.00/hour

Other Fees	
Physician's testimony at Administrative Hearing (includes travel & wait time)	\$350.00/hour
Deposition Fee at Physician's office	\$350.00/hour
Preparation for Expert Testimony at administrative Hearing	\$350.00/hour
Expert Witness Fees in Superior or Appellate Court	\$3,500.00 half day \$7,000 full day
Physician agrees with LACERA's fee schedule?	Yes No
Comments	

Name of person completing this form:

MARILYN CUTCHON Title: OFFICE MGR.
(Please Print Name)

Physician Signature:  Date: 6/16/15

FOR OFFICE USE ONLY	
Physician Interview and Sight Inspection Schedule	
Interview Date: <u>7/30/15</u>	Interview Time: <u>1:00 pm</u>
Interviewer: <u></u>	

Roger S. Sohn, M.D.
Diplomate, American Board of Orthopaedic and Surgery
2080 Century Park East, Suite 305
Los Angeles, CA 90067
(310) 203 0870
Fax (310) 553-3214

LACERA
2015 JUN 18 AM 9:44
DISABILITY

CURRICULUM VITAE

PERSONAL DATA

DATE OF BIRTH: [REDACTED]

PLACE OF BIRTH: BOSTON, MASSACHUSETTS

**PROFESSIONAL
EXPERIENCE**

DATES

INSTITUTION

PRIVATE PRACTICE

9/86-PRESENT

2080 CENTURY PARK EAST
SUITE 305
LOS ANGELES, CA 90067

PRIVATE PRACTICE

7/84-9/86

NEWTON-WELLESLY HOSPITAL
NEWTON, MA

BRIGHAM & WOMEN'S
HOSPITAL
BOSTON, MA

BETH ISRAEL HOSPITAL
BOSTON, MA

**EDUCATIONAL
HISTORY**

**DATE
AWARDED**

INSTITUTION

DEGREE:

DOCTOR OF MEDICINE

JUNE, 1977

UNIVERSITY OF
SOUTHERN CALIFORNIA
LOS ANGELES, CA

BACHELOR OF ARTS

JUNE, 1973

BRANDEIS UNIVERSITY
WALTHAM, MA

SPECIAL TRAINING	DATES	INSTITUTION
SPORTS MEDICINE Fellow	1/84-7/84	HARVARD UNIVERSITY, CHILDREN'S HOSPITAL BOSTON, MA
SENIOR REGISTRAR ORTHOPAEDIC TRAUMA	7/83-1/84	CORK REGIONAL HOSPITAL CORK, IRELAND
CHIEF RESIDENT ORTHOPAEDIC SURGERY	1/83-7/83	TUFTS UNIVERSITY BOSTON, MA
RESIDENT ORTHOPAEDIC SURGERY	7/79-1/83	TUFTS UNIVERSITY BOSTON, MA
RESIDENT GENERAL SURGERY	7/78-7/79	CEDARS SINAI HOSPITAL CENTER LOS ANGELES, CA
INTERN GENERAL SURGERY	7/77-7/78	L.A. COUNTY HOSPITAL LOS ANGELES, CA

ACADEMIC APPOINTMENTS

1985-1986	INSTRUCTOR IN ORTHOPAEDIC SURGERY HARVARD UNIVERSITY SCHOOL OF MEDICINE BOSTON, MA
-----------	--

ACADEMIC AWARDS

JUNE, 1983	ORTHOPAEDIC RESEARCH RESIDENT AWARD TUFTS UNIVERSITY BOSTON, MA
------------	---

LICENSURE

JULY, 1978	STATE OF CALIFORNIA
JULY, 1979	STATE OF MASSACHUSETTS
1985	STATE OF RHODE ISLAND

CERTIFICATION

1. AMERICAN BOARD OF ORTHOPAEDIC SURGERY
2. QUALIFIED MEDICAL EXAMINER
3. AGREED MEDICAL EXAMINER

BIBLIOGRAPHY

SCIENTIFIC ARTICLES:

1. "STRESS FRACTURE OF THE SECOND METATARSAL INVOLVING LISFRANC'S JOINT IN BALLET DANCERS. A NEW OVERUSE INJURY OF THE FOOT," JBJS, VOL. 67-A, NO. 9
2. "THE EFFECT OF RUNNING ON THE PATHOGENESIS OF OSTEOARTHRITIS OF THE HIPS AND KNEE," CLINICAL ORTHOPAEDICS AND RELATED RESEARCH, NO. 198, SEPTEMBER, 1985
3. "OSTEOCHONDRITIS DISSECANS OF THE CAPITELLUM IN CHILDREN, LITTLE LEAGUE ELBOW," AMERICAN JOURNAL OF SPORTS MEDICINE, JANUARY, 1985

CHAPTERS IN BOOKS:

1. "ATHLETIC FOOTWEAR AND MODIFICATIONS," CHAPTER 20, THE LOWER EXTREMITY AND SPINE IN SPORTS MEDICINE, C.V. MOSBY AND COMPANY, ST. LOUIS, 1986
-

SCIENTIFIC EXHIBITS

1985 "THE EFFECT OF BRACING IN NEUROMUSCULAR SCOLIOSIS,"
PRESENTED AT THE NATIONAL CEREBRAL PALSY MEETING
DETROIT, MI

SCIENTIFIC ARTICLE PRESENTATION

MAY, 1984 "THE EFFECT OF RUNNING ON THE PATHOGENESIS OF
OSTEOARTHRITIS OF THE HIPS AND KNEE,"
AMERICAN COLLEGE SPORTS MEDICINE CONVENTION
SAN DIEGO, CA

ORGANIZATIONS


1. FELLOW, AMERICAN ACADEMY OF ORTHOPAEDIC SURGERY
2. CALIFORNIA ORTHOPAEDIC ASSOCIATION

Roger S. Sohn, M.D.

*Sports Medicine
Arthroscopic Surgery*

*Diplomate, American Board of Orthopaedic Surgery
2080 Century Park East, Suite 305
Los Angeles, California 90067
(310) 203-0870
Fax (310) 553-3214*

*Orthopaedic Surgery
Fractures*



RE :
EMP :
CLAIM NO. :
D/I :
ACCOUNT NO. :

AGREED MEDICAL EVALUATION

To Whom It May Concern:

This is a report of orthopedic evaluation regarding _____ is a _____ gentleman whom I was able to examine in orthopedic consultation _____ in my capacity as an Agreed Medical Examiner. _____ was used for interpretative purposes (Certification No. 500019).

I declare under penalty of perjury that this is an ML103, complex medical-legal evaluation. Face to face time with the patient has required one hour, two hours were spent in record review and one and one-half hours were spent in preparation of this report. Also addressed are the issues of apportionment and causation.

OCCUPATIONAL HISTORY:

_____ was employed as a _____ for _____. He was employed in that capacity from about _____ and worked up until _____. He is currently out of work and has been since _____.

_____ was employed in a full time capacity with provisions for overtime. In his first year of employment, he worked 9 to 10 hours a day, 6 days a week. In his second year of employment, he worked 9 to 10 hours a day, 5 to 6 days a week.

The applicant states he worked for a company that provided tree trimming services. He would transport a crew to a job site. The work crew would then proceed to cut tree branches as well as tree trunks. [redacted] was responsible for grabbing bunches of branches that were cut as well as sections of tree trunks and place them into a wood chipper machine.

At times, the applicant would have to lift and carry large sections of tree trunk which could weigh an excess of 150 pounds. The applicant states the section of tree trunk would be lifted with assistance and then be placed on the back of the worker who then had to carry it to where the wood chipper was located. At times, the applicant would assist in lifting and carrying the tree trunk section and place it onto a worker. At other times, he would be the worker carrying the tree trunk section. The applicant would have to work on rough terrain. He states most of his job assignments were in the La Canada area which was mainly hilly terrain. The applicant notes, after the tree branches or tree had been removed, he and the crew were responsible for cleaning the area and loading the truck with debris and wood. He would then have to transport the wood and debris to a dumping area. At times, if very little debris and wood were picked up, he would have to transport the debris and wood to the work base at which point it would be manually removed from the rear of the truck.

[redacted] estimates he had to lift and carry an excess of 150 pounds. The physical demands of his vocational responsibilities required but were not limited to prolonged standing, walking, bending, twisting, lifting, carrying, driving, gripping and grasping, fine manipulation and precarious positioning.

HISTORY OF PRESENT ILLNESS:

[redacted] claims continuous trauma dated [redacted]. The applicant states, after performing his usual and customary work duties for a period of about two months, he began to experience the acute onset of pain in his lower back. He attributes the onset of his lower back pain to heavy lifting. He notes, when having to remove a large tree trunk, the tree trunk would be cut into sections at which point the tree trunk would have to be lifted with the assistance of a co-worker and placed onto another co-worker's back. That co-worker would then have to carry the heavy tree section to where the truck was located at which point that worker would have to load the section of the tree trunk onto the truck. The applicant states he floated from the position of lifting and carrying the section of tree trunk to place on a worker's back to being the worker who carried the tree trunk on his back.

Apart from this arduous task, [redacted] was also responsible for repetitive heavy lifting of bundles of wood branches which he had to lift, carry and transport to a wood chipper machine. The applicant worked on rough terrain, principally, in the [redacted] area. As a consequence, most of his job assignments were on hilly terrain.

tates, when he began to experience the onset of low back pain in or about , he did inform his employer of his symptoms. The applicant was then informed that it was normal for beginning workers to experience this pain due to heavy lifting and that he would adapt to the lifting over time.

As a result, continued working. Regrettably, over time, his low back symptoms progressively worsened. Furthermore, he did develop pain in both shoulders, right side greater than left.

Despite his ongoing complaints, continued working performing his normal job duties.

then described an incident which occurred on . On that date, he was at a residential site located in states he and his work crew were providing tree trimming services for the residence. The applicant states the trees that were being trimmed were located on hilly terrain. The applicant states he was responsible for the lifting and carrying of bunches of branches which he would retrieve from the hilly terrain. He then had to carry the bundles to a wood chipper machine. The wood chipper machine was located downhill from the residential street. The applicant notes, while grabbing a bundle of branches, he proceeded down the hill but, in doing so, he tripped on a branch. He then states he flipped "twice in the air" and landed flat on his back.

Initially, was disoriented. He remained on the ground momentarily. He then experienced the acute onset of pain in his lower back. The incident was witnessed by supervisors and other co-workers. was able to rise on his own volition. He was then allowed to rest for several minutes. No treatment was offered to . He then continued to perform his normal job duties.

Unfortunately, his work efficiency was dramatically compromised because of his ongoing lower back complaints.

Despite his symptoms, he was able to complete his shift. He self-medicated with over-the-counter medication in the form of Tylenol and reported his symptoms. Unfortunately, no medical care was provided to the applicant. He then continued working performing his normal job duties. He experienced persistent pain in his lower back as well as pain in both shoulders and left wrist. He continued to self-medicate with over-the-counter medication.

continued working until the date of his termination which was . Post termination, the applicant decided to pursue legal counsel. In doing so, he came under the direction of Dr. Shah who became his designated primary treating physician. Dr. Shah evaluated and provided him with prescriptive analgesic medication.

On _____, he was referred for MRI scan of both shoulders, MRI scan of both wrists and MRI scan of the lumbar spine.

Upon review of the diagnostic reports, it was recommended the applicant be treated conservatively. He was then commenced in a course of physical therapy which he attended at a frequency of two to three times a week for a period of about four months.

After completing therapy, his therapy was transitioned to acupuncture treatments which the applicant attended at a frequency of two times a week. The applicant then had difficulty attending acupuncture as he had to move to _____. As a consequence, he decreased his acupuncture to once a week.

_____ then requested a change in primary treating physicians closer to his residence in _____.

On _____ he was referred to Dr. La, a chiropractor. Dr. La placed _____ on temporary total disability status and provided him with chiropractic manipulative treatments which _____ is attending at a frequency of once a week. He is also provided with five sessions of acupuncture directed towards his right shoulder. The applicant found the treatments exacerbated his shoulder complaints and, as a consequence, acupuncture was stopped. He was then provided acupuncture for his left wrist which he is presently attending at a frequency of once a week. He has found these acupuncture treatments efficacious.

On _____ was referred to Dr. Jain for pain management consult. Dr. Jain evaluated _____ and was of the opinion he would benefit from a lumbar epidural steroid injection. The patient, however, declined to proceed with said recommendation.

On _____ a was referred for electrodiagnostic studies. Upon review of the diagnostic report, it was recommended the applicant undergo an orthopedic surgical consultation. Unfortunately, to date, authorization for said recommendation has not been forthcoming.

Currently, _____ continues treating with Dr. La. He is attending chiropractic manipulative treatments at a frequency of once a week. He is attending acupuncture treatments at a frequency of once a week for his left wrist. He continues taking medication in the form of Ibuprofen and Naproxen. He is also taking sleep medication. He performs home exercises in the form of light walking. He is not working at this time.

With respect to the right shoulder, _____ complains of a constant, sharp, aching pain. His symptoms are moderate to severe in intensity. He is very limited with use of the right upper extremity, particularly, with movements above shoulder level.

He notes stiffness about the right shoulder. He also notes substantial weakness. He also complains of crepitus in the right shoulder. He cannot sleep on his right side. He notes radiating pain extending proximally to the right side of the cervical spine extending to the right occiput. He also notes numbness and tingling emanating from the right shoulder and extending to the right hand and wrist. He notes weakness throughout the right upper extremity. His right shoulder complaints are exacerbated by pushing, pulling, lifting and carrying activities.

With respect to the left shoulder, he is presently asymptomatic.

With respect to the left hand and wrist, overall, his left hand and wrist symptoms have greatly improved with acupuncture treatment. At present, he complains of an intermittent, moderate to severe pain which is predicated on activity. He presents to this consultation wearing a wrist brace. He denies any weakness with gripping and grasping activities. He notes numbness and tingling affecting all digits of his left hand. He also drops objects uncontrollably with use of his left hand. His left hand and wrist symptoms are exacerbated by repetitive pushing, pulling, lifting and carrying activities.

With respect to the right hand and wrist, he is presently asymptomatic.

With respect to the lumbar spine, he complains of a constant, pulsating sensation. Symptoms are moderate to severe in intensity depending upon activity. Low back symptoms are exacerbated by prolonged sitting, standing, bending, twisting, lifting, carrying, pushing and pulling. He also notes increased pain with sit-to-stand transitions. He notes substantial weakness with pushing, pulling, lifting and carrying activities. He also notes limited mobility secondary to pain with flexion, extension, lateral flexion and rotational motions of the lumbar spine. He also experiences paralumbar muscular spasms. He notes radiating pain extending to the posterior aspect of both lower extremities terminating at both knees. He notes weakness in both legs.

ACTIVITIES OF DAILY LIVING:

With respect to personal hygiene, notes moderate to severe impairment. With respect to methods of communication, he notes mild impairment. With respect to physical activities, he notes severe impairment. With respect to sensory function, he states not applicable. With respect to manual activities, travel, sexual activity and sleep, he notes severe impairment.

PAST MEDICAL HISTORY:

has been informed that he is pre-diabetic.

Previous Injuries:

denies any previous injuries.

Medications:

is presently taking medication in the form of Glucophage, Ibuprofen and Naproxen. He is also taking sleep medication.

Surgeries:

has undergone appendectomy.

SOCIAL HISTORY:

is divorced and has six children. He was born in and currently resides in

PHYSICAL EXAMINATION:

CERVICAL SPINE EXAMINATION:

Palpation:

There was no tenderness to palpation. There was no muscle spasm present.

Range of Motion - Cervical Spine:

	<u>Right</u>	<u>Left</u>
Flexion		100%
Extension		100%
Lateral Rotation	100%	100%
Lateral Bending	100%	100%

Deep Tendon Reflexes:

	<u>Right</u>	<u>Left</u>
Biceps	2+	2+
Triceps	2+	2+
Brachioradialis	2+	2+

Motor Examination:

Right

Left

Muscle group tested:

Deltoid	4/5	5/5
Biceps	5/5	5/5
Triceps	5/5	5/5
Wrist flexors	5/5	5/5
Wrist extensors	5/5	5/5
Extrinsics	5/5	5/5
Intrinsics	5/5	5/5

Sensory Examination:

Sensory examination was normal in all the dermatomes of the upper extremities bilaterally.

Measurements:

Measurements were taken of the upper extremities bilaterally. The arms measured 32 cm. The forearms measured 25 cm. There was no atrophy or edema noted.

SHOULDER EXAMINATION:

Inspection:

The shoulders were normal to inspection. The AC joints were well located. No obvious deformities were noted.

Palpation:

The shoulders were normal to palpation. There was no tenderness. There was no erythema noted.

Range of Motion - Shoulders:

Right

Left

Abduction	90	170
Forward Flexion	90	170
Internal Rotation	80	80
External Rotation	60	60
Extension	30	30

Impingement Sign:

Impingement sign was negative.

Apprehension Sign:

Apprehension sign was negative.

ELBOW EXAMINATION:

<u>Range of Motion - Elbows:</u>	<u>Right</u>	<u>Left</u>
Flexion	135	135
Extension	0	0
Supination	85	85
Pronation	85	85

WRIST AND HAND EXAMINATION:

Inspection:

There were no abnormalities noted to inspection. There was no swelling.

Palpation:

The wrists were nontender to palpation.

<u>Range of Motion - Wrists:</u>	<u>Right</u>	<u>Left</u>
Dorsiflexion	75	75
Palmar Flexion	75	75
Supination	85	85
Pronation	85	85
Radial Deviation	20	20
Ulnar Deviation	40	40

Range of Motion - Hands:

Range of motion of the hands was normal. The patient was able to bring the fingertips to the distal palmar crease.

Tinel's Sign:

Tinel's sign was negative bilaterally.

Phalen's Test:

Phalen's test was negative bilaterally.

Motor Examination:

	<u>Right</u>	<u>Left</u>
EDC	5/5	5/5
FDS	5/5	5/5
FDP	5/5	5/5
FPL	5/5	5/5
FPB	5/5	5/5
EPL	5/5	5/5
EPB	5/5	5/5
APL	5/5	5/5
APB	5/5	5/5
Opponens	5/5	5/5
Intrinsics	5/5	5/5

Sensory Examination:

Sensory examination was normal in the hands.

Grip Strength:

Grip strength was measured with the Jamar Dynamometer. The measurements were:

Right : 10/12/12
Left : 13/13/14

THORACOLUMBAR SPINE EXAMINATION:

Palpation:

The thoracolumbar spine was nontender to palpation. There was no muscle spasm present.

Range of Motion - Thoracolumbar Spine:

	<u>Right</u>	<u>Left</u>
Flexion		90%
Extension		85%
Lateral Bending	95%	100%

Straight Leg Raising:

Straight leg raising was negative bilaterally.

Deep Tendon Reflexes:

	<u>Right</u>	<u>Left</u>
Knees	2+	2+
Ankles	2+	2+

Motor Examination:

	<u>Right</u>	<u>Left</u>
Muscle groups tested:		
Quadriceps	5/5	5/5
Hamstrings	5/5	5/5
Posterior tibialis	5/5	5/5
Anterior tibialis	5/5	5/5
Extensor hallucis longus	5/5	5/5
Gastrocnemius	5/5	5/5

Sensory Examination:

Sensory examination was normal in all the dermatomes of the lower extremities bilaterally.

Measurements:

Measurements were taken of the thighs and calves bilaterally. The thighs measured 45 cm. The calves measured 35 cm. There was no atrophy or edema noted.

KNEE EXAMINATION:

Inspection:

The knees were normal to inspection. There was no effusion. There was no erythema or edema.

Palpation:

The knees were nontender to palpation.

Range of Motion - Knees:

	<u>Right</u>	<u>Left</u>
Flexion	135	135
Extension	0	0

Stability:

The knees were stable to valgus and varus stress.

Anterior Cruciate Ligament:

Lachman's sign was negative. The anterior drawer sign was negative.

Meniscus:

McMurray's test was negative.

Patellofemoral Joint:

The patellofemoral joint was nontender.

MEDICAL RECORD REVIEW:

A report is reviewed from Physician Assistant Natalie Hammond in conjunction with Dr. Hitendra Shah of First Choice Healthcare Medical Group dated This is a handwritten status report. Treatment plan: 1) Medications. 2) Physical therapy two times per week for four weeks. 3) Psychiatric consultation. 4) Follow-up in four weeks. The patient is to return to modified duties with restrictions of no prolonged standing or walking; no climbing, bending or stooping; no overhead work with the right or left hands; a weight lifting restriction of 15 pounds or less; five minute ergonomic stretch breaks; no sports or P.E.; he must wear his braces at work; restrictions also apply at home/off hours; and no forceful use of the right or left hands.

A report is reviewed from Dr. Stanton Kremsky of Vital Imaging Medical Group dated This is an x-ray of the right wrist. Impression: Positive ulnar variance. This is a normal variant.

A report is reviewed from Dr. Kremsky dated This is an x-ray of the left wrist. Impression: Positive ulnar variance. This is a normal variant.

A report is reviewed from Dr. Kremsky dated This is an x-ray of the left hand. Impression: Positive ulnar variance. This is a normal variant.

A report is reviewed from Dr. Kremsky dated This is an x-ray of the left shoulder. Impression: Negative radiographic examination of the left shoulder.

A report is reviewed from Dr. Kremsky dated This is an x-ray of the right shoulder. Impression: Negative radiographic examination of the right shoulder.

A report is reviewed from Dr. Kremsky dated This is an x-ray of the lumbar spine with flexion and extension views. Impression: Negative radiographic examination of the lumbar spine.

A report is reviewed from Dr. Anthony Francisco of Eagle Diagnostic Group dated This is a pain management psychological AOE/COE evaluation and is 24 pages in length. Diagnostic impression: Axis I: Adjustment disorder with anxiety and depressed mood due to chronic pain secondary to industrially related traumatic injuries. Axis II: No diagnosis. Axis III: Physical disorders and conditions as diagnosed by the appropriate examining specialist. Axis IV: Severity of psychosocial stressors-injury caused difficulties. Axis V: GAF 62 current, prior year unknown.

Treatment plan: He may benefit from psychotherapeutic treatment on a monthly basis which may include a variety of modalities including, but not limited to behavioral supportive and/or biofeedback therapy for a period of between two to three months. More than 51% of his psychiatric injury resulted from real and/or actual events of his employment.

A report is reviewed from Physician Assistant Nora Davidian in conjunction with Dr. Shah dated . This is a handwritten primary treating physician's progress report. The patient complains of intermittent mild: 1) Lumbar spine pain. 2) Bilateral shoulder pain. 3) Bilateral wrist and hand pain. 4) Numbness and tingling of his bilateral upper extremities and bilateral lower extremities. Diagnoses: 1) Lumbar spine sprain/strain, rule out radiculopathy. 2) Bilateral shoulder pain, rule out internal derangement. 3) Bilateral wrist and hand pain, rule out internal derangement, rule out carpal tunnel syndrome. Treatment plan: 1) EMG and NCVS of the bilateral upper extremities and bilateral lower extremities. 2) Prescribe creams. 3) Physical therapy two times per week for four weeks. 4) Niosh testing. 5) Follow-up in four weeks. He is to continue modified duties with restrictions of no prolonged standing or walking; no climbing, bending or stooping; no overhead work with the right or left hands; no sports or P.E.; he must wear his braces at work; restrictions apply at home/off hours; a weight lifting restriction of 15 pounds or less; and five minute ergonomic stretch breaks.

A report is reviewed from Chiropractor Michael Assouri dated . This is a procedure report. Diagnosis: Lumbar spine myofascial pain syndrome. Procedure performed: Second extracorporeal shockwave therapy procedure.

A report is reviewed from Dr. Kremsky dated . This is an MRI of the right wrist with flexion and extension views. Impression: Unremarkable MRI of the wrist including evaluation in flexion and extension.

A report is reviewed from Dr. Kremsky dated . This is an MRI of the left wrist with flexion and extension views. Impression: 1) Tear at the radial attachment of the triangular fibrocartilage. Associated distal radioulnar joint effusion. 2) No other significant findings are noted.

A report is reviewed from Dr. Kremsky dated . This is an MRI of the lumbar spine with flexion and extension views. Impression: 1) L5-S1 left paracentral focal disc protrusion that abuts the thecal sac. The neuroforamina are patent. Posterior annular tear/fissure. Disc measurements: Neutral 2.2 mm, flexion 3.1 mm, extension 2.2 mm. 2) Straightening of the lumbar lordosis which may be due to myospasm. Limited range of motion in flexion and extension. 3) No other significant findings are noted.

A report is reviewed from Dr. Kremsky dated . This is a multiposition MRI of the right shoulder. Impression: 1) Full thickness tear of the supraspinatus tendon with 8 mm of medial retraction. Glenohumeral joint effusion and fluid within the subacromial/subdeltoid space. 2) Partial thickness tear of the infraspinatus tendon. 3) No other significant findings are noted.

A report is reviewed from Dr. Amjad Safvi of Vital Imaging Medical Group dated . This is a multiposition MRI of the left shoulder. Impression: 1) Supraspinatus tendinosis. 2) Minimal subacromial and subscapularis bursitis. 3) Minimal glenohumeral joint effusion. 4) Osteoarthropathy of acromioclavicular joint. 5) Subchondral cyst/erosion at lateral aspect of humeral head.

A report is reviewed from Physician Assistant Nelson Fuentesbella in conjunction with Dr. Shah dated . This is a handwritten primary treating physician's progress report. The patient complains of: 1) Lumbar spine pain with numbness and tingling to his lower extremity. 2) Bilateral shoulder pain. 3) Bilateral wrist and hand pain with numbness and tingling. Diagnoses: 1) Lumbar spine rule out herniated nucleus pulposus. 2) Bilateral shoulders rule out internal derangement. 3) Bilateral wrists and hands rule out internal derangement. Treatment plan: 1) Acupuncture two times per week for four weeks. 2) Psychiatric consultation. 3) Shockwave therapy. 4) Follow-up in four weeks. He is to continue modified duties with the previously outlined restrictions.

A report is reviewed from Chiropractor Assouri dated . This is a procedure report. Diagnosis: Right shoulder disorder of bursa/tendon. Procedure performed: Third extracorporeal shockwave therapy procedure.

A deposition transcript of Jose De Santiago Acosta Bonilla dated . is reviewed which is 72 pages in length.

A report is reviewed from Chiropractor Assouri dated . This is a procedure report. Diagnosis: Lumbar myofascial pain syndrome. Procedure performed: Sixth extracorporeal shockwave therapy procedure.

A report is reviewed from Chiropractor Assouri dated . This is a procedure report. Diagnosis: Left shoulder disorder of bursa/tendon. Procedure performed: First extracorporeal shockwave therapy procedure.

A report is reviewed from Dr. Shah dated . This is a handwritten primary treating physician's progress report. The patient complains of: 1) Lumbar spine pain with numbness and tingling to his bilateral feet. 2) Bilateral shoulder pain. 3) Bilateral wrist and hand pain with numbness and tingling.

Treatment plan: 1) Pain management consultation. 2) Prescribe pills and creams. 3) Acupuncture two times per week for four weeks. 4) General orthopaedic consultation within the MPN. 5) Hand specialist consultation. 6) Shockwave therapy. 7) Follow-up in four weeks. He is to continue modified duties with the previously outlined restrictions.

A report is reviewed from First Choice Healthcare Medical Group dated _____ This is a functional capacity evaluation and is six pages in length.

A report is reviewed from Chiropractor Assouri dated _____ This is a procedure report. Diagnosis: Left wrist/hand tenosynovitis. Procedure performed: Third extracorporeal shockwave therapy procedure.

A report is reviewed from Dr. Shah dated _____ This is a handwritten primary treating physician's progress report. The patient complains of: 1) Lumbar spine pain. 2) Bilateral shoulder pain. 3) Bilateral wrist and hand pain. Treatment plan: 1) MPN pain management consultation. 2) Continue medications. 3) Acupuncture two times per week for four weeks. 4) MPN general orthopaedic consultation. 5) Hand specialist consultation. 6) Shockwave therapy. 7) Follow-up in four weeks. He is to continue modified duties. No restrictions are outlined.

A report is reviewed from Physician Assistant Alex Grigorian in conjunction with Dr. Shah dated _____. This is a handwritten primary treating physician's progress report. The patient complains of: 1) Lumbar spine pain with pain, numbness and tingling in his bilateral lower extremities which is intermittent. 2) Bilateral shoulder pain. 3) Bilateral wrist and hand pain. Treatment plan: 1) Pain management consultation. 2) Prescribe pills and creams. 3) Acupuncture two times per week for four weeks. 4) MPN general orthopaedic consultation. 5) Shockwave therapy. 6) Follow-up in four weeks. He is to continue modified duties. No restrictions are outlined.

A report is reviewed from Chiropractor Phu W. La dated _____ This is a handwritten doctor's first report of occupational injury or illness. The patient is seen for injuries he sustained on a continuous trauma basis from _____ to _____. He was injured due to repetitive movement. The patient complains of: 1) Bilateral shoulder pain and stiffness. 2) Bilateral arm numbness and tingling. 3) Back pain radiating to his bilateral legs. 4) Left wrist and arm pain. 5) Headaches. Treatment plan: 1) Chiropractic manipulative therapy, work conditioning, physical therapy and acupuncture three times per week for eight weeks. 2) Pain management, internal medicine and psychiatric consultations. 3) Functional capacity evaluation. 4) EMG and NCVS. 5) MRI. He is temporarily totally disabled.

A report is reviewed from Chiropractor La dated _____ This is a primary treating physician's supplemental report regarding MPN treatment aid is three pages in length.

A report is reviewed from Dr. Kremsky dated _____ his is an x-ray of the thoracic spine. Impression: 1) Straightening of the normal thoracic kyphosis with restricted range of motion on extension view which may reflect an element of myospasm. 2) Degenerative right lateral and left lateral endplate osteophytes off of a few lower thoracic vertebrae and anterior superior and anterior inferior endplate osteophytes off of a few mid thoracic vertebrae and lower thoracic vertebrae.

A report is reviewed from Dr. Kremsky dated _____ This is an x-ray of the left wrist. Impression: Unremarkable wrist study.

A report is reviewed from Dr. Kremsky dated _____ This is an x-ray of the lumbar spine with flexion and extension views. Impression: Degenerative anterior superior endplate osteophyte at L4.

A report is reviewed from Dr. Kremsky dated _____ This is an x-ray of the left shoulder. Impression: Unremarkable shoulder study.

A report is reviewed from Dr. Kremsky dated _____ This is an x-ray of the right shoulder. Impression: Unremarkable shoulder study.

A report is reviewed dated _____ This is a handwritten primary treating physician's progress report. (Physician signature is illegible). The patient complains of: 1) Lumbar spine pain, loss of range of motion, myospasm, numbness and weakness. 2) Migraine headaches. 3) Bilateral shoulder pain, loss of range of motion, myospasm and weakness, right worse. 4) Left wrist pain, loss of range of motion, spasm, numbness and weakness. Treatment plan: 1) Continue treatment including work conditioning and functional restoration. 2) MRI/CT. 3) EMG and NCVS. 4) Pain management consultation. 5) General surgery consultation. 6) Follow-up on _____. He remains temporarily totally disabled.

A report is reviewed from Dr. Adil Mazhar of Vital Imaging Medical Group dated _____ This is a multiposition MRI of the right shoulder. Impression: 1) Acromion flat, laterally downsloping. 2) Acromioclavicular joint osteoarthritis. 3) Supraspinatus tear, partial, articular. 4) Infraspinatus tendinosis. 5) Synovium effusion. 6) Subacromial/subdeltoid bursitis. 7) Subcortical cysts in the humeral head. 8) Horizontal biceps tendon tendinosis.

A report is reviewed from Dr. Mazhar dated [redacted] This is an MRI of the lumbar spine with flexion and extension views. Impression: 1) Straightening of the lumbar lordotic curvature which may reflect an element of myospasm. 2) Disc desiccation at L5-S1. 3) L5-S1 focal central disc herniation which causes stenosis of the spinal canal. Disc measurements: Neutral 2.9 mm, flexion 2.9 mm, extension 2.9 mm. Previous disc measurements: Neutral 2.2 mm, flexion 3.1 mm, extension 2.2 mm.

A report is reviewed from Dr. Mazhar dated [redacted] This is an MRI of the left wrist with flexion and extension views. Impression: Tear at the radial attachment of the triangular fibrocartilage is again appreciated when compared to the study done [redacted]

A report is reviewed from Dr. Norman Reichwald in conjunction with Dr. Francisco dated [redacted] This is a comprehensive pain management medical-legal psychological evaluation and is 26 pages in length. Diagnostic impression: Axis I: Adjustment disorder with anxiety and depressed mood due to chronic pain secondary to industrially elated traumatic injuries. Axis II: No diagnosis. Axis III: Physical disorders and conditions as diagnosed by the appropriate examining specialist. Axis IV: severity of psychosocial stressors-injury caused difficulties. Axis V: GAF 66 current, prior year unknown. Treatment plan: He may benefit from psychotherapeutic treatment on a monthly basis which may include a variety of modalities including, but not limited to behavioral, supportive and/or biofeedback therapy for a period of between two to three months. More than 51% of his psychiatric injury resulted from real and/or actual events of his employment.

A report is reviewed dated [redacted] This is a functional capacity evaluation and is 19 pages in length.

A report is reviewed dated [redacted] This is a handwritten primary treating physician's progress report. (Physician signature is illegible). The patient complains of: 1) Lumbar spine pain, numbness and weakness. 2) Bilateral shoulder pain, loss of range of motion, numbness and weakness. 3) Left wrist pain, loss of range of motion, numbness and weakness. Treatment plan: 1) Continue treatment including work conditioning and functional restoration. 2) MRI/CT. 3) EMG and NCVS. 4) Pain management consultation. 5) Shockwave therapy. 6) Orthopaedic surgery consultation. 7) Follow-up on [redacted] He remains temporarily totally disabled.

A report is reviewed from Dr. Justin Fu dated [redacted] This is a sleep medicine report and is 12 pages in length.

A report is reviewed from Dr. Michael Rudolph dated [redacted] This is a medical consultative report/internal medicine initial consultation and is four pages in length.

Impression: 1) Insomnia. This is most likely due to the patient's pain brought on by his injuries. 2) Gastritis. This is most likely due to the patient's use of pain medications for his injuries. 3) Headache. This is most likely due to the patient's original injuries, as well as the added pain brought on by his injuries. Treatment plan: 1) Prescribe Ambien 10 mg, Prilosec 20 mg and Fioricet. 2) Follow-up in three months.

A report is reviewed from Dr. Fu dated This is a polysomnogram and sleep staging study report and is five pages in length.

A report is reviewed dated This is a handwritten primary treating physician's progress report. (Physician signature is illegible). The patient complains of: 1) Lumbar spine pain, loss of range of motion, myospasm and weakness. 2) Migraine headaches. 3) Bilateral shoulder pain, loss of range of motion, myospasm and weakness. 4) Left wrist pain, spasm, numbness and weakness. Treatment plan: 1) Continue treatment including work conditioning and functional restoration. 2) EMG and NCVS. 3) Shockwave therapy. 4) Follow-up on January 15, 2015. He remains temporarily totally disabled.

A report is reviewed from Dr. Kevin Do dated This is an EMG and NCVS of the bilateral upper extremities. Conclusion: 1) Normal NCVS. 2) Normal EMG.

A report is reviewed from Dr. Sanjiv Kumar Jain dated This is an initial pain management consultation with request for authorization. The patient is seen for injuries he sustained on a continuous trauma basis from to He attributes his injuries to his work related activities and as a result he now complains of low back and bilateral shoulder pain. The patient complains of: 1) Low back pain which is 6-7/10. The pain radiates along his lower extremities. The pain has gradually progressed. His pain is worsened by prolonged standing, lifting, bending or unusual activity. 2) Bilateral shoulder pain which is 6-7/10. The pain radiates along his bilateral upper extremities. The pain progresses with the passage of the day. Diagnostic impression: 1) Lumbar radiculopathy. 2) Bilateral shoulder arthropathy. Treatment plan: 1) Caudal epidural steroid injection at L5-S1. 2) Bilateral suprascapular nerve blocks under fluoroscopic guidance. 3) Myoneural injections. 4) Prescribe Gabapentin/Amitriptyline/Dextromethorphan cream, Cyclobenzaprine/Flurbiprofen cream, Tramadol/Acetaminophen 37.5/325 mg and Omeprazole 20 mg. 5) Treatment should be offered by an acupuncturist, chiropractor and physical therapist with chiropractic modalities. 6) Cold unit should be employed after epidural injections. 7) Interferential unit should be used. 8) Consultation for evaluation and treatment with an orthopaedic surgeon. 9) Follow-up in four weeks.

A report is reviewed from Dr. Do dated This is an EMG and NCVS of the bilateral lower extremities. Conclusion: 1) Normal NCVS. 2) Abnormal EMG. The findings are suggestive of a bilateral chronic active L5-S1 radiculopathy.

A report is reviewed dated This is a handwritten primary treating physician's progress report. (Physician signature is illegible). (Only page two of this report is submitted for review). Treatment plan: 1) Shockwave therapy. 2) Orthopaedic surgery consultation. 3) Follow-up on February 26, 2015. He remains temporarily totally disabled.

A report is reviewed dated This is a handwritten primary treating physician's progress report. (Physician signature is illegible). The patient complains of: 1) Lumbar spine pain, loss of range of motion and weakness. 2) Migraine headaches. 3) Bilateral shoulder pain, loss of range of motion, myospasm and weakness. 4) Left wrist pain, loss of range of motion, numbness and weakness. Treatment plan: 1) Acupuncture two times per week for six weeks. 2) Physical therapy two times per week for six weeks. 3) Shockwave therapy. 4) Orthopaedic surgery consultation. 5) Follow-up on April 16, 2014. He remains temporarily totally disabled.

A report is reviewed which is undated. This is a handwritten primary treating physician's progress report. (Physician signature is illegible). (Only page one of this report is submitted for review). The patient complains of: 1) Lumbar spine pain, loss of range of motion, myospasm and weakness. 2) Migraine headaches. 3) Bilateral shoulder pain, loss of range of motion, myospasm and weakness. 4) Left wrist pain, myospasm, numbness and weakness.

A report is reviewed from Physician Assistant Grigorian in conjunction with Dr. Shah which is undated. This is a handwritten primary treating physician's progress report. The patient complains of: 1) Lumbar spine pain. 2) Bilateral shoulder pain. 3) Bilateral wrist and hand pain. 4) Anxiety and depression. 5) Problems sleeping. Treatment plan: 1) Prescribe pills and creams. 2) Pain management for the lumbar spine. 3) Acupuncture two times per week for four weeks. 4) General orthopaedic consultation. 5) Shockwave therapy. 6) Follow-up in four weeks. He is to continue modified duties with restrictions of no prolonged standing or walking; no climbing, bending or stooping; no overhead work with the right or left extremity; no lifting more than 15 pounds; five minute ergonomic stretch breaks; no sports or P.E.; he must wear his braces at work; and restrictions apply at home/off hours.

A group of handwritten chiropractic therapy notes are reviewed. (The name of the facility is not noted and the chiropractor's signature is illegible).

A group of handwritten physical therapy notes are reviewed. (The name of the facility is not noted and the physical therapists signature is illegible).

A group of handwritten acupuncture secondary treating physician's progress reports and notes from Acupuncturist Grace Lim are reviewed.

A group of urine drug testing reports from Medi-Lab Corporation are reviewed.

A group of discovery reports (clinical and surgical imaging metrics radiological consultation reports) are reviewed.

A group of anatomical impairment measurements reports are reviewed.

ASSESSMENT:

This is a gentleman who works as a _____ for _____ & _____. He states he's had continuous trauma in this regard. He's worked there for about 1 ½ years.

He also notes, however, a specific injury of _____. He was a residential site in _____. He and his work crew were providing tree trimming service for a residence. The applicant states the trees were being trimmed working over a very hilly terrain. He apparently slipped and fell. He tripped on a branch and flipped twice in the air landing on his back. He had immediate back pain. He completed his shift but had back pain as well as shoulder pain. He had been seen by a chiropractor, Dr. La. He's continued to have pain about the right shoulder. The left shoulder is doing well. There really no problem with the left shoulder. However, there appears to be arthrofibrosis as well as right shoulder weakness. He also has back pain with limitation of motion.

MRI scan showed L5-S1 2 to 3 mm. protrusion. Right shoulder MRI was consistent with rotator cuff tear. This is relative to the MRI of the _____ which showed 8 mm. of medial retraction.

Absent surgery, it is unlikely, in my opinion, applicant's condition is going to change in the foreseeable future. He is, therefore, to be considered permanent and stationary for rating purposes having reached maximum medical improvement.

DIAGNOSIS:

1. Rotator cuff tear, right shoulder.
2. Disc injury, lumbar spine.

SUBJECTIVE FACTORS OF DISABILITY:

With respect to the shoulder, applicant has complaints of pain rated as intermittent and slight becoming occasionally slight to moderate.

With respect to the low back, applicant has complaints of pain rated as intermittent and slight becoming occasionally slight to moderate.

OBJECTIVE FACTORS OF DISABILITY:

The patient has positive findings on MRI of the shoulder as well as the back. He has limitation of motion with weakness.

WORK RESTRICTIONS:

Applicant is limited to light work only.

IMPAIRMENT RATING:

With respect to the right shoulder, applicant is best rated per Table 16-35. He has a 6% upper extremity impairment due to weakness in flexion, 3% impairment due to weakness in abduction, 2% impairment due to weakness in extension, 2% impairment due to weakness in internal rotation, 2% impairment due to weakness in external rotation. This is a 15% upper extremity impairment which converts to a 9% impairment whole person. He also has loss of motion. As per Figure 16-40 and Figure 16-43, he has 6% impairment whole person. Combining impairments, right shoulder is rated 15% via AMA Guidelines.

With respect to the lumbar spine, he is DRE Category II with 7% impairment whole person.

Combining all impairments, applicant has 21% impairment whole person.

FUTURE MEDICAL CARE:

The applicant should have access to orthopedic evaluation on an as needed basis. He should have access to analgesics as well as anti-inflammatory medications. He may need surgery for that right shoulder and surgery should be provided on an industrial basis.

VOCATIONAL REHABILITATION:

Vocational rehabilitation is indicated.

APPORTIONMENT:

There is no legal basis for apportionment. Applicant's injury appears to be related strictly to the specific of .

CAUSATION:

Applicant's injury is industrial in causation.

DISCLOSURE:

During this evaluation, the patient was interviewed by a historian, , for an initial history. The entire medical history was reviewed in detail by myself with the patient. The medical records were reviewed and summarized by . and were subsequently reviewed in their entirety by the undersigned. was used for interpretative purposes (Certification No. 500019). The physical examination and dictation of this report with all opinions rendered herein are strictly by the undersigned physician. X-rays, if any, were obtained by Margo Miller, CRT, ARRT. The above evaluation was carried out at 2080 Century Park East, Suite 305, Los Angeles, California. Transcription was provided by .


I declare under penalty of perjury that the information contained in this report and its attachments, if any, is true and correct to the best of my knowledge and belief, except as to information I have indicated I have received from others. As to that information, I declare under penalty of perjury that the information accurately describes the information provided to me and, except as noted herein, that I believe it to be true. I have not violated Labor Code Section 139.3 and the contents of the report and bill are true and correct to the best of my knowledge. This statement is made under penalty of perjury.

Thank you very much for your attention to this matter. If there are any questions not answered in this report, I am available for cross-examination via deposition at the mutual convenience of all parties.

page 23

This report and declaration were signed in the County of Los Angeles on June 6, 2015.

Sincerely yours,

A handwritten signature in black ink, appearing to read 'R. Sohn', written over the 'Sincerely yours,' text.

ROGER SOHN, M.D.
Diplomate, American Board
of Orthopaedic Surgery

RS:sm

Copy to:

Roger S. Sohn, M.D.

*Sports Medicine
Arthroscopic Surgery*

*Diplomate, American Board of Orthopaedic Surgery
2080 Century Park East, Suite 305
Los Angeles, California 90067
(310) 203-0870
Fax (310) 553-3214*

*Orthopaedic Surgery
Fractures*

Sample 2

RE :
EMP :
CLAIM NO. :
EAMS/WCAB NO. :
D/I :
ACCOUNT NO. :

AGREED MEDICAL EVALUATION

To Whom It May Concern:

This is a report of orthopedic evaluation regarding _____, a gentleman whom I was able to examine in orthopedic consultation on _____, in my capacity as an Agreed Medical Examiner. _____ was used for interpretive services (Certification No. 500228).

I declare under penalty of perjury that this is an ML104 medical-legal evaluation involving extraordinary circumstances, as documented by four of the complexity factors listed under ML103. Those factors included four or more hours of face-to-face time with the applicant obtaining the history and performing the physical examination, as well as reviewing the medical records (two factors), and addressing the complex medical-legal issues of causation and apportionment.

Face-to-face time with the patient has required one hour, review of voluminous records, preparation and dictation of this report has required six hours. Total time spent on this evaluation was seven hours.

OCCUPATIONAL HISTORY:

_____ as employed as a _____ for _____ He was employed in that capacity from about _____ and worked up until _____.

He is currently out of work and has been since about . was employed in a full time capacity. He states he was responsible for moving : to his worktable. The applicant worked with various size _ usually weighing roughly 50 pounds depending on the order. The applicant would then, after placing the _ on his table, extend the _ to the order designated length at which point he would operate a specialized cutting machine which would then cut the roll.

The applicant also had to lift and carry a roll of heavy paper which weighed roughly 150 pounds which he had to lift and place on the table. This had to be performed two to three times daily.

The physical demands of the applicant's vocational responsibilities required but were not limited to prolonged standing and walking, repetitive bending, twisting, lifting, carrying, gripping and grasping and fine manipulation. His duties also required stooping, squatting, reaching and precarious positioning.

HISTORY OF PRESENT ILLNESS:

_ date of injury of . On that date, he was performing his usual and customary work duties as a _ for . The applicant states he and two other co-workers needed to pull a large _ which roughly weighed 50 pounds which was positioned under several other rolls which made it difficult to pull free. The applicant states he was positioned at the end of the roll while the other two workers were positioned closer to the base of the roll. As all three men pulled forcefully, the roll came free and, with the pulling force applied to the roll, the roll was pulled towards ! _ with tremendous force. This threw the applicant backwards and he fell into other rolls located behind him after which he fell into split position. He immediately experienced the acute onset of pain in the right inguinal area. Despite his symptoms, he continued working and completed his workday.

The following day, he continued to experience pain prompting _ to communicate his symptoms to his employer. In doing so, no medical treatment was provided to l _ and he continued working performing his normal job duties.

then self-medicated with over-the-counter medication in the form of Ibuprofen. As he continued to perform his normal job duties, he then developed pain in the right shoulder and lower back.

On multiple occasions, he notified his employer of his right inguinal and orthopedic symptoms. Unfortunately, no treatment was ever offered to

On a private basis, on three separate occasions, he sought treatment at California Hospital. There, an examination was performed and he underwent an ultrasound evaluation of the right inguinal area. He was diagnosed with a right inguinal hernia and recommended treatment. The applicant then communicated the diagnosis given to him from the physicians at California Hospital but, to no avail, treatment was never offered.

Eventually, as the applicant continued to complain of his orthopedic and right inguinal symptoms, he was referred for medical care per his employer.

_____ was initially treated at U. S. Health Works Medical Group on _____ where he underwent a consultation by Dr. Abdo, the industrial physician. Dr. Abdo evaluated the applicant's right shoulder symptoms. He provided him with medication in the form of Nabumetone 750 mg., Tylenol 500 mg., Polar Frost Gel 150 mg. and Omeprazole 20 mg. He then released the applicant to return to work with restrictions. Unfortunately, the applicant's work restrictions were not respected and he continued to perform his normal job duties.

_____ so reported, to the physician at U. S. Health Works Medical Group, his right inguinal pain for which he was recommended to undergo a general surgical consultation. Ultimately, the applicant was referred to Dr. Sim, a general surgeon. Dr. Sim evaluated _____ and informed him that he was a candidate to proceed with a right inguinal hernia report.

At this juncture, _____ decided to pursue legal counsel. In doing so, his medical care was then transferred to Dr. Rubanenko, an orthopedic surgeon, on _____. Dr. Rubanenko evaluated _____ and provided him with a prescription for Motrin 600 mg., Flexeril 7.5 mg. He also dispensed, to _____, a TENS unit and referred him for an MRI scan of the lumbar spine as well as electrodiagnostic studies. Unfortunately, authorization for electrodiagnostic studies was not provided.

_____ then received authorization to proceed with the previously recommended surgery by Dr. Sim. On _____, under the auspices of Dr. Sim, _____ underwent right inguinal hernia repair. The applicant found the procedure efficacious. Postoperatively, he experienced mild residual pain.

He then followed up with Dr. Rubanenko who commenced him in a course of physical therapy directed towards the thoracic and lumbar spine. The applicant is presently attending therapy at a frequency of two times a week.

Currently, [redacted] continues treating with Dr. Rubanenko. He continues medication in the form of Tramadol 50 mg., Amitriptyline 10 mg. and Ibuprofen 600 mg. At present, he performs home exercises in the form of walking. He is not working at this time.

With respect to the thoracolumbar spine, [redacted] complains of a constant pain. Symptoms are moderate to severe in intensity. He notes substantial weakness with pushing, pulling, lifting and carrying activities. He also notes limited mobility secondary to pain with flexion, extension, lateral flexion and rotational motions of the thoracolumbar spine. He experiences parathoracic muscular spasms. In his lower back, he notes radicular pain extending distally to the right lower extremity extending to the foot. He notes substantial weakness of the right leg with numbness and tingling in the right foot. He also complains of numbness and tingling affecting the entirety of both lower extremities. He notes stiffness of the thoracolumbar spine. He also notes increased pain with prolonged sitting, standing and driving. He has difficulty sleeping as a consequence of his thoracolumbar complaints.

With respect to the right shoulder, he complains of a constant pain. His symptoms are moderate to severe in intensity. He notes substantial weakness with pushing, pulling, lifting and carrying activities. He has difficulty with movements of the right upper extremity at or above shoulder level. He notes crepitus in the right shoulder. He also notes stiffness. His right shoulder complaints are exacerbated by pushing, pulling, lifting and carrying. He cannot sleep on his right side.

ACTIVITIES OF DAILY LIVING:

With respect to personal hygiene, [redacted] notes moderate to severe impairment. With respect to methods of communication, he notes mild impairment. With respect to physical activity, he notes moderate to severe impairment. With respect to sensory function, he states not applicable. With respect to manual activities and travel, he notes moderate to severe impairment. With respect to sexual activity, he notes severe impairment. With respect to sleep, he notes moderate to severe impairment.

PAST MEDICAL HISTORY:

[redacted] denies any previous medical problems.

Previous Injuries:

On [redacted] while employed as a [redacted], Inc., sustained injury. While performing his normal job duties, he was spreading fabric on a table.

In doing so, a co-worker, operating a forklift, struck him from behind crushing the applicant and pinning him against the table. As a consequence of the incident, he developed pain in the cervical spine and lumbar spine. He was treated conservatively with physical therapy and medication and chiropractic treatments. Ultimately, he retained legal counsel and came under the direction of Dr. Salick, an orthopedic surgeon, on [redacted]. Dr. Salick evaluated the applicant and provided him with prescriptive analgesic medication. He eventually referred [redacted] to Dr. Ford for pain management.

In or about [redacted], under the auspices of Dr. Ford [redacted] underwent a series of three lumbar epidural steroid injections. He was then treated with a course of acupuncture treatments. Ultimately, he was declared permanent and stationary. He continued to experience residual pain in his cervical spine and lumbar spine. As a consequence of his [redacted] injury, the applicant was placed on temporary total disability status for a period of two years.

[redacted] also sustained injury in [redacted] while employed as a [redacted] for [redacted]. The applicant states, while pushing on a rack, he stepped on a piece of paper and did the splits. He sustained a right inguinal hernia. He subsequently underwent right inguinal hernia repair. Postoperatively, he was placed on temporary total disability status for Amitriptyline period of several months. He states he made a full recovery.

On [redacted] while employed as a fabric spreader for [redacted], sustained an injury when he lifted a fabric roll and placed it on his right shoulder. He then turned while carrying the fabric roll on his right shoulder. In doing so, he tripped on a wooden pallet, fell and fell into a rack. He sustained injury to his cervical spine, right shoulder and lower back. He was initially treated by the industrial physician. X-rays were obtained and he was provided with twelve physical therapy sessions. He then obtained legal counsel and came under the direction of Dr. Silbart. Dr. Silbart evaluated the applicant and placed him on temporary total disability status for a period of six to seven months. He was also provided with twelve physical therapy sessions. [redacted] states his case was settled. He states he made a "full recovery" from this injury.

Medications:

[redacted] is presently taking Tramadol 50 mg., Ibuprofen 600 mg. and Amitriptyline 10 mg.

Surgeries:

[redacted] is undergone two right inguinal hernia repairs.

SOCIAL HISTORY:

divorced and has three children. He was born in [redacted] and currently resides in [redacted], California.

PHYSICAL EXAMINATION:

CERVICAL SPINE EXAMINATION:

Palpation:

There was no tenderness to palpation. There was no muscle spasm present.

Range of Motion - Cervical Spine:

	<u>Right</u>	<u>Left</u>
Flexion	100%	
Extension	100%	
Lateral Rotation	100%	100%
Lateral Bending	100%	100%

Deep Tendon Reflexes:

	<u>Right</u>	<u>Left</u>
Biceps	2+	2+
Triceps	2+	2+
Brachioradialis	2+	2+

Motor Examination:

	<u>Right</u>	<u>Left</u>
Muscle group tested:		
Deltoid	5/5	5/5
Biceps	5/5	5/5
Triceps	5/5	5/5
Wrist flexors	5/5	5/5
Wrist extensors	5/5	5/5
Extrinsics	5/5	5/5
Intrinsics	5/5	5/5

Sensory Examination:

Sensory examination was normal in all the dermatomes of the upper extremities bilaterally.

Measurements:

Measurements were taken of the upper extremities bilaterally. The arms measured 30 cm. The forearms measured 20 cm. There was no atrophy or edema noted.

SHOULDER EXAMINATION:

Inspection:

The shoulders were normal to inspection. The AC joints were well located. No obvious deformities were noted.

Palpation:

The shoulders were normal to palpation. There was no tenderness. There was no erythema noted.

Range of Motion - Shoulders:

	<u>Right</u>	<u>Left</u>
Abduction	170	170
Forward Flexion	170	170
Internal Rotation	80	80
External Rotation	60	60
Extension	30	30

Impingement Sign:

Impingement sign was negative.

Apprehension Sign:

Apprehension sign was negative.

ELBOW EXAMINATION:

<u>Range of Motion - Elbows:</u>	<u>Right</u>	<u>Left</u>
Flexion	135	135
Extension	0	0
Supination	85	85
Pronation	85	85

WRIST AND HAND EXAMINATION:

Inspection:

There were no abnormalities noted to inspection. There was no swelling.

Palpation:

The wrists were nontender to palpation.

<u>Range of Motion - Wrists:</u>	<u>Right</u>	<u>Left</u>
Dorsiflexion	75	75
Palmar Flexion	75	75
Supination	85	85
Pronation	85	85
Radial Deviation	20	20
Ulnar Deviation	40	40

Range of Motion - Hands:

Range of motion of the hands was normal. The patient was able to bring the fingertips to the distal palmar crease.

Tinel's Sign:

Tinel's sign was negative bilaterally.

Phalen's Test:

Phalen's test was negative bilaterally.

<u>Motor Examination:</u>	<u>Right</u>	<u>Left</u>
EDC	5/5	5/5
FDS	5/5	5/5
FDP	5/5	5/5
FPL	5/5	5/5
FPB	5/5	5/5
EPL	5/5	5/5
EPB	5/5	5/5
APL	5/5	5/5
APB	5/5	5/5
Opponens	5/5	5/5
Intrinsics	5/5	5/5

Sensory Examination:

Sensory examination of the hands was normal.

THORACOLUMBAR SPINE EXAMINATION:

Palpation:

The thoracolumbar spine was nontender to palpation. There was no muscle spasm present.

<u>Range of Motion - Thoracic Spine:</u>	<u>Right</u>	<u>Left</u>
Flexion		90%
Extension		85%
Lateral Bending	100%	100%

<u>Range of Motion - Lumbar Spine:</u>	<u>Right</u>	<u>Left</u>
Flexion		80%
Extension		70%
Lateral Bending	90%	80%

Straight Leg Raising:

Straight leg raising was negative bilaterally.

Deep Tendon Reflexes:

	<u>Right</u>	<u>Left</u>
Knees	2+	2+
Ankles	2+	2+

Motor Examination:

	<u>Right</u>	<u>Left</u>
Muscle groups tested:		
Quadriceps	5/5	5/5
Hamstrings	5/5	5/5
Posterior tibialis	5/5	5/5
Anterior tibialis	5/5	5/5
Extensor hallucis longus	5/5	5/5
Gastrocnemius	5/5	5/5

Sensory Examination:

Sensory examination was normal in all the dermatomes of the lower extremities bilaterally.

Measurements:

Measurements were taken of the thighs and calves bilaterally. The thighs measured 43 cm. The calves measured 36 cm. There was no atrophy or edema noted.

MEDICAL RECORD REVIEW:

A report is reviewed from Dr. Hartyun I. Yousif of Linar Medical group dated . This is a treating physician's initial orthopaedic evaluation. The patient is seen for injuries he sustained on ' and . On ' he was loading some material. His coworker was pushing and he was pulling a cart when another coworker with a cart crossed their path and struck the patients femur. He immediately reported the injury to his manager who did not do anything in the form of medical treatment and in spite of the pain he continued working. He reminded the manager of the injury many times, however was never sent to a doctor.

On [redacted] he went on his own to Clinica Medica. His leg was swollen and he had surgical intervention. On [redacted] he was pushing approximately 200 molds for plants on a machine with a rail that was moving. Upon standing he hit his head and left ear. He had severe pain. He notified his manager who provided him with pain pills. He was advised that if he did not feel good to punch his time card and go home. Approximately five days later he started bleeding from his ear. He was seen by a physician and upon taking all of his medical bills to his employer his supervisor became very upset and told him "we do not care about your work any longer." Because of persistent pain he decided to seek legal advice. He has had no prior injuries and no prior surgeries. The patient complains of: 1) Constant severe headaches. 2) Neck pain. 3) Severe left ear pain. 4) Constant severe left foot pain. 5) His pain is electric shock like and throbbing. 6) Bending, climbing stairs and twisting makes his pain worse. 7) Since the injuries he has experienced shakiness, dizziness, heart palpitations, nervousness, depression, numbness, recurrent headaches and a tired feeling. Initial diagnostic impression: 1) Cerebral concussion/posttraumatic cephalgia. 2) Left earache/infection per patient. 3) Cervical spine strain/myofascialgia. 4) Left leg contusion/sprain. 5) Status post minor surgery of the left leg, extent unknown. Treatment plan: 1) Physical therapy. 2) X-rays of the skull, cervical spine, left tibia and left fibula. He is temporarily totally disabled.

A report is reviewed from Dr. Yousif dated [redacted]. This is a supplemental orthopaedic medical report. (Only page one of this report is submitted for review). The patient is being followed periodically to assess his progress and he is also receiving physical therapy in this office. He is making slow, but satisfactory progress. The following is a summary of evaluations. On [redacted] the patient's subjective complaints were essentially unchanged. He was complaining of a severe left earache for which he was taking Dicloxicillin. A request for medical records from Clinica Medica was made.

A report is reviewed from Dr. Yousif dated [redacted]. This is an attending physician's report. The patient's condition has improved as expected. He received a course of physical therapy with relief. Treatment was discontinued on [redacted]. Diagnoses: 1) Cervical spine strain/myofascialgia. 2) Left leg contusion/sprain. Treatment plan: 1) MRI of the cervical spine. 2) ENT consultation. He remains temporarily totally disabled.

A report is reviewed from Dr. Yousif dated [redacted]. This is a final orthopaedic consultation and permanent and stationary report. The patient complains of: 1) Earaches. 2) Neck pain. 3) Left leg pain. Diagnostic impression: 1) Left earache/infection per patient. 2) Cervical spine strain/myofascialgia. 3) Left leg contusion/sprain. 4) Status post minor surgery of the left leg, extent unknown. His condition is permanent and stationary.

Subjective factors of disability include intermittent slight neck pain, becoming slight to moderate with repetitive movements of the neck and work with the neck in a bent position; intermittent slight left leg pain; and earaches. Objective factors of disability include cervical spine tenderness and muscle spasm; restricted and painful range of motion of the cervical spine; disc bulging at C5-6 encroaching the spinal cord; and left leg tenderness and scars secondary to incision and drainage due to infection. He has sustained injuries to his cervical spine and left leg which has resulted in a preclusion from activities involving work with the neck in a bent position, as well as prolonged walking, standing and walking on uneven terrain. This injured worker may need vocational rehabilitation in the future if his job duties are ever extended beyond the recommended work restrictions. Future medical treatment: He has received the maximum benefits of conservative therapy at this time. However, future treatment such as physiotherapy and analgesics should be made available in the event of acute exacerbations of the present condition or otherwise renewed symptomatology. Provision for this eventuality should be made. There is no indication or evidence for apportionment.

A report is reviewed from Dr. Philip Sobol dated _____ This is a primary treating physician's initial orthopaedic evaluation. The patient is seen for the injuries he sustained on _____ and _____. He complains of: 1) Neck pain extending to his left upper trapezius and levator scapular regions. The neck pain is accompanied by headaches occurring one to two times per week. 2) Occasional residual pain at the contusion site and subsequent hematoma evacuation of his left lower leg. Diagnoses: 1) Residuals of cervical musculoligamentous strain with attendant myofascial strain of left upper trapezius and levator scapula muscles. 2) Degenerative disc disease, C5-6, with 2 mm central disc bulge, per MRI dated _____. 3) History of contusion injury, left lower leg, with subsequent development of hematoma necessitating excision and drainage, _____ per patient history. Treatment plan: 1) The superior border of the left scapula is infiltrated with medication which provides some degree of improvement. 2) A short course of physical therapy totaling approximately four weeks. 3) Follow-up in approximately two to three weeks. He is to return to modified duties with restrictions of no activities requiring heavy lifting and repetitive or forceful pushing and pulling using the left upper extremity. His left lower leg residuals are a direct result of the contusion type injury sustained on _____. His neck and left periscapular complaints are considered solely industrial in nature and developed as a result of the _____ injury.

A report is reviewed from Dr. Sobol dated _____ This is a handwritten attending physician's report. The patient has had no change in his condition. Diagnoses: 1) Cervical spine strain. 2) Cervical disc degeneration. Treatment plan: Pending therapy three times per week. He is to continue modified duties with restrictions of no heavy lifting and no repetitive reaching, pushing or pulling.

A report is reviewed from Dr. Sobol dated [redacted]. This is a handwritten attending physician's report. The patient's condition has improved as expected. Diagnoses: 1) Cervical spine strain. 2) Residual left lower extremity pain. Treatment plan: physical therapy three times per week. He is temporarily totally disabled.

A report is reviewed from Dr. Sobol dated [redacted]. This is a primary treating physician's orthopaedic permanent and stationary report. The patient estimates an overall 80% improvement with regard to his neck and left periscapular complaints. He continues to experience some residual pain at the site of the prior contusion and hematoma drainage with respect to his left lower leg, primarily during periods of "weather." His headaches have completely resolved over the course of the past four to six weeks. Diagnoses: 1) Residuals of cervical musculoligamentous sprain/strain with attendant myofascial strain of left upper trapezius and levator scapulae muscles. 2) Degenerative disc disease with 2 mm central disc bulge at C5-6, per MRI dated [redacted]. 3) History of contusion injury, left lower leg, with subsequent development of a hematoma necessitating excision and drainage, [redacted], per patient history. His condition is permanent and stationary. Subjective factors of disability include intermittent slight neck and left upper trapezial/levator scapulae pain at rest, increasing to frequent slight, becoming moderate with activities requiring heavy lifting and repetitive overhead work using both upper extremities; and occasional minimal to slight left lower leg pain at rest, increasing to intermittent slight with very prolonged weight bearing. Objective factors of disability include degenerative disc disease with 2 mm disc bulge at C5-6 per MRI dated [redacted], residual cervical, suboccipital and paraspinal spasm, with spasm involving the left upper trapezial and levator scapulae muscles; and a scar, left lower leg, at the site of prior contusion and hematoma, necessitating excision and drainage, with a small palpable fascial defect at the contusion and excision site. For his cervical spine residuals he is precluded from activities requiring heavy lifting and repetitive overhead work using both upper extremities. It is not felt that any additional work restrictions are warranted for his left lower leg and he should be rated on residual factors of disability alone. Following the [redacted] injury he did not resume employment with [redacted].

In approximately [redacted] he began employment with [redacted], performing janitorial and maintenance type duties, noting that his current duties are much lighter in nature than those performed with his prior employer. He would be considered physically incapable of resuming his preinjury duties for [redacted] and as such would be considered medically eligible for vocational rehabilitation. However, it is felt that he may continue his current course of employment with [redacted].

Future medical treatment: No further treatment is warranted for his left lower extremity. For his cervical spine he may experience exacerbations at a future date necessitating brief courses of physiotherapy totaling two to four weeks in duration, possible trigger point injections, as well as appropriate pharmacotherapeutic agents.

There is no basis for apportionment to preexisting or nonindustrial factors. His left lower leg residuals are a direct result of the industrial injury with his cervical spine residuals considered a direct result of the industrial injury.

A report is reviewed from Dr. Angel B. Pena dated . This is a doctor's first report of occupational injury or illness. Today while standing next to a table, the table was hit by a rack and it hit the patient on the right side of his waist. He complains of right hip and back pain. Diagnoses: 1) Sprain/strain, hip. 2) Contusion, hip. Treatment plan: 1) Dispense reusable cold packs. 2) Prescribe Motrin 800 mg and Tylenol. 3) Ice. 4) Rest. 5) Elevation. He is temporarily totally disabled.

A report is reviewed from Kennedy Occupational Medical Center dated This is a handwritten work status slip. (Physician signature is illegible). The patient remains temporarily totally disabled.

A report is reviewed from Kennedy Occupational Medical Center dated This is a handwritten work status slip. (Physician signature is illegible). The patient is to return to work without restrictions on

A report is reviewed from Chiropractor Gilberto Gomez dated . This is a doctor's first report of occupational injury or illness. On the patient was struck from behind by a forklift carrying rolls of fabric and was pinned against a work table. He complains of: 1) Headaches. 2) Difficulty sleeping. 3) Fatigue. 4) Neck pain. 5) Mid and low back pain. 6) Muscle pain. 7) Discomfort in both arms and lower limbs. 8) Lower abdominal pain. 9) Internal problems. Diagnoses: 1) Cervicalgia. 2) Sprain/strain, thoracic spine. 3) Backache. 4) Lumbalgia. 5) Muscle spasms. 6) Pain in forearm. 7) Synovitis. 8) Tenosynovitis. Treatment plan: 1) Chiropractic manipulation, anatomotor, diathermy, hand held unit massage, electric stimulation and ultrasound. He is advised to come every day for the first two weeks and thereafter three times per week. 2) MRI and NCVS. 3) He will be referred to an internal specialist and an orthopedist. He is temporarily totally disabled.

A report is reviewed from Dr. Zinovy Lekht dated This is an NCVS of the bilateral upper extremities. Abnormal findings: 1) Decreased amplitude of the action potentials of the right and left median motor nerves. 2) Prolonged distal latency of the action potential of the right ulnar motor nerve. Decreased amplitude of the action potential of the left ulnar motor nerve. 3) Decreased amplitude of the action potentials of the right and left medial motor nerves.

Impression: These electrodiagnostic abnormalities can be seen in patients with peripheral motor neuropathy. The presence of abnormalities in motor nerves can be attributed to lesions at different levels of these nerves. Although this study does not demonstrate the presence of proximal lesion, the abnormalities in motor nerves can also be seen in patients with C5, C6, C7 and C8 radiculopathy on both sides. Clinical correlation is recommended.

A report is reviewed from Dr. Sim C. Hoffman of Advanced Professional Imaging Medical Group dated . This is an MRI of the lumbar spine. Impression: 1) The L1-2 level shows a 1 to 2 mm posterior disc protrusion present. A Schmorl's node is seen at the L1 and L2 vertebral bodies. The neural foramina appear patent. 2) The L2-3 level shows no evidence of a disc protrusion present. The neural foramina appear patent. Schmorl's node is present at the L2 and L3 disc levels. 3) The L4-5 level shows a 2 mm central disc protrusion present. The neural foramina appear patent. Moderate bilateral hypertrophic facet changes are present.

A report is reviewed from Dr. Lekht dated . This is an NCVS of the bilateral lower extremities. Abnormal findings: Decreased amplitude of action potentials of the right and left peroneal motor nerves. Impression: These electroneurodiagnostic abnormalities can be seen in patients with peripheral motor neuropathy. The presence of abnormalities in motor nerves can be attributed to lesions at different levels of these nerves. Although this study does not demonstrate the present of proximal lesions, the abnormalities in motor nerves can also be seen in L4 and L5 radiculopathy on both sides. Clinical correlation is recommended.

A report is reviewed from Dr. Darrell H. Burstein dated . This is an internal medicine consultation and is eight pages in length. Diagnostic impression: 1) No evidence of work related internal medicine injury. 2) Lower abdominal pain secondary to: A) Crush injury to abdominal wall and/or. B) Referred pain from spinal injury. 3) Musculoskeletal diagnoses deferred to Dr. Gomez. Treatment plan: CT scan of the abdomen and blood work are pending. The complete medical file is requested before coming to any final conclusions, however it does seem probable that he has not sustained a work related internal medicine disorder and that his lower abdominal pain emanates from a crush injury to the abdominal wall and/or is referred pain from his lumbar spine injury.

A report is reviewed from Dr. Gustav Salkinder dated . This is a comprehensive orthopaedic consultation. The patient is seen for the injury he sustained on . He was lifting a roll of fabric onto a table when he was struck by a forklift which was carrying 800 pounds of fabric rolls. The forklift hit the right side of his back. He landed on the table, hitting his chest. He was unconscious for a few minutes and when he awoke he had immediate pain in his mid and lower back with radiating pain to both legs. He also subsequently developed neck pain. He was off work for approximately a week and then went back to work, however could not tolerate his job duties due to the pain. He had to quit his job on . due to his back pain.

He sustained an industrial injury to his left foot and left ear in . He received treatment and recovered. He underwent left leg surgery in . The patient complains of: 1) Constant severe sharp middle and low back pain radiating to both lower extremities with numbness and tingling in both legs. He has some weakness in both lower extremities. He cannot walk, stand or be in one position for prolonged periods of time. 2) Neck pain and stiffness which is slight to moderate and intermittent, aggravated by repetitive bending and twisting of the neck. Diagnostic impression: 1) Musculoligamentous sprain/strain of the cervical spine. 2) Musculoligamentous sprain/strain of the thoracic spine. 3) Musculoligamentous sprain/strain of the lumbosacral spine. 4) Lumbar radiculitis. 5) Rule out lumbar radiculopathy. 6) There is a 1-2 mm posterior disc protrusion at the L1-2 level with patent neural foramina per MRI. 7) 2 mm central disc protrusion at the L4-5 level with patent neural foramina, moderate bilateral hypertrophic facet changes present per MRI. 8) Bilateral lumbar facet syndrome confirmed by MRI. Treatment plan: 1) He should continue conservative treatment in the form of physical therapy and chiropractic treatment three times per week for six weeks. 2) Prescribe Motrin 800 mg, Vicodin Extra Strength and Soma. 3) He is given detailed instructions for a home exercise program to increase flexibility and for strengthening of the lumbosacral spine. 4) He is instructed to avoid activities exerting strain on the lumbosacral spine. 5) He is advised that if he continues to remain symptomatic he will require lumbar epidural steroid injections to alleviate his symptoms. 6) Follow-up in six weeks. He is temporarily totally disabled. The injuries sustained which resulted in disability and the need for medical treatment arose out of and occurred during the course of his employment and were a direct result and sole contributing factor of the industrial injury.

A report is reviewed from Chiropractor Gomez dated . This is a primary treating physician's progress report. The patient complains of exacerbating, sharp, throbbing: 1) Neck, mid and low back pain. 2) Bilateral arm pain. 3) Lower limb pain. 4) Internal problems. Diagnoses: 1) Cervicalgia. 2) Sprain/strain, thoracic spine. 3) Lumbalgia. Treatment plan: 1) Chiropractic manipulation, anatomotor, diathermy and hand held unit massage three times per week for four weeks. 2) Dispense lumbar support. 3) Clinical and home use of a GEMS TENS unit and supplies. He remains temporarily totally disabled.

A report is reviewed from Dr. Natalia L. Ratiner dated . This is a neurological evaluation medical-legal report. The patient is seen for the injury he sustained on . He now states that he was hit by a loaded forklift on his back, neck and occipital area. He lost consciousness for an unknown period of time. His body flexed on the table. He was woken up by the manager and upon awakening he felt a bad headache and pain in his neck, both shoulders, low back and both legs. About one hour later both legs became swollen. One week later he quit his job.

The patient complains of: 1) Intermittent generalized headaches with dizziness. 2) Constant neck pain spreading to both shoulders and both arms associated with numbness in both hands. 3) Constant low back pain with weakness in both legs and intermittent numbness in both upper extremities. 4) Painful urination and bowel movement processes. Impression: 1) Status post closed head injury with posttraumatic head syndrome manifested with headache and dizziness. 2) Cervical paraspinal muscle strain, posttraumatic, radicular symptomatology in both upper extremities, rule out cervical discopathy. 3) Thoracic and lumbosacral paraspinal muscle strain, posttraumatic, with multilevel discopathy by MRI, rule out myelopathy. Treatment plan: 1) MRI of the head to rule out posttraumatic brain pathology. 2) MRI of the cervical spine to rule out discopathy. 3) EMG of the bilateral upper extremities and bilateral lower extremities to rule out radiculopathy. 4) Prescribe Fiorinal. 5) It is suggested that he continue to receive care with physical therapy and chiropractic manipulation in Chiropractor Gomez's office. All of the problems are related to the industrial injury.

A report is reviewed from Dr. Hoffman dated . This is an MRI of the cervical spine. Impression: 1) The C4-5 level shows hypertrophic changes anteriorly present. A 2 to 3 mm posterior disc protrusion is present. 2) The C5-6 level shows hypertrophic changes anteriorly present. A 3 mm mid posterior disc protrusion consistent with a subligamentous disc herniation is present. There is narrowing in the AP and right lateral recess diameter.

A report is reviewed from Dr. Hoffman dated .. This is an MRI of the head. Impression: Negative MRI of the head.

A report is reviewed from Dr. Peter S. Lorman dated . This is an AOE/COE evaluation. The patient is seen for the injury he sustained on . He now states that he was struck in the right hip by a forklift. He denies any prior industrial or nonindustrial injuries and any prior surgeries. The patient complains of: 1) Vague pain involving his lower cervical spine. This pain radiates to his shoulders. He has occasional headaches and occasional dizziness. 2) Vague pain involving his lower lumbar spine. The pain radiates to his bilateral legs. X-rays of the cervical spine reveal no evidence of fracture, dislocation or signs of intrinsic bony pathology. There are no signs suggestive of disc herniation. There is no evidence of congenital anomalies present. The open mouth view reveals the odontoid process to be within normal limits. There is no evidence of calcification within the soft tissues. X-rays of the lower spine reveal no evidence of fracture, dislocation or signs of intrinsic bony pathology. There are no signs suggestive of disc herniation. There is no evidence of congenital anomalies present. The soft tissue shadows appear to be within normal limits. Diagnoses: 1) History of contusion, right hip, without objective evidence of pathology. 2) No objective evidence of cervical spinal pathology present. 3) No objective evidence of lumbar spinal pathology present. His condition is permanent and stationary.

Subjective factors of disability include residual symptomatology that would be classified as minimal, i.e. pain which would constitute an annoyance but cause no handicap in the performance of the particular work activity and would be considered as non-ratable permanent disability. The frequency of his complaints would be classified as occasional. Objective factors of disability include a normal evaluation. He has intact sensation, circulation and muscle strength without evidence of atrophy or muscular weakness. He has a normal MRI. He has EMG testing showing no evidence of nerve root pressure or motor involvement. There is no objective evidence of pathology present. Vocational rehabilitation is not indicated. Disability is not indicated; there is no objective basis for disability beyond He is not a qualified injured worker. Future medical treatment: Treatment is not required at this time or in the future. Apportionment is not indicated.

A report is reviewed from Chiropractor Gomez dated . This is a primary treating physician's progress report. The patient complains of: 1) Headaches. 2) Constant, sharp, shooting pain, muscle discomfort and stiffness in the neck radiating to his entire back. 3) Pain radiating down to his legs, causing numbness in his feet. Diagnoses remain unchanged. Treatment plan: Chiropractic manipulation, anatomotor, diathermy and hand held unit massage three times per week for four weeks. He remains temporarily totally disabled.

A deposition transcript of dated . is reviewed which is 49 pages in length.

A report is reviewed from Dr. Lorman dated . This is a supplemental report for a review of medical records and is four pages in length.

A report is reviewed from Chiropractor Gomez dated . This is a primary treating physician's progress report. The patient complains of: 1) Headaches. 2) Tension in his neck. 3) Constant, jabbing pain in his mid and low back which radiates to both legs. He also has constant low back stiffness which radiates down to both legs, causing weakness. Diagnoses remain unchanged. Treatment plan: Chiropractic manipulation, anatomotor, diathermy and hand held unit massage three times per week for four weeks. 2) Dispense lumbar support. He remains temporarily totally disabled.

A report is reviewed from Dr. Salkidner dated . This is a handwritten treating physician's progress report. The patient complains of neck, upper and lower back pain with limited function. Diagnoses: 1) Disc disease, cervical spine, lumbar spine. 2) Sprain, cervical spine, thoracic spine, lumbar spine. 3) Radiculopathy, lumbar. Treatment plan: 1) Continue physical therapy and chiropractic treatment two to three times per week for one month. 2) Continue home exercises and TENS. 3) Continue Naproxen, Soma ad Vicodin. 4) The paravertebral muscles are injected with Depo-Medrol and Lidocaine. He remains temporarily totally disabled.

A report is reviewed from Dr. Lorman dated [redacted]. This is a supplemental report for review of medical records. (Only page one of this report is submitted for review).

A report is reviewed from Dr. Lorman dated [redacted]. This is a supplemental report for a review of medical records and is three pages in length. The report of [redacted] is amended. Apportionment is indicated. 100% of the cervical spinal and lumbar spinal pathology is apportioned to the [redacted] injury based upon the fact that the patient required prolonged medical treatment, incurred medical bills of over \$2,500.00 and had a permanent work restrictions placed on him prior to the time of the [redacted] episode.

A report is reviewed from Dr. Salkinder dated [redacted]. This is a handwritten treating physician's progress report. The patient complains of persistent neck and lower back pain. Blocks gave him only minimal relief. Diagnoses: 1) Discogenic disease, cervical spine, lumbar spine. 2) Lumbar radiculitis. Treatment plan: 1) Pain management consultation. 2) Continue chiropractic treatment. 3) Continue Soma and Ibuprofen. He remains temporarily totally disabled.

A report is reviewed from Chiropractor Gomez dated [redacted]. This is a primary treating physician's progress report. The patient complains of: 1) Constant sharp throbbing neck, mid and low back pain radiating to both legs. 2) Tightness in both shoulders. 3) Tiredness and weakness in both calves. Diagnoses remain unchanged. Treatment plan: 1) Chiropractic manipulation, anatomotor, diathermy, hand held unit massage and electrical muscle stimulation two times per week for four weeks. 2) Dispense a walking cane. He remains temporarily totally disabled.

A report is reviewed from Dr. Lorman dated [redacted]. This is a supplemental report for a review of medical records and is two pages in length.

A report is reviewed from Chiropractor Gomez dated [redacted]. This is a primary treating physician's progress report. The patient complains of: 1) Continuous headaches associated with sharp throbbing pain in his neck, mid and low back. 2) Occasional numbness and weakness in his right leg. 3) Lower abdominal pain. Diagnoses remain unchanged. Treatment plan: Chiropractic manipulation, anatomotor, diathermy and hand held unit massage three times per week for four weeks. He remains temporarily totally disabled.

A report is reviewed from Chiropractor Gomez dated [redacted]. This is a primary treating physician's progress report. The patient complains of: 1) Constant tension and exasperating(sic) pain in his neck associated with headaches. 2) Sharp mid back pain. 3) Constant throbbing low back pain radiating to his right leg, causing weakness and soreness.

Diagnoses remain unchanged. Treatment plan: Chiropractic manipulation, anatomotor, diathermy, hand held unit massage and electrical muscle stimulation three times per week for four weeks. He remains temporarily totally disabled.

A report is reviewed from Dr. Salkinder dated This is a handwritten treating physician's progress report. The patient complains of neck and low back pain. Physical therapy and acupuncture are helping. Diagnoses: 1) Disc disease, cervical spine, lumbar spine. 2) Lumbar radiculitis. Treatment plan: 1) Pain management consultation. 2) Continue physical therapy and chiropractic treatment three times per week for six weeks. 3) Acupuncture. 4) Continue medications.

A report is reviewed from Chiropractor Gomez dated This is a primary treating physician's progress report. The patient complains of: 1) Constant less than moderate pain in his neck and mid back. 2) More than moderate pain in both arms. 3) Constant shooting pain associated with a burning sensation in his low back which radiates to his lower extremities. Diagnoses remain unchanged. Treatment plan: 1) Manipulation, anatomotor, diathermy, hand held unit massage and electric muscle stimulation three times per week for four weeks. 2) Dispense Sombra. He remains temporarily totally disabled.

A report is reviewed from Dr. Mary Jo Ford of Phoenix Pain Medicine dated This is an initial pain management consultation. The patient is seen for the injury he sustained on He complains of persistent: 1) Upper and lower back pain. 2) Headaches. 3) Leg pain. 4) Frequent neck pain. 5) The pain is associated with numbness, tingling and weakness in both arms and both legs. 6) His pain is aggravated by walking, standing, sitting and lying down for an extended time period. 7) Frequent headaches since the injury. 8) Feelings of nervousness, nausea and anxiety. 9) The pain routinely disrupts his sleep. Assessment: 1) Lumbar strain and sprain. 2) Lumbar disc protrusions at the L1-2 and L4-5 levels. 3) Bilateral facet hypertrophy at the L3-4, L4-5 and L5-S1 levels. 4) Thoracic strain and sprain. 5) Cervical strain and sprain. 6) Disc protrusions at the C4-5 and C5-6 levels. 7) Headaches. 8) Pain related anxiety and sleep disorder. Treatment plan: 1) A series of lumbar epidural steroid injections. 2) Continue to regularly participate in physical therapy and chiropractic treatment sessions in conjunction with the injections. 3) Prescribe Soma, Darvocet and Zantac. 4) Follow-up one to two weeks following the initial injections.

A report is reviewed from Chiropractor Gomez dated This is a primary treating physician's progress report. The patient complains of: 1) Continuous sharp pain in his neck, mid and low back associated with tension and stiffness which radiates to his right leg. 2) Frequent headaches. Diagnoses: 1) 3 mm in C5-6, narrowing in recess diameter, disc herniation. 2) Disc disease in cervical, thoracic and lumbar vertebrae. 3) 2 mm in L4-5 level, disc protrusion, bilateral hypertrophic changes.

Treatment plan: 1) Anatomotor, diathermy, hand held unit massage, chiropractic manipulation and electrical muscle stimulation three times per week for four weeks. 2) Dispense a pack of four electrodes. He remains temporarily totally disabled.

A report is reviewed from Dr. Ford of Comprehensive Outpatient Surgery Center dated

This is a procedure report. Pre- and post-operative diagnoses: 1) Lumbar strain and sprain. 2) Lumbar disc protrusions at L1-2 and L4-5. 3) Bilateral facet hypertrophy at L3-4, L4-5 and L5-S1. 4) Thoracic strain and sprain. 5) Cervical strain and sprain. 6) Cervical disc protrusions at C4-5 and C5-6. 7) Headaches. 8) Pain related anxiety and sleep disorder. Procedure performed: 1) Caudal epidural steroid injection using an epidural catheter with Kenalog 30 mg/ml and 0.5% Xylocaine 8 cc. 2) Multiplanar fluoroscopy. 3) Epidurogram. 4) Intra-operative application of four lead, two channel interferential electrical stimulation unit with 30 minute physician attended treatment protocol.

A report is reviewed from Dr. Salkinder dated . This is a handwritten treating physician's progress report. The patient complains of: 1) Neck pain. 2) Low back pain. 3) Pain radiating into his right leg. 4) Tingling of his foot. He has had slow improvement with treatment. Diagnoses: 1) Cervical/lumbar disc disease. 2) Cervical/lumbar radiculitis. Treatment plan: 1) Continue physical therapy and chiropractic treatment for six weeks. 2) Finish epidurals times two. 3) Continue home exercises. 4) Continue medications. He remains temporarily totally disabled.

A report is reviewed from Dr. Ford of Comprehensive Outpatient Surgery Center dated .

This is a procedure report. Pre- and post-operative diagnoses: 1) Lumbar strain and sprain. 2) Lumbar disc protrusions at L1-2 and L4-5. 3) Bilateral facet hypertrophy at L3-4, L4-5 and L5-S1. 4) Thoracic strain and sprain. 5) Cervical strain and sprain. 6) Cervical disc protrusions at C4-5 and C5-6. 7) Headaches. 8) Pain related anxiety and sleep disorder. Procedure performed: 1) Bilateral transforaminal epidural steroid injections at the L5-S1 level, one each side, injected with Kenalog 15 mg/ml with 1% Xylocaine 2 cc. 2) Multiplanar fluoroscopy. 3) Epidurogram. 4) Intra-operative application of four lead, two channel interferential electrical stimulation unit with 30 minute physician attended treatment protocol.

A report is reviewed from Dr. Ford of Comprehensive Outpatient Surgery Center dated

This is a procedure report. Pre- and post-operative diagnoses: 1) Lumbar strain and sprain. 2) Lumbar disc protrusions at L1-2 and L4-5. 3) Bilateral facet hypertrophy at L3-4, L4-5 and L5-S1. 4) Thoracic strain and sprain. 5) Cervical strain and sprain. 6) Disc protrusions at C4-5 and C5-6. 7) Headaches. 8) Pain related anxiety and sleep disorder. Procedure performed: 1) Bilateral dorsomedial branch blocks to the facet joints at the L3-4, L4-5 and L5-S1 levels. 2) Multiplanar fluoroscopy. 3) Intra-operative application of four lead, two channel interferential electrical stimulation unit with 30 minute physician attended treatment protocol.

A report is reviewed from Dr. Ford dated [redacted] This is a follow-up evaluation. The patient recently had lumbar epidural and lumbar facet joint injections with minimal improvement in his intractable low back pain. He also developed a rash following these injections. Treatment plan: 1) Acute treatment of his rash and attempts to optimize his analgesic medications in conjunction with physiotherapy and supportive care. 2) Prescribe Darvocet, Zantac, Soma, Motrin 800 mg and Lidex cream. 3) Continue physiotherapy three times per week. 4) Follow-up in one month.

A report is reviewed from Chiropractor Gilberto Gomez dated [redacted] This is a primary treating physician's progress report. The patient complains of: 1) Continuous throbbing neck pain associated with tension. 2) Constant shooting mid back pain. 3) Continuous exasperating low back pain radiating to his right leg. Diagnoses remain unchanged. Treatment plan: Anatomotor, diathermy, electrical muscle stimulation, hand held unit massage and chiropractic manipulation three times per week for four weeks. He remains temporarily totally disabled.

A report is reviewed from Dr. Salkinder dated [redacted] This is a final orthopaedic consultation evaluation. The patient complains of: 1) Slight constant neck pain with intermittent radiation to his bilateral upper extremities, increasing to slight to moderate and constant with repetitive bending, twisting and repetitive looking up and down, as well as heavy lifting. 2) Slight to moderate constant low back pain, increasing to moderate and severe with repetitive bending, stooping, twisting, prolonged standing, walking sitting in fixed positions and heavy lifting. Final diagnostic impression: 1) Musculoligamentous sprain/strain of the cervical spine, improved. 2) Cervical radiculitis. 3) 2-3 mm posterior disc protrusion at C4-5 level per MRI. 4) 3 mm mid posterior disc protrusion at C5-6 level with subligamentous disc herniation and narrowing of the AP and right lateral recess diameter per MRI. 5) Musculoligamentous sprain/strain of the lumbosacral spine, improved. 6) Lumbar radiculitis. 7) Rule out lumbar radiculopathy. 8) 1-2 mm posterior disc protrusion at the L1-2 level with patent neural foramina per MRI. 9) 2 mm central disc protrusion at the L4-5 level with patent neural foramina, moderate bilateral hypertrophic facet changes present, per MRI. 10) Bilateral lumbar facet syndrome confirmed by MRI. His condition has reached a therapeutic plateau from further surgical orthopaedic consideration. He is referred back to his primary treating physician, Chiropractor Gomez, to complete his therapy. Subjective factors of disability include slight constant neck pain radiating to his bilateral upper extremities, increasing to slight to moderate and constant with repetitive bending, twisting and repetitive looking up and down, as well as heavy lifting; and slight to moderate constant low back pain, increasing to moderate and severe with repetitive bending, stooping, twisting, prolonged standing, walking, sitting in fixed positions and heavy lifting. Objective factors of disability include limited range of motion of the cervical spine and lumbar spine; positive findings on MRI's of the cervical spine and lumbosacral spine; and positive right straight leg raising.

For his cervical spine and lumbar spine he has a work restriction of a limitation to light work only. He is considered a qualified injured worker in need of vocational rehabilitation. Future medical treatment: Future treatment should be awarded as follows on an industrial basis: 1) Reevaluation by an orthopaedic surgeon if his condition deteriorates. 2) Additional physical therapy and chiropractic treatment for exacerbations of his pain. 3) Additional diagnostic studies and testing if his condition worsens. 4) Possible surgical treatment of the cervical and/or lumbar disc disease if his condition deteriorates. 5) Refills of analgesic medication and replacement of orthopaedic appliances as needed. 6) Additional pain management procedures such as lumbar epidural steroid injections if his condition deteriorates. Apportionment is not an issue.

A report is reviewed from Dr. Lorman dated . This is a supplemental report for a review of medical records and is two pages in length.

A report is reviewed from Dr. Noel Lee Chun of Phoenix Pain Medicine dated . This is a follow-up evaluation. The patient continues to have persistent problems with axial low back pain and some problems with neck pain. His rash has been steadily resolving somewhat. Treatment plan: 1) Several treatment options are discussed including diagnostic lumbar facet joint injections versus diagnostic provocative lumbar discography for further evaluation. 2) He is also a potential candidate for continued attempts to optimize his analgesic medications versus consideration of surgical intervention for his back pain. 3) Prescribe Zantac, Naprosyn 375 mg, Lorcet 10/650 mg, Valium 5 mg, Zostrix cream and topical Lidoderm patches. 4) Continue physiotherapy three times per week. 5) Follow-up in one month.

A report is reviewed from Chiropractor Gomez dated . This is a return to work order. The patient will be able to return to work on . For his cervical spine he is precluded from heavy work. For his thoracic and lumbar spine his disability results in a limitation to semi-sedentary work.

A report is reviewed from Chiropractor Gomez dated . This is a primary treating physician's permanent and stationary chiropractic consultation. The patient complains of: 1) headaches. 2) Pain and discomfort in his neck, mdi back and low back accentuated to the left, middle and right sides. 3) Pain in the bilateral legs with residual soreness more on the right side. 4) Constant pain at the right inguinal area which is moderate in nature. His symptoms are improving. Current diagnoses: 1) Cervicalgia. 2) Cervical torticollis. 3) Cervical muscle spasm. 4) The C4-5 level shows hypertrophic changes anteriorly present. A 2 to 3 mm disc protrusion is present as per MRI. The C5-6 level shows hypertrophic changes anteriorly present. A 3 mm mid posterior disc protrusion consistent with a subligamentous disc herniation is present. There is narrowing in the AP and right lateral recess diameter as per MRI.

5) Pain in thoracic spine. 6) Thoracic muscle spasm. 7) Lumbago. 8) Sprain/strain, lumbar spine. 9) Lumbar muscle spasm. 10) The L1-2 level shows a 1 to 2 mm posterior protrusion present. A Schmorl's node is seen at the L1 and L2 vertebral bodies. The neural foramina appear patent as per MRI. The L2-3 level shows no evidence of a disc protrusion present. The neural foramina appear patent. Schmorl's node is present at the L2 and L3 disc levels as per MRI. The L4-5 level shows a 2 mm central disc protrusion present. The neural foramina appear patent. Moderate bilateral hypertrophic facet changes are present as per MRI. His condition is permanent and stationary. Subjective factors of disability include constant moderate neck pain which increases with bending, stooping, lifting, pushing, pulling and climbing or other activities involving comparable physical effort; and constant moderate mid back and low back pain which increases with bending, stooping, lifting, pushing, pulling and climbing or other activities involving comparable physical effort. Objective factors of disability include tenderness to palpation of the cervical spine; tenderness to palpation of the dorsolumbar spine; limited range of motion of the cervical spine; limited range of motion of the dorsolumbar spine; and positive MRI and NCVS. For his neck he is precluded from heavy work which contemplates that he has lost approximately 50% of his preinjury capacity for performing such activities as bending, stooping, lifting, pushing, pulling and climbing or other activities involving comparable physical effort. For his back he has a disability resulting in a limitation to light work which contemplates that he can do work in a standing or walking position with a minimum of demands for physical effort. He is a qualified injured worker who will need vocational rehabilitation services, testing and counseling or special placement to return to work. Future medical treatment: He may require future treatment in the form of: 1) Reevaluation by an orthopaedic surgeon if his condition deteriorates. 2) Additional physical therapy and chiropractic treatments for exacerbations of his musculoskeletal pain. 3) Additional diagnostic studies and testing if his condition worsens. 4) Surgery for the cervical and/or lumbar disc disease if his condition deteriorates. 5) Refills of analgesic medications and replacement of orthopaedic appliances as needed. 6) Additional pain management procedures such as lumbar epidural steroid injections if his condition deteriorates. No apportionment is given. The current symptomatology and related disability is directly related to the industrial injury.

A report is reviewed from Dr. P.A. Lucero of Integrative Industrial and Family Practice Medical Clinics dated . This is an annexure to primary treating doctor's first report of occupational injury or illness and request for authorization. On the patient was pulling a rolling rack that measured 4 x 6 x 7 in dimension containing rolls of fabric which weighed a total of approximately 800 pounds. He usually had an assistant, however at that time his coworkers were unavailable to assist him. He was walking backwards towards his table which was approximately 24 feet away as he pulled the rolling rack when he stepped on a paper lying on the wooden floor with his left foot, causing him to lose his balance. He tried to maintain his balance, supporting himself with his right foot, however twisted it in the process.

He tried to break his fall by forcefully holding onto the rolling rack using both hands, pulling with his shoulders to support himself which caused immediate pain in his neck and shoulders. He landed in a sitting position on his buttocks with his legs apart, injuring his right testicle and felt excruciating pain in his right inguinal area, his entire low back, right thigh and neck. He felt a throbbing ache in his head due to severe pain sustained on impact. He remained in the same position for a few minutes, waiting for the pain to subside. He did not immediately seek help since he knew that everybody was on the first floor. He was able to hoist himself up as the pain decreased by holding onto the rack. He denies any prior injuries. Prior surgeries include a hernia repair in The patient complains of: 1) Headaches associated with nausea, neck pain and vision problems due to lack of sleep. 2) Neck pain radiating between the shoulder blades associated with stiffness, limited motion, headaches and sleep interruption. 3) Right shoulder pain radiating to his right arm associated with weakness and popping. 4) Left shoulder pain associated with weakness. 5) Low back pain radiating to his groin, right thigh, right calf and right foot associated with tingling and popping, stiffness, limited motion, weakness and sleep interruption. 6) Right foot pain associated with numbness, tingling, weakness and sleep interruption. Diagnoses: 1) History of musculoligamentous stretch injury to the cervical/thoraco/lumbar region with associated radiation to the right lower extremity. 2) Status post contusion of right foot, resolved. 3) Status post contusion of shoulders, resolved. Treatment plan: 1) Physiotherapy three times per week for four weeks. 2) Prescribe Motrin 800 mg. 3) Computer analyzed muscle strength testing. 4) X-rays of the cervical spine, thoracic spine and lumbosacral spine. 5) MRI of the neck. 6) Educational classes for the low back. 7) Dispense educational pamphlets for a home regimen of range of motion exercise for the neck and back. 8) Follow-up on He is temporarily totally disabled. His condition is attributable to the industrial injury.

A report is reviewed from Dr. Steven B. Silbart dated ; This is a primary treating physician's comprehensive orthopaedic medical-legal initial evaluation. (Pages two through six of this report are not submitted for review). On the patient was lifting a large heavy roll of fabric which weighed approximately 60 pounds when he was injured. He complains of: 1) Intermittent midline and right paraspinal and right trapezius discomfort which is mild. He has right sided headaches which he feels are related to his neck. He will get a headache up to three times per week. The pain radiates from his shoulder into his neck and he has numbness in both hands. His pain is increased by twisting, turning or gazing upward. He is able to perform activities at or above shoulder level, however with right shoulder pain. He will wake up due to neck pain. 2) Constant right shoulder discomfort which is mild to greater than mild, less than severe. His pain increases with lifting, pushing and pulling, as well as with above shoulder level activities with the right upper extremity. He is not able to sleep on his shoulder. His shoulder pops. He has painful range of motion. He has pain with gripping and grasping.

3) Constant midline and bilateral lumbosacral paraspinous discomfort, greater on the right, which is greater than mild, less than severe. He has constant radiation down the posterior aspect of his thigh to the bottom of his right foot. He has numbness and tingling over the same distribution of the right lower extremity including his toes. His pain increases with bending, stooping, sitting for longer than five minutes, standing or walking for more than 10 minutes or lifting more than 10 pounds. He is limping on the right side due to back pain. He wakes up during the night due to back pain. 4) Constant discomfort at his right ankle joint which is mild to severe depending upon activity or weight bearing. The pain is greater at night. He has redness of his ankle. He has instability and weakness. He tries to be careful when walking. He has normal range of motion, however with pain. His pain increases with standing for more than five minutes and he cannot bear weight on it. He is limping due to his ankle pain. X-rays of the cervical spine reveal mild narrowing and anterior spurring at C4 and C6. A large anteroinferior spur is noted at C5. There is no evidence of fracture or dislocation. The odontoid is intact. On oblique views there is no evidence of neural foraminal encroachment. The overall osseous density is satisfactory. X-rays of the right shoulder reveal that the glenohumeral and acromioclavicular joints are well maintained. There is no evidence of fracture or dislocation. There is no evidence of soft tissue calcification. The overall osseous density is satisfactory. X-rays of the lumbosacral spine reveal that the intervertebral disc spaces are well maintained. There is no evidence of fracture or dislocation. There is no evidence of soft tissue calcification. On oblique views there is no evidence of a defect in the pars interarticularis. The overall osseous density is satisfactory. X-rays of the pelvis reveal that the hip joints and sacroiliac joints are well maintained. There is no evidence of fracture or dislocation. There is no evidence of soft tissue calcification. The overall osseous density is satisfactory. X-rays of the right tibia and fibular reveal no evidence of fracture or cortical irregularity. The overall osseous density is satisfactory. X-rays of the right ankle reveal that the tibiotalar and tibiofibular joints are well maintained. There is no evidence of fracture or dislocation. There is no evidence of soft tissue calcification. The overall osseous density is satisfactory. X-rays of the right foot reveal no evidence of fracture or dislocation. Hindfoot, forefoot and mid foot alignment is within normal limits. There is no evidence of soft tissue calcification. Treatment plan: 1) MRI of the right shoulder. 2) Prescribe Naprosyn 375 mg. 3) Physical therapy two times per week for six weeks. 4) Follow-up in three weeks. He is temporarily totally disabled.

A report is reviewed from Dr. Silbart dated [redacted]. This is an orthopaedic surgery progress report. The patient has not had any physical therapy sessions yet, although it has been authorized. Treatment plan: 1) Continue to request authorization for an MRI of the right shoulder. 2) Begin physical therapy. 3) Continue Naprosyn. 4) Follow-up in three weeks. He remains temporarily totally disabled.

A report is reviewed from Dr. Silbart dated [redacted]. This is an orthopaedic surgery progress report. The patient is receiving physical therapy, however only to his lower back.

He has had five sessions and has one more scheduled. Treatment plan: 1) Continue to request authorization for an MRI of the right shoulder. 2) Physical therapy for the right shoulder. 3) Continue Naprosyn. 4) Follow-up in three weeks. He remains temporarily totally disabled.

A report is reviewed from Dr. Silbart dated This is an orthopaedic surgery progress report. Authorization for physical therapy for the right shoulder and an MRI of the right shoulder have been denied. He finished physical therapy for his lower back on Treatment plan: 1) Continue to request authorization for an MRI of the right shoulder and physical therapy for the right shoulder. 2) Continue Naprosyn. 3) Home exercise program. 4) Follow-up in four weeks. He remains temporarily totally disabled.

A report is reviewed from Dr. Silbart dated This is an orthopaedic surgery progress report. The patient's right shoulder pain awakens him nightly. He feels that the shoulder pain is now equal to the lower back pain. Treatment plan: 1) Continue to request authorization for an MRI of the right shoulder and physical therapy for the right shoulder. 2) Continue Naprosyn. 3) Continue home exercise program. 4) Follow-up in six weeks. He remains temporarily totally disabled.

A report is reviewed from Dr. Silbart dated This is an orthopaedic surgery progress report. The patient's chief complaint is now lower back pain. Treatment plan: 1) Continue to try to obtain authorization for an MRI of the right shoulder and physical therapy for the right shoulder. 2) Continue Naprosyn. 3) Continue home exercise program. 4) Follow-up in eight weeks. He remains temporarily totally disabled.

A report is reviewed from Dr. Silbart dated This is an orthopaedic surgery progress report. The patient complains of persistent lower back pain. He is awakened by lower back pain and right shoulder pain. He is also having some GI discomfort from Naprosyn. Treatment plan: 1) Continue to request authorization for an MRI of the right shoulder and physical therapy for the right shoulder. 2) Continue home exercise program. 3) Request a copy of Dr. Paul's AME report. 4) Follow-up in for weeks. He remains temporarily totally disabled.

A report is reviewed from Dr. Gerald M. Paul dated This is an agreed medical evaluation. The patient is seen for the injury he sustained on He picked up a roll of fabric and put in on his right shoulder. As he turned and took a step his right foot tripped on the edge of a rack. He subsequently twisted his foot and fell forward, landing on the cement floor, and the roll struck him on the right side of his body from his neck to his lower back. He felt a crack in his lower back when he was struck by the roll of fabric. He also had pain and instability of his right foot, as well as pain in his neck and right shoulder. He was laid off on

After being laid off he retained an attorney. His neck, right shoulder and right foot have not been treated and remain symptomatic. He sustained an industrial injury in . while working for as a spreader. He was walking along a hall when a forklift driver struck him and he injured his back. He reported the injury and was treated with physical therapy and medications. He was off work for one to two years. He underwent an MRI and injections. He received a \$22,000.00 award, however does indicate that he became asymptomatic and returned two years later to identical duties as a spreader without any particular difficulty until the subject injury. He sustained an industrial injury in when he slipped and fell, sustaining a hernia. He was treated with surgery and fully recovered. The patient complains of: 1) Lower back pain which is present every day and varies in intensity from sharp to aching. He has radiating pain down the back of his right leg towards the plantar aspect of his foot, as well as his anterior thigh. He has painful range of motion of his back and pain with twisting. 2) Neck pain. He has pain with right sided movements and at times there is limited range of motion. He has pain radiating to his right upper extremity circumferentially with numbness and tingling. 3) Pain in the right upper trapezius and superior aspect of the right shoulder present most of the time. The pain varies in intensity, off and on throughout the day. There is limited and painful range of motion of the right shoulder. He has painful popping of his shoulder. 4) Diffuse right foot pain noted quite often, aggravated by prolonged standing and walking. Diagnosis: Deferred(sic). Treatment plan: There are no records currently available for review. Once these become available a supplemental report will be provided. It does not seem that there is an actual ankle injury. He does have some radiating pain down both legs and pain about his shoulder, neck and low back. Insofar as his right foot basically this is more his leg than his foot per se. He does have some degenerative changes in his neck noted radiographically. Once there is an opportunity to review the medical records a thorough supplemental report will be provided.

A report is reviewed from Dr. Silbart dated . This is an orthopaedic surgery progress report. The patient's low back and right shoulder pain have increased since he had to discontinue the anti-inflammatory medication due to GI irritation. He is taking plain Tylenol without any effect. Treatment plan: 1) Request a copy of Dr. Paul's report. 2) Encourage to continue home exercise program. 3) Follow-up in four weeks. He remains temporarily totally disabled.

A report is reviewed from Dr. Silbart dated . This is an orthopaedic surgery progress report. The patient continues to remain off Naprosyn due to GI intolerance. His right shoulder and low back symptoms persist. Treatment plan: 1) Continue to await Dr. Paul's AME report. 2) Encourage to continue home exercise program. 3) Follow-up in four weeks. He remains temporarily totally disabled.

A report is reviewed from Dr. Silbart dated . This is an orthopaedic surgery progress report. The patient has had no change in his lower back or right shoulder symptoms.

The low back pain is currently equal to the right shoulder pain. Treatment plan: 1) Request the orthopaedic AME report. 2) Encourage to continue home exercises. 3) Follow-up in four weeks. He remains temporarily totally disabled.

A report is reviewed from Dr. Paul dated . This is an agreed medical evaluator's supplemental report for a review of medical records and is 13 pages in length.

A report is reviewed from Dr. Silbart dated . This is an orthopaedic surgery progress report. The patient's low back and right shoulder symptoms persist. Treatment plan: 1) Continue to await the orthopaedic AME report. 2) Encourage to continue a home exercise program. 3) Follow-up in four weeks. He remains temporarily totally disabled.

A report is reviewed from Dr. Silbart dated . This is a comprehensive orthopaedic medical-legal report by primary treating physician/final report with permanent and stationary rating. The patient's complaints persist unchanged. His condition is considered permanent and stationary and has reached maximal medical improvement. He has a 16% total whole person impairment. He is not considered capable of resuming his usual and customary work duties. Future medical treatment: Anticipated future treatment includes oral anti-inflammatory and non-narcotic analgesic medication, as well as orthopaedic follow-up on an intermittent and as needed basis for flares of symptomatology. His lumbar disability is apportioned 50% to the specific injury with the remainder apportioned equally between the and specific injuries.

A report is reviewed from Nurse Gail Gaddis dated . This is an emergency department report. On the patient was moving a bolt of fabric from over his head and ended up doing the splits. He developed right groin pain. In he had right inguinal hernia repair. He has not had any medical attention. He is now complaining of pain in his right thigh and the right inguinal area. He also complains of pain in his right shoulder which is aching and increases with movement. Treatment plan: 1) Laboratory studies. 2) Ultrasound of the scrotum. 3) X-rays of the right shoulder. 4) Toradol. 5) Follow-up with his company's workers' compensation M.D. and get his medications and release from them. 6) Prescribe Feldene 20 mg, Flexeril 5 mg and Norco 5/325 mg.

A report is reviewed from Physician Assistant Evadna T. Nesbit in conjunction with Dr. Gaby Abdo of U.S. Healthworks Medical Group dated . This is a doctor's first report of occupational injury or illness. On the patient was bringing down rolls of material when he slipped. He complains of 9/10 pain in his: 1) Right shoulder. His pain is sharp, moderately severe, intermittent and exacerbated by using the machine. He has pain with shoulder range of motion. 2) Right abdomen/groin pain which is sharp and moderately severe, exacerbated by walking. Diagnoses: 1) Sprain/strain, shoulder, right. 2) Pain in joint, shoulder, right.

Treatment plan: 1) Prescribe Nabumetone 750 mg, Acetaminophen 500 mg, polar frost and Omeprazole 20 mg. 2) Dispense hot/cold therapy pack, custom touch heat therapy pad and hernia support belt. 3) Physical therapy three times per week for two weeks. 4) General surgery evaluation. He is to return to modified duties with restrictions of limited stooping and bending and limited lifting, pulling and pushing up to 10 pounds.

A report is reviewed dated _____ This is a description of employee's job duties (form DWC-AD 10133.33) for the position of fabric cutter and is two pages in length.

A report is reviewed from Physician Assistant Beverly J. Lassiter-Brown in conjunction with Dr. Abdo dated _____ This is a primary treating physician's progress report. The patient's condition has not improved significantly. His employer is not following the restrictions. He complains of: 1) Right groin pain which is dull, moderately severe and intermittent. 2) Dull, moderately severe intermittent right shoulder pain with pain on range of motion. Diagnosis: Sprain/strain, shoulder, right. Treatment plan: 1) Physical therapy. 2) General surgery evaluation for persistent right groin pain. He is to continue modified duties with restrictions of limited overhead work; limited stooping and bending; limited lifting, pushing and pulling up to 10 pounds; and he must wear his groin support.

A report is reviewed from Dr. Abdo dated _____ This is a primary treating physician's progress report. The patient's condition has not improved significantly. He feels worse. He complains of sharp right groin pain which is moderately severe and extremely severe and intermittent. Diagnoses: 1) Unilateral inguinal hernia, right. 2) Sprain/strain, shoulder, right. 3) Pain in joint, shoulder, right. Treatment plan: 1) He is sent to the emergency room due to 10/10 right inguinal pain to rule out incarceration. 2) Follow-up on _____. He is temporarily totally disabled for the rest of his shift. He is to return to modified duties on _____ with the previously outlined restrictions.

A report is reviewed from Dr. Wendy Ruggeri dated _____. This is an emergency department report. Impression: Right femoral hernia. Treatment plan: Pain control.

A report is reviewed from Dr. Abdo dated _____ This is a primary treating physician's progress report. The patient's condition has not improved significantly. He complains of sharp, moderately severe, intermittent right shoulder pain with decreased motion and pain on motion. Diagnoses: 1) Sprain/strain, shoulder, right. 2) Pain in joint, shoulder, right. Treatment plan: 1) MRI of the right shoulder. 2) Orthopaedic consultation. 3) Follow-up with hernia network for groin pain. 4) Follow-up on _____. He is to continue modified duties with the previously outlined restrictions.

A report is reviewed from Dr. K. Sim dated . This is a handwritten surgical evaluation report and is two pages in length. Diagnostic impression: Recurrent right inguinal hernia. Treatment plan: Right inguinal hernia repair.

A report is reviewed from Dr. Gabriel Rubanenko dated This is a doctor's first report of occupational injury or illness. The patient is seen for the injury he sustained on . He was pulling rolls of fabric from a rack when he slipped, causing him to perform an awkward split with the onset of severe pain in his right inguinal area. He continued working despite his pain and felt the onset of pain in his back radiating to his right lower extremity. The patient complains of: 1) Headaches. 2) Back pain. 3) Abdominal/GI problems. 4) A right inguinal hernia. 5) Psychiatric complaints. Diagnoses: 1) Head pain. 2) Thoracic musculoligamentous sprain/strain. 3) Lumbosacral musculoligamentous sprain/strain with radiculitis. 4) Rule out lumbosacral spine discogenic disease. 5) Rule out right inguinal hernia. 6) Right lower abdominal pain. 7) Depression, situational. Treatment plan: 1) Prescribe TGHOT, Cyclobenzaprine 7.5 mg and Motrin 600 mg. 2) Prescribe lumbosacral brace, interferential unit and hot and cold unit. 3) Urine toxicology for medication monitoring. 4) MRI of the lumbosacral spine. 5) EMG and NCVS of the bilateral lower extremities. 6) Consultation with an internist. 7) He is a candidate for a right inguinal hernia repair and is advised to follow-up with his scheduled surgical appointment. 8) Chiropractic evaluation and treatment two times per week for six weeks. He is temporarily totally disabled.

A report is reviewed from Dr. Stanton Kremsky of Vital Imaging Medical Group dated . This is an MRI of the lumbar spine with flexion and extension views. Impression: 1) L3-4 left paracentral disc protrusion that produces left neuroforaminal narrowing. Left posterolateral annular tear/fissure. Disc measurements: Neutral 2.5 mm, flexion 2.5 mm, extension 2.5 mm. 2) Schmorl's nodes at L1-4. 3) Straightening of the lumbar lordosis which may be due to myospasm. 4) No other significant findings are noted.

A report is reviewed from Dr. Sim of Advanced Diagnostic & Surgical Center dated , This is an operative report. Pre- and post-operative diagnosis: Recurrent right inguinal hernia. Operation performed: Repair of right inguinal hernia with mesh implant.

A report is reviewed from Chiropractor Rene Nevarez for Dr. Rubanenko dated . This is a primary treating physician's progress report with request for authorization. The patient complains of: 1) Increased headaches. 2) Increased mid and upper back pain. 3) Increased lower back pain radiating in a pattern of the bilateral L4-5 dermatomes. 4) Increased neck pain. He had hernia surgery on / and has not been cleared by the surgeon for chiropractic therapy.

Diagnostic impression: 1) Head pain. 2) Thoracic spine musculoligamentous sprain/strain. 3) Lumbar spine musculoligamentous sprain/strain with radiculitis, rule out lumbar spine discogenic disease. 4) Status post herniorrhaphy (inguinal) dated . 5) Rule out right inguinal hernia. 6) Right lower abdominal. 7) Depression, situational. Treatment plan: 1) Hold physical therapy until cleared by the hernia surgeon. 2) Urine toxicology testing. 3) Follow-up on . He remains temporarily totally disabled.

A report is reviewed from Dr. Sim dated . This is a handwritten status report. The patient's condition is permanent and stationary and has reached maximal medical improvement. He is to return to work without restrictions.

A report is reviewed from Dr. Rubanenko dated . This is a primary treating physician's progress report with request for authorization. (Only page one of this report is submitted for review).

A report is reviewed from Dr. Rubanenko dated . This is a primary treating physician's progress report with request for authorization. The patient complains of: 1) Increased headaches. 2) Decreased mid and upper back pain. 3) Decreased lower back pain. 4) Decreased right abdominal pain. Physical therapy helps decrease his pain and tenderness. Diagnostic impression: 1) Head pain. 2) Thoracic spine musculoligamentous sprain/strain. 3) Lumbar spine musculoligamentous sprain/strain with radiculitis, lumbar spine disc protrusion, per MRI dated . 4) Status post herniorrhaphy (inguinal) dated . 5) Right lower abdominal pain. 6) Depression, situational. Treatment plan: 1) Continue physical therapy two times per week for six weeks. 2) Prescribe Flurbi cream and Gabacyclotram cream. 3) Prescribe motorized hot and cold unit. 4) Pain management consultation for the lumbar spine. 5) One time psychiatric evaluation. 6) Urine toxicology testing for medication monitoring. 7) Transportation to and from all medical appointments. 8) Follow-up on . He remains temporarily totally disabled.

A deposition transcript of] dated is reviewed which is 61 pages in length.

A report is reviewed from Dr. Rubanenko dated . This is a handwritten primary treating physician's progress report. The patient complains of: 1) Headaches. 2) Mid and upper back pain. 3) Lower back pain. Diagnoses: 1) Head pain. 2) Thoracic spine musculoligamentous sprain/strain, myofascial pain. 3) Lumbar spine sprain/strain with radiculitis. 4) Lumbar spine disc protrusion per MRI dated . 5) Status post herniorrhaphy, inguinal, . 6) Depression, situational. 7) Right lower abdominal pain.

Treatment plan: 1) Continue physical therapy two times per week for six weeks. 2) Prescribe Tramadol, Elavil and topical medications. 3) Lumbar spine extracorporeal shockwave therapy. 4) Follow-up on He remains temporarily totally disabled.

A report is reviewed from Dr. Yousif which is undated. This is a report. (Only pages three and four of this report are submitted for review). The patient continues to be symptomatic with persistent cervical spine and left leg tenderness. However, he is having a good response to the treatment regimen. Present diagnoses: 1) Cerebral concussion/posttraumatic cephalgia. 2) Left earache/infection per patient. 3) Cervical spine strain/myofascialgia. 4) Left leg contusion/sprain. 5) Status post minor surgery of the left leg, extent unknown. Treatment plan: 1) Continue physiotherapeutic treatments for an additional two to three weeks. 2) Follow-up in three weeks.

A handwritten acupuncture treating physician's progress report from Acupuncturist George Lu is reviewed.

A group of handwritten physical therapy reports and notes from Physical Therapist Ina Hocutt are reviewed.

A handwritten chiropractic therapy report from Chiropractor Carissa Hang is reviewed.

A group of urine drug testing reports from Medi-Lab Corporation are reviewed.

A group of records from WCAB-Los Angeles are reviewed.

A group of records from Law Offices of Elliott Wachtel & Associates are reviewed.

A group of records from McNamara and Drass are reviewed.

A group of records from Chernow and Lieb, Attorneys at Law are reviewed.

ASSESSMENT:

This is a gentleman who worked as a fabric cutter. He states he was injured in . He and two other co-workers were apparently pulling a large fabric roll which weighed 50 pounds. Apparently, the applicant was pulling the roll with tremendous force. He was thrown backwards. He fell in a split position. Apparently, he developed a right hernia. He also injured his neck and back and, to some extent, his shoulder.

He was seen at U. S. Health Works. He later saw Dr. Rubanenko. He's had conservative treatment though he did have a hernia repair.

Currently, he seems to be improved. He still has some mild weakness about the right shoulder and has some back pain but, otherwise, seems to be doing better. He is permanent and stationary for rating purposes having reached maximum medical improvement.

DIAGNOSIS:

1. Rotator cuff injury, right shoulder.
2. Thoracic strain.
3. Lumbar strain.

SUBJECTIVE FACTORS OF DISABILITY:

With respect to the back, applicant has complaints of pain rated as intermittent and slight.

With respect to the right shoulder, applicant has complaints of pain rated as intermittent and slight.

OBJECTIVE FACTORS OF DISABILITY:

The patient does have some weakness about the right shoulder. He has limitation of motion of the lumbar spine and thoracic spine.

WORK RESTRICTIONS:

Overall, applicant is limited to no very heavy lifting.

IMPAIRMENT RATING:

With respect to the thoracic and lumbar spine, applicant is DRE Category II with a 6% impairment whole person at each level. Overall impairment to the spine is 12%.

With respect to the right shoulder, applicant is best rated per Table 16-35. He has a 5% upper extremity impairment due to weakness in flexion and 3% impairment due to weakness in abduction. This is an 8% upper extremity impairment which converts to a 5% impairment whole person.

Combining all impairments, applicant has 16% impairment whole person.

FUTURE MEDICAL CARE:

The applicant should have access to orthopedic evaluation on an as needed basis. He can take over-the-counter medication as needed. I don't see the need for surgery in this patient. Surgery is not likely to make this patient any better. I would avoid any surgical approach.

VOCATIONAL REHABILITATION:

Vocational rehabilitation is not indicated.

APPORTIONMENT:

Applicant has had a prior back injury. He had prior back injury in . In my opinion, 25% of this patient's condition is due to pre-existing condition with respect to the low back.

He also injured his right shoulder in . He sustained injury to the cervical spine, right shoulder and low back at that time. He was treated by Dr. Silbart. He made a "full recovery". Clearly, he was somewhat more fragile which is a factor of patient's current condition and 20% of the right shoulder whole person impairment is related to the injury.

CAUSATION:

Applicant's injury is industrial in causation.

DISCLOSURE:


During this evaluation, the patient was interviewed by a historian,] , for an initial history. The entire medical history was reviewed in detail by myself with the patient. The medical records were reviewed and summarized by] and were subsequently reviewed in their entirety by the undersigned. was used for interpretive services (Certification No.). The physical examination and dictation of this report with all opinions rendered herein are strictly by the undersigned physician. X-rays, if any, were obtained by] , CRT, ARRT. The above evaluation was carried out at 2080 Century Park East, Suite 305, Los Angeles, California. Transcription was provided by .

I declare under penalty of perjury that the information contained in this report and its attachments, if any, is true and correct to the best of my knowledge and belief, except as to information I have indicated I have received from others. As to that information, I declare under penalty of perjury that the information accurately describes the information provided to me and, except as noted herein, that I believe it to be true. I have not violated Labor Code Section 139.3 and the contents of the report and bill are true and correct to the best of my knowledge. This statement is made under penalty of perjury.

Thank you very much for your attention to this matter. If there are any questions not answered in this report, I am available for cross-examination via deposition at the mutual convenience of all parties.

This report and declaration were signed in the County of Los Angeles on .

Sincerely yours,




ROGER SOHN, M.D.
Diplomate, American Board
of Orthopaedic Surgery

RS:sm

Copy to:

September 22, 2015

TO: Each Member
Board of Retirement

FROM: Ricki Contreras, Manager 
Disability Retirement Services Division

FOR: October 7, 2015 Board of Retirement Meeting

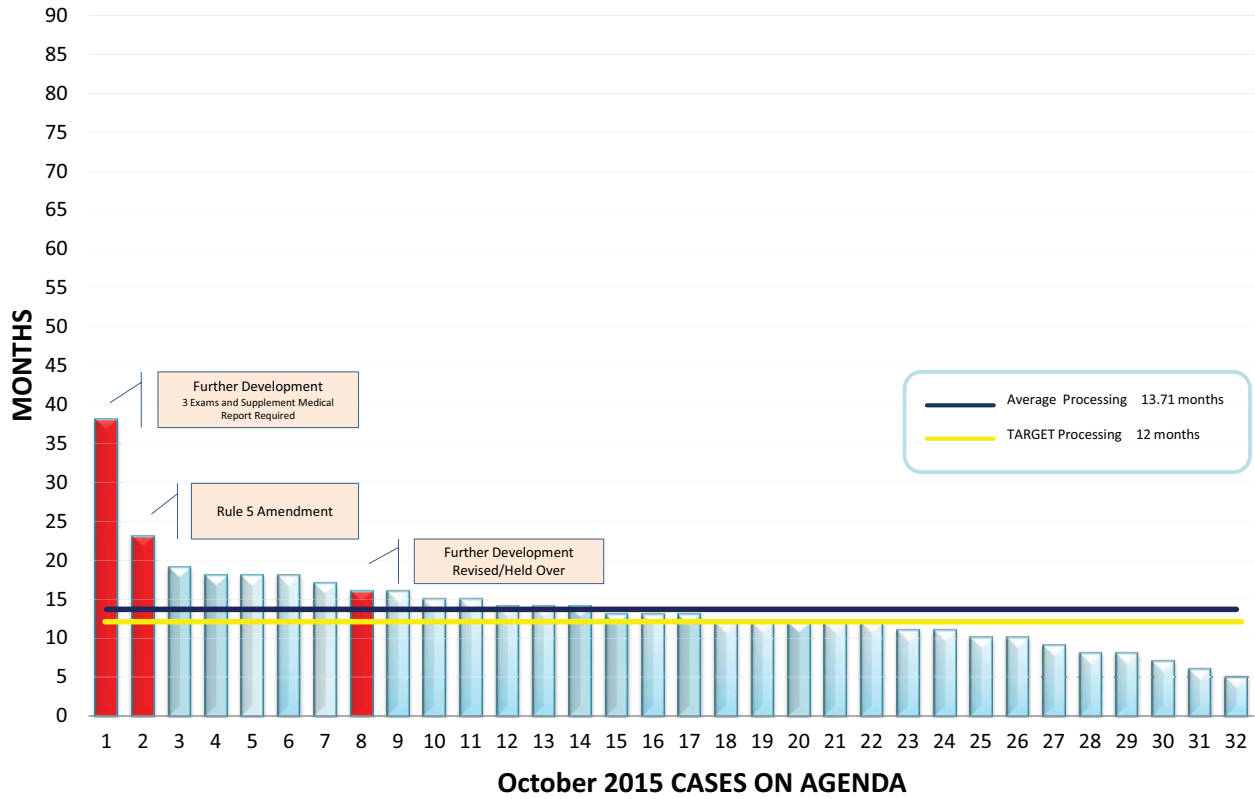
SUBJECT: **Application Processing Time Snapshot Reports**

At the February 4, 2015 meeting, the Disability Procedures & Services Committee voted to add two additional snapshot reports addressing application processing times and pending applications by elapsed time since application date. These reports will now be provided on a monthly basis along with the current snapshot that provides a look at application processing time before and after procedural changes were made to the disability application process. The Board adopted proposed changes on July 12, 2012. The chart breaks down the periods for cases processed under the old procedures vs. the new procedures with the associated monthly processing timeframes.

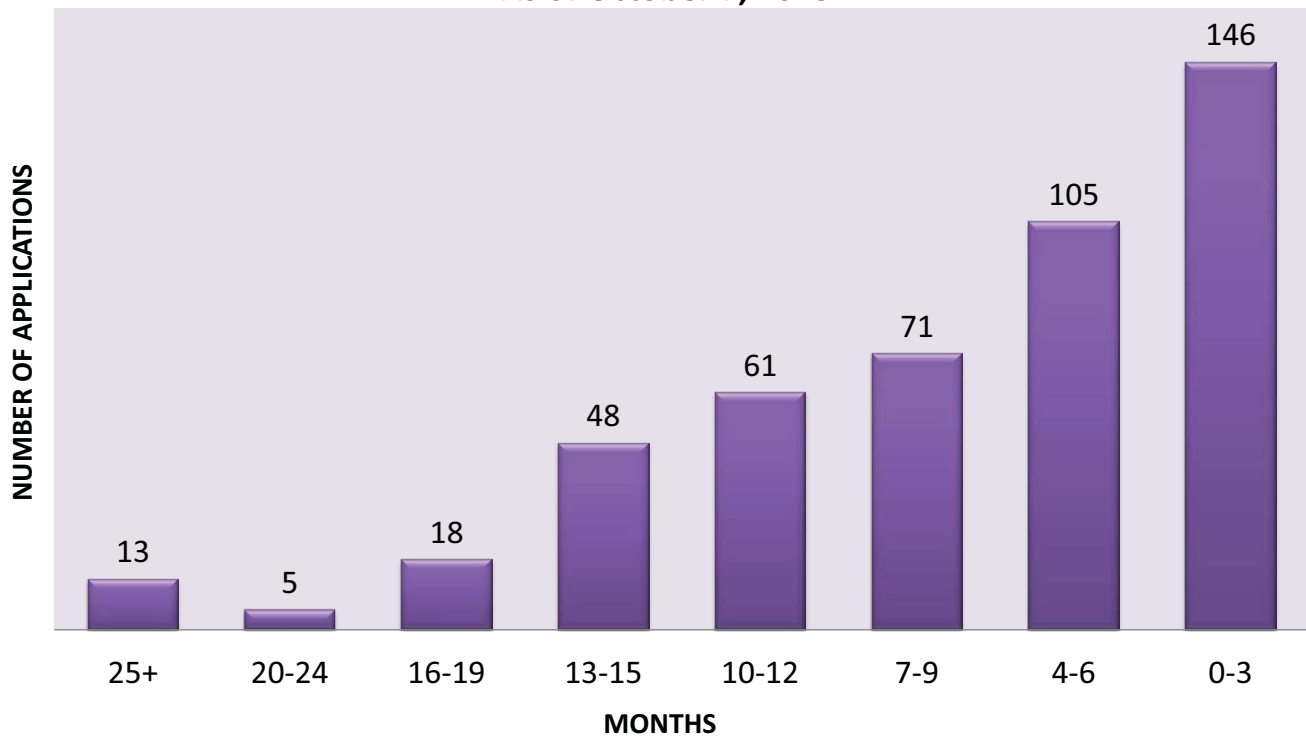
The following chart shows the total time from receipt of the application to the first Board action for the month in question.

Consent & Non-Consent Calendar			
Received <u>Prior</u> to July 12, 2012		Received <u>After</u> July 12, 2012	
Number of Applications	Processing Time (in Months)	Number of Applications	Processing Time (in Months)
0	0	30	12.53
Revised/Held Over Calendar (page 7)			
Rule 5 Amendment (1 case, total processing time since reopened)		23.0	
Held Over/Revised; Returned for Further Development (2 Cases, total average processing time since receipt of application)		Case 1 38.0	Case 2 16.0
<i>Average Processing Time for Revised/Held Over Calendar</i>		25.67	

ACTUAL vs. AVERAGE PROCESSING TIME



TIME ELAPSED FOR PENDING APPLICATIONS As of October 7, 2015





Documents not attached are exempt from disclosure under the California Public Records Act and other legal authority.

**For further information, contact:
LACERA
Attention: Public Records Act Requests
300 N. Lake Ave., Suite 620
Pasadena, CA 91101**



Documents not attached are exempt from disclosure under the California Public Records Act and other legal authority.

**For further information, contact:
LACERA
Attention: Public Records Act Requests
300 N. Lake Ave., Suite 620
Pasadena, CA 91101**



Documents not attached are exempt from disclosure under the California Public Records Act and other legal authority.

**For further information, contact:
LACERA
Attention: Public Records Act Requests
300 N. Lake Ave., Suite 620
Pasadena, CA 91101**



Documents not attached are exempt from disclosure under the California Public Records Act and other legal authority.

**For further information, contact:
LACERA
Attention: Public Records Act Requests
300 N. Lake Ave., Suite 620
Pasadena, CA 91101**



Documents not attached are exempt from disclosure under the California Public Records Act and other legal authority.

**For further information, contact:
LACERA
Attention: Public Records Act Requests
300 N. Lake Ave., Suite 620
Pasadena, CA 91101**



Documents not attached are exempt from disclosure under the California Public Records Act and other legal authority.

**For further information, contact:
LACERA
Attention: Public Records Act Requests
300 N. Lake Ave., Suite 620
Pasadena, CA 91101**