

AGENDA

A REGULAR MEETING OF THE BOARD OF RETIREMENT

LOS ANGELES COUNTY EMPLOYEES RETIREMENT ASSOCIATION

300 N. LAKE AVENUE, SUITE 810, PASADENA, CA

9:00 A.M., WEDNESDAY, FEBRUARY 3, 2016

- I. CALL TO ORDER
- II. PLEDGE OF ALLEGIANCE
- III. APPROVAL OF MINUTES
 - A. Approval of the Minutes of the Regular Meeting of January 6, 2016
- IV. REPORT ON CLOSED SESSION ITEMS
- V. PUBLIC COMMENT
- VI. CONSENT AGENDA
 - A. Ratification of Service Retirement and Survivor Benefit Application Approvals.
 - B. Requests for an administrative hearing before a referee.
(Memo dated January 20, 2016)
 - C. Recommendation as submitted by Ricki Contreras, Division Manager, Disability Retirement Services: That the Board dismiss with prejudice the appeal for a service-connected disability retirement in the case of **Richard M. Fontenot**. (Memo dated January 13, 2016)

VI. CONSENT AGENDA (Continued)

- D. Recommendation as submitted by Ricki Contreras, Division Manager, Disability Retirement Services: That the Board dismiss with prejudice the appeal for a service-connected disability retirement in the case of **Lamberto R. Villarroel**. (Memo dated January 20, 2016)
- E. Recommendation as submitted by Vivian H. Gray, Chair, Disability Procedures & Services Committee: That the Board approve Jason J. Chiu, M.D. – Board Certified Orthopedist to the LACERA Panel of Physicians for the purpose of examining disability retirement applicants. (Memo dated January 13, 2016)
- F. For information only as submitted by Ricki Contreras, Division Manager, Disability Retirement Services regarding the Application Processing Time Snapshot Reports. (Memo dated January 20, 2016)

VII. GOOD OF THE ORDER

(For information purposes only)

VIII. DISABILITY RETIREMENT APPLICATIONS ON CONSENT CALENDAR

IX. DISABILITY RETIREMENT CASES TO BE HELD IN CLOSED SESSION

- A. Applications for Disability
- B. Referee Reports
- C. Staff Recommendations

- 1. Recommendation as submitted by Vincent A. Lim, Chief Counsel, Disability Litigation: That the Board find that **Joseph Gagliardi** delayed the filing of his application for disability retirement because he was unable to ascertain the permanency of his incapacity and that his application be deemed filed on the day after the last day of regular compensation in accordance with Government Code Section 31724. (Letter dated January 12, 2016)

IX. DISABILITY RETIREMENT CASES TO BE HELD IN CLOSED SESSION

C. Staff Recommendations (Continued)

2. Recommendation as submitted by Ricki Contreras, Division Manager, Disability Retirement Services: That the Board adopt the Proposed Findings of Fact and Conclusions of Law granting **Dennis E. Cusino** for an earlier effective date pursuant to Government Code Section 31724. (Memo dated January 21, 2016)
3. For Information Only as submitted by Ricki Contreras, Division Manager, Disability Retirement Services regarding the 4th Quarter Report of Paid Invoices for October 1, 2015 – December 31, 2015. (Memo dated January 22, 2016)

X. ADJOURNMENT

Documents subject to public disclosure that relate to an agenda item for an open session of the Board of Retirement that are distributed to members of the Board of Retirement less than 72 hours prior to the meeting will be available for public inspection at the time they are distributed to a majority of the Board of Retirement Members at LACERA's offices at 300 N. Lake Avenue, Suite 820, Pasadena, CA 91101, during normal business hours of 9:00 a.m. to 5:00 p.m. Monday through Friday.

Persons requiring an alternative format of this agenda pursuant to Section 202 of the Americans with Disabilities Act of 1990 may request one by calling Cynthia Guider at (626) 564-6000, from 8:30 a.m. to 5:00 p.m. Monday through Friday, but no later than 48 hours prior to the time the meeting is to commence. Assistive Listening Devices are available upon request. American Sign Language (ASL) Interpreters are available with at least three (3) business days notice before the meeting date.

MINUTES OF THE REGULAR MEETING OF THE BOARD OF RETIREMENT

LOS ANGELES COUNTY EMPLOYEES RETIREMENT ASSOCIATION

300 N. LAKE AVENUE, SUITE 810, PASADENA, CA

9:00 A.M., WEDNESDAY, JANUARY 6, 2016

PRESENT:

Shawn R. Kehoe, Chair

Alan Bernstein, Vice Chair

William de la Garza, Secretary

Anthony Bravo

Yves Chery

Vivian H. Gray

Joseph Kelly

David L. Muir (Alternate Retired)

William Pryor (Alternate Member) (Mr. Pryor left at 9:40 a.m.)

Ronald A. Okum

Les Robbins

STAFF ADVISORS AND PARTICIPANTS

Gregg Rademacher, Chief Executive Officer

JJ Popowich, Assistant Executive Officer

Steven Rice, Chief Counsel

Dr. Vito Campese, Medical Advisor

STAFF ADVISORS AND PARTICIPANTS (Continued)

Ricki Contreras, Division Manager
Disability Retirement Services

Tamara Caldwell, Specialist Supervisor
Disability Retirement Services

Francis J. Boyd, Senior Staff Counsel
Legal Division

Allison E. Barrett, Senior Staff Counsel
Disability Litigation

Thomas J. Wicke, Attorney at Law
Lewis, Marenstein, Wicke & Sherwin, LLP

Michael Treger, Attorney at Law

I. CALL TO ORDER

The meeting was called to order by Chair Kehoe at 9:00 a.m., in the Board Room of Gateway Plaza.

II. ELECTION OF OFFICERS

(Election of Chair, Vice Chair, Secretary, and Audit Committee Member)

The election of officers was conducted by Secretary de la Garza:

A) Chair of the Board

Mr. Kehoe was nominated to the position of Chair of the Board of Retirement by Mr. de la Garza.

Hearing no other nominations the nominations were closed on a motion by Mr. de la Garza, seconded by Mr. Okum.

II. ELECTION OF OFFICERS (Continued)

Secretary de la Garza announced that Mr. Kehoe was elected to the position of Chair of the Board of Retirement.

B) Vice Chair of the Board

Ms. Gray was nominated to the position of Vice Chair of the Board of Retirement by Mr. Bernstein.

Hearing no other nominations the nominations were closed on a motion by Mr. Bernstein, seconded by Mr. Chery.

Secretary de la Garza announced that Ms. Gray was elected to the position of Vice Chair of the Board of Retirement.

C) Secretary of the Board

Mr. de la Garza was nominated to the position of Secretary of the Board of Retirement by Ms. Gray.

Hearing no other nominations the nominations were closed on a motion by Ms. Gray, seconded by Mr. Bernstein.

Secretary de la Garza announced that he was elected to the position of Secretary of the Board of Retirement.

D) Audit Committee Member

Mr. Kelly was nominated to the position of Audit Committee Member by Chair Kehoe.

II. ELECTION OF OFFICERS (Continued)

Hearing no other nominations the nominations were closed on a motion by Chair Kehoe, seconded by Mr. Bernstein.

Secretary de la Garza announced that Mr. Kelly was elected to the position of Audit Committee Member.

III. PLEDGE OF ALLEGIANCE

Mr. Chery led the Board Members and staff in reciting the Pledge of Allegiance.

IV. APPROVAL OF MINUTES

A. Approval of the Minutes of the Regular Meeting of December 2, 2015

Mr. Chery made a motion, Mr. Okum seconded, to approve the minutes of the regular meeting of December 2, 2015. The motion passed unanimously.

V. REPORT ON CLOSED SESSION ITEMS

No items were reported.

VI. PUBLIC COMMENT

There were no requests from the public to speak.

VII. CONSENT AGENDA

Mr. de la Garza made a motion, Mr. Kelly seconded, to approve the following agenda items. The motion passed unanimously.

VII. CONSENT AGENDA (Continued)

- A. Ratification of Service Retirement and Survivor Benefit Application Approvals.
- B. Requests for an administrative hearing before a referee.
(Memo dated December 9, 2015)
- C. For information only as submitted by Ricki Contreras, Division Manager, Disability Retirement Services regarding the Application Processing Time Snapshot Reports. (Memo dated December 18, 2015)

VIII. GOOD OF THE ORDER

(For information purposes only)

Mr. Rademacher recognized Virginia Carrillo, Mamie Kwan, and Juan Almaguer on their recent retirement and thanked them for their careers serving the LACERA membership.

IX. DISABILITY RETIREMENT APPLICATIONS ON CONSENT CALENDAR

Safety Law Enforcement
Service-Connected Disability Applications

On a motion by Mr. Kelly, seconded by Mr. Chery, the Board of Retirement approved a service-connected disability retirement for the following named employees who were found to be disabled for the performance of their duties and have met the burden of proof:

<u>APPLICATION NO.</u>	<u>NAME</u>
421C	ROBERT M. RIFKIN
422C	JANICE E. MUNSON

IX. DISABILITY RETIREMENT APPLICATIONS ON CONSENT CALENDAR

Safety Law Enforcement (Continued)
Service-Connected Disability Applications

<u>APPLICATION NO.</u>	<u>NAME</u>
423C	TIMOTHY C. MILEY
424C*	ERNEST T. DIAZ
425C	DAVID S. KIM
426C**	RICHARD W. BARRETT
427C**	DONALD T. HERNANDEZ
428C***	DEBORAH R. HAYES
429C*	WARREN E. FAIRBANKS
430C**	PHILLIP BUSCH
431C	VICTOR M. RONQUILO
432C	MARTIN V. DEIRO
433C	MICHAEL A. PROCTOR
434C	ANDREW M. AVELINO

* Granted SCD – Retroactive

** Granted SCD – Employer Cannot Accommodate

*** Applicant Present

IX. DISABILITY RETIREMENT APPLICATIONS ON CONSENT CALENDAR
(Continued)

Safety-Fire, Lifeguard
Service-Connected Disability Applications

On a motion by Mr. Okum, seconded by Mr. Pryor, the Board of Retirement approved a service-connected disability retirement for the following named employees who were found to be disabled for the performance of their duties and have met the burden of proof:

<u>APPLICATION NO.</u>	<u>NAME</u>
1725A*	TIMOTHY A. WILLIAMS
1726A	MICHAEL R. JASPERSON
1727A	MICHAEL R. SHANNON
1728A	STEVEN E. GARNER

General Members
Service-Connected Disability Applications

On a motion by Mr. Chery, seconded by Mr. Bernstein, the Board of Retirement approved a service-connected disability retirement for the following named employees who were found to be disabled for the performance of their duties and have met the burden of proof:

<u>APPLICATION NO.</u>	<u>NAME</u>
2580B	VERNARDINE MARTINEZ

* Granted SCD – Retroactive

IX. DISABILITY RETIREMENT APPLICATIONS ON CONSENT CALENDAR

General Members (Continued)
Service-Connected Disability Applications

<u>APPLICATION NO.</u>	<u>NAME</u>
2581B	RITA M. DOWELL
2582B*	ANN C. RUTAR
2583B**	LESTER R. MIGUEL
2584B	LINDA S. ESTRADA (KRZYCKI)
2585B	SHEILA J. CROSBY
2586B*	HELEN E. ROEBUCK
2587B***/**	CLINTON E. HOWARD, JR.
2588B***	LETICIA CARLSON
2589B***	CASSANDRA F. YOUNGBLOOD
2590B**/**	NEAL H. OSHEROW

* Granted SCD – Retroactive

** Granted SCD – Survivor Benefit

*** Granted SCD – Employer Cannot Accommodate

**** Applicant Present

IX. DISABILITY RETIREMENT APPLICATIONS ON CONSENT CALENDAR

General Members

Non-Service Connected Disability Applications

On a motion by Mr. de la Garza, seconded by Mr. Bernstein, the Board of Retirement approved a non-service connected disability retirement for the following named employees who were found to be disabled for the performance of their duties and have met the burden of proof:

<u>APPLICATION NO.</u>	<u>NAME</u>
4337*	ARIANNE B. PACHTER
4338*	IMELDA LIEZ N. DIAZ

X. DISABILITY RETIREMENT CASES TO BE HELD IN CLOSED SESSION

A. Applications for Disability

<u>APPLICATION NO. & NAME</u>	<u>BOARD ACTION</u>
6863A – SCOTT R. FRIEDMAN	Mr. Chery made a motion, Ms. Gray seconded, to deny a service connected disability retirement and find the applicant not permanently incapacitated. The motion passed unanimously.
6864A – MARYLOU D. VELASQUEZ	Mr. Okum made a motion, Ms. Gray seconded, to grant a non-service connected disability retirement pursuant to Government Code Section 31720. The motion passed unanimously.

* Granted NSCD - Retroactive

X. DISABILITY RETIREMENT CASES TO BE HELD IN CLOSED SESSION

A. Applications for Disability (Continued)

APPLICATION NO. & NAME

BOARD ACTION

6865A – JUAN G. BECERRA

Mr. Muir made a motion, Mr. de la Garza seconded, to grant a non-service connected disability retirement pursuant to Government Code Section 31720. The motion passed unanimously.

6866A – SELINA C. SAFARI

Chair Kehoe made a motion, Ms. Gray seconded, to deny a service connected disability retirement without prejudice.

The makers of the motion amended their motion to refer back to staff for additional information. The motion passed unanimously.

6742A – RANEE A. WERNER

Chair Kehoe made a motion, Mr. Chery seconded, to grant a service connected disability retirement. The motion passed (roll call) with Messrs. Bravo, Robbins, Chery, Chair Kehoe, and Ms. Gray voting yes; and Messrs. Kelly, Bernstein, Okum, and de la Garza voting no.

6841A – CYRIL H. LEGENDRE

Mr. de la Garza made a motion, Chair Kehoe seconded, to deny a service connected disability retirement since the employer can accommodate. The motion passed unanimously.

X. DISABILITY RETIREMENT CASES TO BE HELD IN CLOSED SESSION
(Continued)

B. Referee Reports

APPLICATION NO. & NAME

BOARD ACTION

Anna M. Enriquez – Thomas J. Wicke for applicant
Steven Tallant for respondent

Chair Kehoe made a motion, Ms. Gray seconded, to grant a service connected disability retirement. The motion passed unanimously.

Gilbert D. Anderson – Thomas J. Wicke for applicant
Eugenia W. Der for respondent

Mr. Bernstein made a motion, Chair Kehoe seconded, to grant a service connected disability retirement. The motion passed unanimously.

Rafael Ortiz – Michael Treger for applicant
Eugenia W. Der for respondent

Mr. Pryor made a motion, Chair Kehoe seconded, to grant the option of an earlier effective date. The motion passed unanimously.

Alfred J. Castro – Michael Treger for applicant
Allison E. Barrett for respondent

Mr. Okum made a motion, Mr. Pryor seconded, to grant a service connected disability retirement and deny the option of an earlier effective date. The motion passed unanimously.

X. DISABILITY RETIREMENT CASES TO BE HELD IN CLOSED SESSION

B. Referee Reports (Continued) (Mr. Pryor left at 9:40 a.m.)

APPLICATION NO. & NAME

BOARD ACTION

Mary L. McFadden – Thomas J. Wicke for applicant
Allison E. Barrett for respondent

Ms. Gray made a motion, Chair Kehoe seconded, to grant a retroactive service connected disability retirement. The motion passed (roll call) with Messrs. Bravo, Robbins, Chery, Chair Kehoe, and Ms. Gray voting yes; and Messrs. Kelly, Bernstein, Okum, and de la Garza voting no.

C. Staff Recommendations

Mr. Muir made a motion, Mr. Okum seconded, to approve the following agenda items. The motion passed unanimously.

1. Recommendation as submitted by Allison E. Barrett, Senior Staff Counsel, Disability Litigation: That the Board find that the service-connected disability retirement application of **William F. Bennett, Jr.** be deemed filed on the day after the applicant's last day of regular compensation in accordance with Government Code Section 31724. (Letter dated December 10, 2015)
2. Recommendation as submitted by Steven Tallant, Senior Staff Counsel, Disability Litigation: That the Board find that **Craig Boyett** delayed the filing of his application for disability retirement because he was unable to ascertain the permanency of his incapacity and that his application be deemed filed on the day after the last day of regular compensation in accordance with Government Code Section 31724. (Letter dated December 15, 2015)

X. DISABILITY RETIREMENT CASES TO BE HELD IN CLOSED SESSION

C. Staff Recommendations (Continued)

3. Recommendation as submitted by JJ Popowich, Assistant Executive Officer: That the Board approve the service provider invoice for Gutierrez, Preciado & House, LLP. (Memo dated December 9, 2015)

Green Folder Information (Information distributed in each Board Member's Green Folder at the beginning of the meeting)

1. Retirement Board Listing dated January 6, 2016
2. Disability Retirement Evaluation Report Correction Memo – Marylou D. Velasquez (Memo dated January 5, 2016)

XI. ADJOURNMENT

There being no further business to come before the Board, the meeting was adjourned at 10:07 a.m.


WILLIAM DE LA GARZA, SECRETARY

SHAWN R. KEHOE, CHAIR



January 20, 2016

TO: Each Member
Board of Retirement

FROM: Ricki Contreras, Manager 
Disability Retirement Services Division

SUBJECT: **APPEALS FOR THE BOARD OF RETIREMENT'S MEETING OF
FEBRUARY 3, 2016**


IT IS RECOMMENDED that your Board grant the appeals and requests for administrative hearing received from the following applicants and direct the Disability Retirement Services Manager to refer each case to a referee:

6857A	Tammie D. Eckford	In Pro Per	Deny SCD
6850A	Rhonda A. Johnson	In Pro Per	Deny SCD Employer Can Accommodate
6861A	Ernesto D. Nunez	In Pro Per	Deny NSCD Employer Can Accommodate



January 13, 2016

TO: Each Member
Board of Retirement

FROM: Ricki Contreras, Manager 
Disability Retirement Services Division

FOR: February 3, 2016 Board of Retirement Meeting

SUBJECT: **DISMISS WITH PREJUDICE THE APPEAL OF
RICHARD M. FONTENOT**

Mr. Richard M. Fontenot applied for a service-connected disability retirement on April 30, 2012. On January 15, 2015, the Board denied Mr. Fontenot's application for service-connected disability retirement.

Mr. Fontenot's attorney filed a timely appeal. On January 5, 2016, the applicant's attorney advised LACERA that his client did not wish to proceed with his appeal.

IT IS THEREFORE RECOMMENDED THAT YOUR BOARD:


Dismiss with prejudice Richard M. Fontenot's appeal for a service-connected disability retirement.

FJB: RC: mb

Fontenot, Richard M. doc.

Attachment

NOTED AND REVIEWED:




Francis J. Boyd, Sr. Staff Counsel

Date: 1/13/16

January 20, 2016

TO: Each Member
Board of Retirement

FROM: Ricki Contreras, Manager 
Disability Retirement Services Division

FOR: February 3, 2016 Board of Retirement Meeting

SUBJECT: **DISMISS WITH PREJUDICE THE APPEAL OF
LAMBERTO R. VILLARROEL**

Mr. Lamberto R. Villarroel applied for a service-connected disability retirement on February 7, 2013. On March 11, 2014, the Board denied Mr. Villarroel's application for service-connected disability retirement and granted him a non-service connected disability retirement.

Mr. Villarroel filed a timely appeal. On January 19, 2016, Mr. Lamberto R. Villarroel signed a voluntary withdrawal letter advising LACERA that he does not wish to proceed with his appeal.

IT IS THEREFORE RECOMMENDED THAT YOUR BOARD:

Dismiss with prejudice Lamberto R. Villarroel's appeal for a service-connected disability retirement.

FJB: RC: mb

Villarroel, Lamberto R. doc.

Attachment

NOTED AND REVIEWED:


Francis J. Boyd, Sr. Staff Counsel

Date: 1/20/16

January 13, 2016

TO: Each Member
Board of Retirement

FROM: Disability Procedures & Services Committee
Vivian H. Gray, Chair
William de la Garza, Vice Chair
Yves Chery
Les Robbins
David Muir, Alternate

FOR: February 3, 2016 Board of Retirement Meeting

SUBJECT: **CONSIDER APPLICATION(S) FOR LACERA PANEL OF EXAMINING
PHYSICIAN(S)**

On January 6, 2016, the Disability Procedures & Services Committee reviewed the attached applications for the LACERA Panel of Examining Physicians.

The application packages have been reviewed by the Committee. After discussion, the Committee voted to accept the applications of the following physicians and submit to the Board of Retirement for approval to the LACERA panel.

IT IS THEREFORE RECOMMENDED THAT the Board approve the following physician to the LACERA Panel of Physicians for the purpose of examining disability retirement applicants.

Jason J. Chiu, M.D. – Board Certified Orthopedist


Attachments

VG:RC/mb



December 16, 2015

TO: Disability Procedures & Services Committee
Vivian H. Gray, Chair
William de la Garza, Vice Chair
William R. Pryor
Les Robbins
Yves Chery, Alternate

FROM: Ricki Contreras, Manager 
Disability Retirement Services Division

FOR: January 6, 2016, Disability Procedures and Services Committee Meeting

SUBJECT: **CONSIDER APPLICATION OF JASON J. CHIU, M.D., AS LACERA
PANEL PHYSICIAN**

On November 17, 2015, Debbie Semnanian interviewed Jason J. Chiu, M.D., a physician seeking appointment to the LACERA Panel of Examining Physicians.

Attached for your review and consideration are:


- Staff's Interview Summary and Recommendation
- Panel Physician Application
- Curriculum Vitae
- Sample Report(s).

IT IS THEREFORE RECOMMENDED THAT THE COMMITTEE accept the staff recommendation to submit the application of Jason J. Chiu, M.D., to the Board of Retirement for approval to the LACERA Panel of Examining Physicians.

Attachments

JJ:RC/sc

NOTED AND REVIEWED:



JJ Popowich, Assistant Executive Officer

Date: 12/22/15



December 11, 2015

TO: **Ricki Contreras, Manager**
Disability Retirement Services Division

FROM: **Debbie Semnanian, WCCP** DS
Supervising Disability Retirement Specialist

SUBJECT: **INTERVIEW OF ORTHOPEDIC SURGEON APPLYING FOR
LACERA PHYSICIAN'S PANEL**

On November 17, 2015, I interviewed **Jason Chiu**, M.D. at his office at 1220 Hemlock Way, Suite 205, Santa Ana, CA 92707. The office space is located in an older but well maintained three-story building with free parking located in the back and sides of the building.

Dr. Chiu is a board certified orthopedic surgeon who has been in private practice for fifteen years. Dr. Chiu shares office space with another LACERA panel orthopedist and several other physicians. He has available 5 complete examination rooms. Dr. Chiu estimates that 50 percent of his practice is devoted to patient treatment, while the other 50 percent of his time is devoted to evaluations primarily within the workers' compensation system and other retirement systems.

As referenced in his Curriculum Vitae, Dr. Chiu received his undergraduate degree from Massachusetts Institute of Technology and graduated from the University of California, Los Angeles with his medical degree in 1995. He completed his internship and a residency at the University of California, San Diego.

Dr. Chiu's office was clean with ample seating. The office and restrooms are handicap accessible and there is a staff of thirteen employees.

Staff reviewed the LACERA Disability Retirement procedures and expectations in its evaluation of County Employees applying for both service-connected and nonservice-connected disability retirements. The importance of preparing impartial and non-discriminatory reports that are clear and concise and address issues of causation and incapacity were discussed with the doctor. He understood that he would adhere strictly to the HIPAA laws that would also apply for LACERA reports. Staff reviewed with Dr. Chiu the Panel Physician Guidelines for evaluating LACERA applicants and defined the relationship between workers'

compensation and disability retirement. Staff discussed the need to rely on his own objective and subjective findings rather than the opinions of previous physician reports and/or comments.

Dr. Chiu agreed to adhere to LACERA's standard of having his evaluation reports sent to us within 30 days of examination. Staff confirmed that Dr. Chiu is agreeable with accepting payment per the Official Medical Fee Schedule (OMFS). He has also been advised of the requirement to immediately notify LACERA if any license, Board certification, or insurance coverage is lapsed, suspended or revoked. Dr. Chiu was informed that if he is approved by the Board to be on our panel of physicians, he is required to contact the specialist assigned to the case for approval of any special tests or extraordinary charges. He was also informed that a Quality Control Questionnaire is sent to each applicant regarding their visit.

RECOMMENDATION

LACERA has a need to add orthopedic physicians, particularly in the area in which Dr. Chiu completes examinations. He expressed not only a willingness to be on our panel, but also an enthusiasm for building a relationship with LACERA.

Based on our interview and the need for his specialty, staff recommends Dr. Chiu's application be presented to the Board for approval as a LACERA Panel Physician.



300 N. Lake Ave., Pasadena, CA 91101 ■ Mail to : PO Box 7060, Pasadena, CA 91109-706 626/564-2419 • 800/786-6464

GENERAL INFORMATION		Date
Group Name: <u>Golden State Physicians</u>	Physician Name: <u>Jason J. Chiu, M.D.</u>	
I. Primary Address: <u>1220 Hemlock, Suite 905, Santa Ana, CA 92707</u>		
Contact Person: <u>Bill Ellis</u>	Title: <u>Managing Director</u>	
Telephone: <u>1.714.755.0224</u>	Fax: <u>1.714.755.0578</u>	
II. Secondary Address		
Contact Person	Title	
Telephone	Fax	
PHYSICIAN BACKGROUND		
Field of Specialty: <u>Orthopedics</u>	Subspecialty	
Board Certification <input checked="" type="checkbox"/> Yes <input type="checkbox"/> No	License # <u>A62291</u>	Expiration Date
EXPERIENCE		
Indicate the number of years experience that you have in each category.		
Evaluation Type		
I. Workers' Compensation Evaluations		
<input type="checkbox"/> Defense	How Long? _____	<input checked="" type="checkbox"/> IME
<input type="checkbox"/> Applicant	How Long? _____	<input checked="" type="checkbox"/> QME
<input checked="" type="checkbox"/> AME	How Long? <u>10+</u>	How Long? <u>8+</u>
<input checked="" type="checkbox"/> Disability Evaluations	How Long? <u>8+</u>	How Long? <u>10+</u>
For What Public or Private Organizations? <u>OCERS, CalPERS</u>		
Currently Treating? <input checked="" type="checkbox"/> Yes <input type="checkbox"/> No		
Time Devoted to: Treatment	<u>50%</u>	Evaluations <u>50%</u>
Estimated Time from Appointment to Examination	Able to Submit a Final Report in 30 days?	
<input type="checkbox"/> 2 weeks	<input checked="" type="checkbox"/> Yes <input type="checkbox"/> No	
<input checked="" type="checkbox"/> 3-4 Weeks		
<input type="checkbox"/> Over a month		
LACERA's Fee Schedule		
Examination and Initial Report by Physician	\$1,500.00 flat fee	
Review of Records by Physician	\$350.00/hour	
Review of Records by Registered Nurse	\$75.00/hour	
Supplemental Report	\$350.00/hour	

Other Fees	
Physician's testimony at Administrative Hearing (includes travel & wait time)	\$350.00/hour
Deposition Fee at Physician's office	\$350.00/hour
Preparation for Expert Testimony at administrative Hearing	\$350.00/hour
Expert Witness Fees in Superior or Appellate Court	\$3,500.00 half day \$7,000 full day
Physician agrees with LACERA's fee schedule? Yes No	
Comments	

Name of person completing this form:

Jason Chiu, M.D. Title: 14 September 2015
(Please Print Name)

Physician Signature:  Date: _____

FOR OFFICE USE ONLY	
Physician Interview and Sight Inspection Schedule	
Interview Date:	Interview Time:
Interviewer:	

Jason J. Chiu, M.D.

Special Interest: Hip, Knee, & Shoulder Surgery

Locations: Santa Ana

Languages: Mandarin Chinese

EDUCATION & TRAINING

Undergraduate - Massachusetts Institute of Technology	1985-1989
Medical School - University of Virginia, School of Medicine	1991-1993
Internship - University of California, Los Angeles	1993-1995
University of California, San Diego	1995-1996
Fellowship - Howard Hughes Medical Institute Fellowship	1991-1993
University of California, San Diego	1996-1997
Residency - University of California, San Diego	1997-2001

Board Certification

American Board of Orthopedic Surgery

Certificates

Diplomate of United States Medical Licensing Examiners

American Academy of Orthopedic Surgeons

State of California

DEA

Radiology & Fluoroscopy

Industrial Medicine

Qualified Medical Examiner

Independent Medical Evaluator

1220 Hemlock Suite 205
Santa Ana, CA 92707
tel. 714.755.0224

JASON J. CHIU, M.D. Curriculum Vitae
Board Certified American Board Orthopedic Surgery
Languages: Mandarine Chinese English

Undergraduate

Massachusetts Institute of Technology
Cambridge, MA
Bachelor of Science – Chemistry 1985-1989
Phi Beta Kappa Honor Society
Merck Index Award (Highest GPA Honor)

Medical School

University of Virginia
Charlottesville, VA 1989 – 1991
Howard Hughes Medical Institute Fellow
Cloister Scholar 1991-1993

University of California, Los Angeles
Los Angeles, CA
Doctor of Medicine 1993-1995

Internship

University of California, San Diego
San Diego, CA
General Surgery Internship 1995-1996

Residency

Orthopedic Surgery Research Fellowship
1996-1997
University of California, San Diego
San Diego, CA
Orthopedic Surgery 1997-2001

Certificates

Board Certified American Board Orthopedic Surgery
National Board Medical Examiners
Licensure, State of California
American Academy of Orthopedic Surgeons
Qualified Medical Examiner, State of California 2007

Work History

Kaiser Permanente Medical Group 2001-2004
9961 Sierra Avenue, Fontana, CA 92335
Staff Physician

<i>Work History continued</i>	Orthopaedic Specialties Associates 4201 Torrance Boulevard, Suite 190 Torrance, CA 90503	2004-2005
	William Kim, M.D, Orthopedic Specialist Santa Ana, CA 92707	2004-2005
	Trieu Tran, M.D. Orthopedic Specialist Westminister, CA 92843	2005-2006
	Goldenstate Physician's Medical Group 1220 Hemlock Way, Suite 205 Santa Ana, California 92701	2006 to present
	Jason J. Chiu, M.D., Inc. (private practice) 10212 Westminster Avenue, Suite 102 Garden Grove, CA 92843	2007 to Present
<i>Government Employee Organizations</i>	Orange County Employees Retirement Association CalPERS	2007 to Present
<i>Hospital Staff</i>	Orange Coast Memorial	2004-2005
	Long Beach Memorial	2004-2005
	Fountain Valley Hospital	2006 –
	Garden Grove Hospital	2006 –
	Riverside Communities	2007 –

I take calls at the above hospitals currently and serve
In the Emergency Departments – on call
Solo Private Practice since 2007 with 50% of my time
spent in treating and 50% includes Workers'
Compensation/AME/QME/IME evaluations

JASON J. CHIU, M.D.

Board Certified, Orthopaedic Surgery

1220 HEMLOCK WAY, SUITE 205
SANTA ANA, CALIFORNIA 92707
[714] 755-0224 [714]755-0578[FAX]

3816 WOODRUFF AVENUE, SUITE 100
LONG BEACH, CALIFORNIA 90808
(562) 938-8494 [562] 429-9080 (FAX)

*Sample Report
#1*

TO: XXXXXXXX

**INDEPENDENT MEDICAL
EXAMINATION**

RE:
SSN: XXX-XX-XXXX
DOB: XXXX
EMP: County of XXXXXX
OCC:
DOI: CT
CHART#:

ORTHOPEDIC INDEPENDENT MEDICAL EXAMINATION

Dear Ms. _____:

Mr. _____ XXXXXXXX was seen in my Santa Ana office on _____
for an Orthopedic Independent Medical Examination with regard to his
application for disability retirement.

IDENTIFYING INFORMATION

Mr. XXXXXXXX is a _____-year-old right-handed male, who stands 6 feet tall

and weighs _____ pounds.

HISTORY OF INJURY

Mr. XXXXXXXX states that he developed pain in his neck, shoulders, hands and lower back from working as an _____ for XXXXXXXX, where he had been employed since _____.

"When I was hired in _____ my job entailed heavy lifting (up to 65 pounds), squatting, bending, kneeling, looking downwards for a long period of time, standing for long periods of time and operating various mailing equipment. Various inserting machines, sorting correspondence manually by hand, utilizing various folding machines, heavy pre-stuffing of packets containing 5 to 27 inserts manually by hand on a daily basis, repetitive hand movement. Over the course of the years, the above actions took a cumulative effect on various parts of my body."

TREATMENT HISTORY

Mr. XXXXXXXX states that he had been experiencing pain in his neck and hands, but he never complained to his employer.

On _____, he went to the doctors at UCI for evaluation. He was told that there were "issues in his neck" and that he has carpal tunnel syndrome.

He was referred to Dr. Jeffrey Deckey for evaluation of his cervical spine. He was referred to Dr. Andres Taleisnik for evaluation of carpal tunnel disease. He underwent MRI examinations. He underwent electrodiagnostic studies of the upper extremities.

In _____, he underwent left carpal tunnel release. In _____, he underwent right carpal tunnel release. Both surgeries were performed by Dr. Taleisnik.

Later, he transferred his care to Dr. Ranjan Gupta and to Dr. Nitin Bhatia at UCI Medical Center. He underwent repeat left carpal tunnel release surgery. He underwent a left shoulder surgery in _____. He underwent cervical spine

surgery and he underwent lumbar spine surgery.

Currently, he is still under the care of Dr. Gupta and Dr. Bhatia. He also sees Dr. Iskander and Dr. Pacius for various ailments regarding his neck and low back.

PRESENT COMPLAINTS

Mr. XXXXXXX states that he has pain in the following body parts:

1. Back of right deltoid.
2. The inside of his hands along the fingertips and palms.
3. Wrist, forearm and right arm.
4. Neck and left side of the throat.
5. Pain inside of his groin.
6. Sharp pain in the mid low back.
7. Sharp pain radiating down into the buttocks and hamstrings.
8. His legs give out.
9. Pain radiating down into his calves and feet.

Mr. XXXXXXX states that his left foot slipped off some steps a while ago. He felt something snap in his left calf and heel. He had bruising along his left leg. He had pain and limp in his left leg since that incident. This incident did not happen at work.

He states that prolonged standing, looking downward and constant sitting at a work desk aggravate his symptoms. Sitting in a reclining chair with a neck pillow alleviates them. He denies bowel or bladder dysfunction.

He states, "I do not make love to my wife like I used to back in the days because of pain and discomfort. I cannot lightly jog because of pain. I cannot over exercise because of the pain. Sleeping is a task within itself when I am trying to sleep. It makes it much more difficult to exercise consistently. It is a task to try to write a couple of sentences without feeling any pain or discomfort."

RE: XXXXXXXXXXXXXXX

4

XX, 20XX

PRIOR INJURIES

Work-Related Injuries: right shoulder partial rotator cuff tear; neck strain; low back strain.

Nonwork-Related Injuries: Left knee playing softball; fender-bender.

PAST MEDICAL HISTORY

Major Illnesses/Serious Diseases: None.

Surgeries: left carpal tunnel release; right carpal tunnel release; repeat left carpal tunnel release; lumbar spinal surgery; left shoulder surgery; cervical spine surgery; left foot bunion surgery.

Current Medications: Cymbalta, Lyrica, Norco, Ambien, diazepam, Naprosyn and Tamsulosin.

Allergies: None.

FAMILY HISTORY

Mr. XXXXXXX has brothers and sisters. His father is deceased. His mother is age . . .

PERSONAL AND SOCIAL HISTORY

He does not smoke tobacco; he does not consume alcohol. He is married and has children.

He has an Associate Degree. His hobbies include reading the Bible and

He has never served in the military.

OCCUPATIONAL HISTORY

- 1.
- 2.
- 3.
- 4.

He states that he filed retirement from _____ of XXXXXX on _____

JOB DESCRIPTION

Mr. XXXXXXX states that he worked as an _____ nt from _____ : to _____ . He became Accounting Supervisor from _____) until his retirement in _____

He worked from seven a.m. until four p.m., Monday through Friday.

As an _____ r, he assisted _____ in benefits control in the day-to-day operations. He assisted benefit control staff in resolving issues by following established guidelines and consulting with _____ accounting unit supervisor and/or district service manager. He acted as a back-up senior supervisor for all job responsibilities and benefit control staff. He kept detailed notes and records up-to-date, update _____ timely and accurately. He assisted the senior accounting office supervisor in monitoring all district accounting performances.

During the course of his work day, the work hours are spread between sitting, standing and walking. He lifted and carried up to 10 pounds. He used his hands for grasping, pushing, fine manipulation, pulling and reaching. He performed occasional bending, squatting and kneeling.

PHYSICAL EXAMINATION

Mr. XXXXXXXX has a tall stature. He has a slightly obese body build. He sits comfortably during the interview. He requires no assistance with movement. He ambulates with a limp. He appears to be in no acute distress.

He displays appropriate emotional affect. His speech is slightly pressured.

CERVICAL SPINEInspection:

There is a well-healed incision across the left anterior neck from cervical spine surgery. He has a normal head carriage.

Palpation:

The left upper trapezius muscle is tender. There is no appreciable muscle spasm or tightness. The anterior cervical incision site is slightly tender.

Ranges of Motion:

Flexion	5 degrees
Extension	20 degrees
Right Lateral Bending	15 degrees
Left Lateral Bending	20 degrees
Right Rotation	35 degrees
Left Rotation	35 degrees

RE: XXXXXXXXXXXXXXX

7

XX, 20XX

NEUROLOGICAL EXAMINATION

Deep Tendon Reflexes: Right Left

Biceps 2+ 1+

Triceps 2+ 2+

Brachioradialis 2+ 2+

Special Testing:

Compression test: Negative

Traction test: Negative

Spurling's sign: Positive

Adson's test: Negative

Motor: Right/Normal/Left

Deltoids 5/55/5

Biceps 5/55/5

Triceps 5/55/5

Brachialis 5/55/5

Wrist Extensors 5/55/5

Wrist Flexors 5/55/5

Hand Abductors 5/55/5

Vascular: Right Left

Radial Pulse 2+ 2+

Ulnar Pulse 2+ 2+

SHOULDERSInspection:

There are well-healed arthroscopic portal scars about the left shoulder.

Palpation:

Palpation reveals that the anterior aspects of the acromions are not tender. The bicipital grooves are not tender. The subdeltoid bursae are not tender, and there are no signs of inflammation.

There is no palpable defect, crepitus or tenderness at the acromioclavicular joints.

The superior, vertebral and lateral borders of the scapulae are not tender. There is no tenderness of the axillae. Latissimus dorsi and pectoralis major are not tender from its origin to its insertion.

Range of Motion:

Range of motion is full and without pain in all planes. There is normal scapulothoracic movement and normal glenohumeral joint motion.

<u>Special Testing:</u>	<u>Right</u>	<u>Left</u>
Impingement sign:	Negative	Negative
Apprehension sign:	Negative	Negative
Sulcus sign:	Negative	Negative
Drop-arm sign:	Negative	Negative

ELBOWSInspection:

There is no obvious deformity of the carrying angle. There are no abrasions noted. There is no diffuse or localized swelling noted.

Palpation:

There is slight tenderness along the right lateral radial forearm and lateral epicondyle. There is no tenderness around the ulnar notches where the ulnar nerves pass. There is no tenderness of the medial epicondyles. There is no tenderness of the wrist flexors. There is no tenderness of the radial heads. There is no tenderness of the wrist extensors. There is no tenderness of the collateral and ulnar ligaments. There is no tenderness or defect noted to the areas of the olecranon bursae or along the course of the triceps muscles. There is no tenderness or defect noted at the biceps muscle insertions or the cubital fossae.

Range of Motion:	<u>Normal</u> <u>Right</u> <u>Left</u>	
Extension-Flexion	0-135°0-135°0-135°	
Pronation	0-75°0-75°0-75°	
Supination	0-85°0-85°0-85°	
<u>Special Testing:</u>	<u>Right</u>	<u>Left</u>
Mill's test:	Negative	Negative
Reverse Mill's test:	Negative	Negative

WRISTS AND HANDSInspection:

There are well-healed surgical scars across both carpal canals. There is left thenar muscle atrophy noted. His hand posture shows normal cascade.

Palpation:

The left thenar muscles are tender.

There is no tenderness over the anatomical snuff boxes or radial styloids on

palpation. Finkelstein's test for de Quervain's tenosynovitis is negative.

There is no tenderness over the carpal tunnels. Tinel's sign is negative. Phalen's test with the wrists flexed to 90° to reproduce symptoms of carpal tunnel syndrome is negative.

Range of Motion:

Wrist:	<u>Normal</u>	<u>Right</u>	<u>Left</u>
Palmar Flexion	0 – 60°	0 – 60°	0 – 60°
Dorsiflexion/Extension	0 – 60°	0 – 60°	0 – 60°
Radial Deviation	0 – 20°	0 – 20°	0 – 20°
Ulnar Deviation	0 – 30°	0 – 30°	0 – 30°

1 st Finger (Thumb):	<u>Normal</u>	<u>Right</u>	<u>Left</u>
Interphalangeal	0 – 80°	0 – 80°	0 – 80°
Metacarpophalangeal	0 – 60°	0 – 60°	0 – 60°
Radial Abduction	0 – 50°	0 – 50°	0 – 50°

Thumb adduction: he is able to touch the metacarpophalangeal joint of the small finger on the right and on the left.

Thumb opposition: he is able to touch the metacarpophalangeal joint of the long finger on the right and on the left.

Neurological:

He reports altered and mixed sensation in both hands in no specific distribution. He shows good hand and thumb opposition strength. He shows good finger dexterity demonstrating the ability to clench, claw, abduct and adduct the digits.

Vascular:

Allen's test show good collateral circulation in his hands. Radial pulse is 2+. Capillary refill to all digits is normal.

RE: XXXXXXXXXXXXXXX

11

XX, 20XX

Measurements:

Right

Left

Arms

38 cm

37 cm

Forearms

33 cm

32.5 cm

Jamar Dynamometer Grip Strength Testing: (in kilograms)

Right Hand: 10/12/10

Left Hand: 18/18/17

LUMBOSACRAL SPINE

Inspection:

There is a well-healed incision along the dorsal trunk. There is no sign of thoracolumbar scoliosis.

Palpation:

There is tenderness at the lumbosacral junction. There is no appreciable muscle spasm or tightness noted.

Range of Motion:

Flexion:

20 degrees

Extension:

5 degrees

Right Side Bending:

15 degrees

Left Side Bending:

15 degrees

Special Testing:

Straight-leg-raise test and cross straight-leg-raise test is negative.

HIPSPalpation:

There is no tenderness to palpation over the greater trochanter, anterior aspect of the groin, sciatic notch, or adductor muscles.

Range of motion:

He displays no discernible limitation or pain with movement of the hips.

Special Testing:RightLeft

Fabere's test:

Negative

Negative

ANKLES AND FEETInspection:

There is bruising along the left calf and left heel.

Palpation:

The left Achilles tendon is painful in the musculotendinous junction.

Special Testing:

Thompson's test is positive on the left calf indicative of Achilles tendon rupture.

Measurements:RightLeft

Quadriceps muscle mass
10 cm above superior
margin of patella

52 cm

52 cm

Calf muscle mass at
point of maximum growth

42 cm

42 cm

REVIEW OF MEDICAL RECORDS

, Healthcare Note.

Return to Work , with limited lifting or carrying up to 25 pounds. Non-work related condition. Nurse's signature is illegible.

, Supervisor and Employer's Report of Occupational Injury or Illness for date of injury of

Employee states severe pain in back due to large volume of work process. Works in accounting, supervisor I.

, Employer's Report of Occupational Injury or Illness for date of injury of

Lifting and stacking boxed. Was also placing boxes above his head. Notes body parts, neck, shoulders and hand.

, Work Status Note from Tustin Employee Health Center.

Complaining of neck, upper back, and left hand numbness and redness. He was lifting a 40-pound box overhead and felt pain. Blood pressure 120/64, listed as feet pounds. Also felt pain in upper back and neck, may be due to repetitive motion, pain on hand and numbness x2 weeks. Actual examination notes are most difficult to decipher. Upper thoracic area TTP, along trap muscles. Neck, positive TTP with full range of motion. Negative impingement.

Assessment:

1. Upper thoracic strain.
2. Neck sprain and strain.
3. Chronic OA of neck/hands.

X-rays were taken, no details. Motrin and Flexeril given. Modified duties of no lifting over 25 pounds. No work with either arm above shoulder

level.

, Orthopedic Medical Report from Dr. Jeffrey Deckey.

Applicant presents with a history of neck and arm pain present for the last four to five years. He has tried cervical traction as well as therapy and epidurals. His pain has become quite severe. He also has a history of lumbar pain as well as sciatica, however, neck is certainly worse than back. Left arm is greater than right arm. He has some numbness and weakness but denies any specific balance problems or significant difficulty with motor movement. Past medical history includes bunion surgery, no details. Home medications are Naprosyn and unknown muscle relaxant. Nonsmoker. On examination, current weight 217 pounds. Normal gait. Motor strength is 5/5 in upper extremities bilaterally. DTRs are 2+. Negative Hoffman sign. Negative Romberg sign. Apparently, **x-rays show severe degeneration at C5-C6 and C6-C7 with large disk osteophytes anteriorly and disk space collapse. An MRI from a year ago demonstrated foraminal stenosis at these levels without significant cord compression.**

Diagnosis: Cervical spondylosis with cervical radiculopathy.

Dr. Deckey had a lengthy discussion with the applicant and first recommended more recent MRI of the cervical spine. Applicant is inquiring about cervical disk replacement. He was told that this certainly was an option; however, given that he has significant amount of neuropathic symptoms and significant foraminal stenosis, Dr. Deckey felt that there is chance of recurrence of his symptoms if motion was preserved. In addition, given the degenerative changes, he likely has a fair amount of facet changes which would be persistent despite a disk replacement. I will discuss other options after MRI.

, MRI of Cervical Spine without Contrast from Dr. Masotto.

1. DDD, combined with **congenital shortening of the pedicles** that resulted in central spinal canal stenosis from C3-C4 through C6-C7.

2. There was compression and deformity of the cervical cord at C5-C6 and C6-C7 levels.

When compared to prior MRI of _____, there has been progression of the disease at C3-C4 level. C3-C4 level showed mild **hypertrophy of the left facet complex and left uncovertebral joint**. There was mild congenital shortening of the pedicles. The combination of findings resulted in mild **central spinal canal stenosis** and **moderate bilateral neuroforaminal narrowing**. This appeared slightly worse when compared to _____.

_____, Work Status Notice from employee health.

Limited lifting and carrying up to 10 pounds. No work with either arm above shoulder level.

_____, Work Status Notice from employee health.

Same work restrictions.

_____, MRI of Cervical Spine from Dr. Dan Vu.

DDD combined with **congenial short pedicles** at multiple levels that results in mild-to-moderate **central canal stenosis** and mild-to-moderate neuroforaminal narrowing. The findings were slightly worse in comparison to _____ MRI. At C3-C4, there was disk desiccation. The disk height was maintained. The tiny diffuse disk osteophyte complex was present as previously noted. There was also left unconvertible joint hypertrophy seen. The result was mild bilateral neuroforaminal narrowing, left worse than right. There was also mild central canal narrowing noted. The findings were unchanged from prior examination. C4-C5 showed disk desiccation. A small diffuse disk osteophyte complex was seen. The applicant has congenial short pedicles. The result was mild central canal narrowing. There was minimal left neuroforaminal narrowing noted. C5-C6 showed severe DDD with noted with disk desiccation and decreased disk height. A moderate sized diffuse disk osteophyte complex was seen. Applicant

also has congenial short pedicles. The result was moderate central stenosis. There was moderately severe bilateral neuroforaminal narrowing. The findings appears slightly worse compared to prior examination. C6-C7 showed severe DDD present with disk desiccation and decreased disk height. A moderate sized diffuse disk osteophyte complex was present. The applicant also has mild congenial short pedicles. The result was moderate central canal stenosis. There was moderate left neuroforaminal narrowing seen, with mild right neuroforaminal narrowing noted. Findings appear slightly worse in comparison to prior examination. C7-T1 showed disk desiccation. Bilateral unconvertible joint hypertrophy noted, left worse than right. There was a left lateral disk osteophyte complex seen, that resulted in moderate left lateral recess narrowing. There was moderate left neuroforaminal narrowing with mild right neuroforaminal narrowing. The central canal was mildly narrowed.

5, MRI of Lumbar Spine from Dr. Vu, referred by Dr. Deckey.

1. At L4-L5, there was **severe DDD**. A small diffuse disk bulge was seen in addition to right paracentral focal disk protrusion that resulted in mild central canal narrowing, moderate right lateral recess narrowing, and mild-to-moderate bilateral neuroforaminal narrowing.
2. At L5-S1, there was moderate DDD present with a small diffused disk bulge in addition to focal central disk protrusion/extrusion. Mild facet arthrosis was also seen. The result was mild central canal narrowing with mild bilateral neuroforaminal narrowing noted.

Clinical history of lower back pain radiating down to the legs and ankles greater on the left.

Electrodiagnostic Study from Dr. Schreiber. Referred by Dr. Lynn Wilson.

EMG NCV of both upper limbs was consistent with **bilateral CTS**, moderate – severe. No other details.

Doctor's First Report, Tustin Irvine Medical Group. Dr. Roman Shulze.

He has been a [redacted] x5 years. Complain of bilateral wrist pain that began on the left and then went to the right. Exam showed positive TTP volar wrist, but negative Tinel's and Phalen's and Finkelstein's. Other complains of numbness in the fourth and fifth digits. Full range of motion.

Assessment: Bilateral wrist tendinitis.

He is given bilateral Neoprene wrist braces. Physical therapy three times. There is a notation for CTS by Dr. Schreiber. Bone spur and C-spine declined surgery. He had steroid injection December 2004. He has attorney. Not disabled from work.

[redacted], Employer's Report of Occupational Injury for date of injury

He states he hurt his wrist and hands due to lifting.

Work Progress and Status Report from Dr. Alevizes.

Home doctor told the applicant has bilateral CTS, declined surgery. Suspended from work today until [redacted]. Negative Tinel's and Phalen's. Grip is 5/5 very strong. No swelling. Grip strength on the right 135/135/135, on the left 120/100/110.

Assessment: Bilateral wrist tendinitis.

Go to therapy. [redacted], he was told by a private doctor he has bilateral CTS needs surgery.

Doctor's First Report of Occupational Injury Illness for date of injury [redacted] Signature is missing.

Applicant has work injury he states due to repetitive use of his hands

along with lifting and moving mail trays and data boxes. Objectively, multiple positive musculoskeletal signs and symptoms.

Diagnoses:

1. Carpal tunnel syndrome.
2. Cervical brachial syndrome.

Plan is for chiropractic treatment, laser therapy.

Work Progress and Status Report from Dr. Alevizes.

He states bilateral wrist is still painful. Better with therapy. Refusing injections at this time. Doing regular work. Continue therapy. Tendinitis.

Work Status Note from Tustin Irvine Medical Group.

Not wanting steroid injections. Therapy is helping. He has gotten total of 18 sessions so far. Of note, on exam from physician's assistant positive Tinel's bilaterally. Decreased grip 3/5. Bilateral wrist tendinitis. Continue PT and chiro. No refill of unknown meds needed. Regular duties.

X-Rays of Cervical Spine series complete from Dr. Krimsky.
Referred by Dr. Robert Glover D.C.

Degenerative changes. Disk space narrowing and anterior and posterior spurs formation at C5-C6 and C6-C7 with neural foraminal encroachment bilateral at these segments. Straightening indicates muscle spasms.

PR-2 report from Robert Glover D.C.

Diagnoses:

1. Carpal tunnel syndrome.

2. Cervical brachial syndrome.
3. Cervical segmental dysfunction/myospasm.

In modified duties of no repetitive gripping or grabbing or pinching. Take 3 to 5 minute breaks per hour, micro stretch.

Work Progress and Status Report from Tustin Irvine Medical Group.

Apparently per Dr. Alevizes, under lot of stress from work, went to urgent care, had EKG. "They are trying to get rid of me." Currently he is seeing chiro in Irvine for a bilateral wrist carpal tunnel. Wrists are getting worse. Rest is very difficult to read. Positive Tinel's negative Phalen's. If possible, different work station for future. Applicant came in at 10:30 to see me however did not see other doctor, I was in Irvine Clinic.

, Work Progress and Status Report from Dr. Shulze.

He was off work felt better now positive Tinel's, negative Phalen's on the right, negative Tinel's and Phalen's on the left. Rule out CTS. Acupuncture. No excessive use of right and left hand and wrist. No repetitive use of bilateral hands and wrist for more than 15 minutes each hour. Typing 15 minutes and then change.

, Work Progress and Status Report from Physicians Assistant.

He feels better when he takes some time off, but pain resumes when he goes back to work. We will consider acupuncture. Objective findings show positive left paravertebral muscle tightness. Only positive Phalen's and Tinel's left greater than right wrist. Positive DTP left lateral forearm.

Diagnosis: Bilateral carpal tunnel syndrome.

Plan is to start acupuncture when approved. He is given sample of Celebrex x11 days. Elbow strap for left forearm.

- Work Progress and Status Report at Tustin Irvine Medical Group.

Very difficult to read. CT S. Modified duties.

PR-2 report from Robert Glover D.C.

Applicant states the arrangement of his work space makes him difficult to work and perform his duty increases his pain.

Diagnosis: Unchanged.

Chiropractic treatment and modified duties.

Notice of Temporary Restrictions.

No continuous computer input. Limited bending head downwards. No continuous pinch and grip activities.

Handwritten Note for Modified Duties from Gateway Regional Medical Center.

Difficult to read.

PR-2 report from Robert Glover D.C.

Status unchanged.

MRI of the Right Shoulder from Dr. Karlin also MRD. Referred by Dr. Chuan Nguyen.

1. Partial tear noted at the rotator cuff tendon.
2. Findings above appear to represent sequel from a paralabral cyst which could be associated with a labral tear. Recommend correlation with MR shoulder arthrogram.
3. Mild degenerative changes.

Findings: there was a small periarticular effusion. There was abnormal signal noted involving the articular surface at the distal rotator cuff

tendon, which most likely reflect sequel from a partial tear.

No evidence of bone marrow edema identified within the proximal humerus. A few subcorneal cysts were noted within the humeral head. There was a mildly down sloping acromion with mild degenerative changes at the AC articulation. Biceps tendon appears normal. There was an approximately 2.7 cm well circumscribed elliptical shaped area of T2 prolongation noted within the subscapular notch adjacent to the contigous with the posterior superior labrum. Findings were suspicious for a paralabral cyst again associated with a labral tear.

12/20/00, MRI of the Left Shoulder from Dr. Karlin.

1. Small thickness rotator cuff tendons tear.
2. Mild degenerative changes.
3. There was subchondral cyst noted within the humeral head.
4. There is a small periarticular effusion noted.
5. There was abnormal signal involving the distal rotator cuff tendon at its insertion site into the greater tuberosity.

Return to Work Note for [REDACTED] apparently from Dr. Nguyen at Gateway Regional Medical Center.

Offer consult for bilateral shoulder tears.

Supplemental AME Report from Dr. Lynn Edward Wilson.

MRI scans of the bilateral shoulders revealed along with PR-2 reports from chiropractor Glover and [REDACTED] electrodiagnostic study from Dr. Schreiber. Dr. Wilson comments based on additional medical documentation:

1. Long history of DDD, L4-L5 with radiculitis and radiculopathy right lower extremity dating **back to** [REDACTED] according to medical records.
2. Long history of DDD with cervical sprains and associated shoulder

complaints **dating back to approximately** with history of bilateral shoulder pain secondary to cervical DDD and combination of **rotator cuff strains from athletic activities** and circuit training.

3. Bilateral carpal tunnel syndrome moderate-severe per nerve conduction studies.
4. Bilateral shoulder sprain strain syndrome with rotator cuff disease mild and AC arthritis, mild.

In discussion, clearly **this is a long history of chronic problems involving the neck, shoulders in the lower back with headaches of the muscle tension type associated with neck pain that dates back to**

Dr. Wilson reviewed voluminous records including medical records from the applicant's personal physicians, and it is clear that he has had significant problems with his neck and lower back. His records states that he is not aware of any injury to his neck or lower back of a specific nature and Dr. Wilson believes that is true. However, Dr. Wilson did not find any medical evidence that back him to the documentation reviewed that the applicant ever told the physician that he experienced pain as a result of any work related injury to his neck or back. Likewise, Dr. Wilson did not find any medical evidence in the records available that any physician ever told the applicant that he thought the applicant's symptoms/disability with regard to the spine or upper extremities was either cause aggravated exhilarated as a result of job related activities. In conclusion, Dr. Wilson cannot find any medical evidence to support the claimed injury of alleging an injury to his back. Dr. Wilson cannot find any medical evidence from the documentation reviewed that the applicant had sustained any significant injury of cumulative trauma nature or specific injury to the neck. In Dr. Wilson's opinion there was evidence the applicant sustained cumulative trauma, from and continuing as he relates the upper extremities and hands and shoulders.

Under SB899 taking effect all dates of injuries, apportionment of permanent disability is not based upon causation. In review of the guidelines of board held in Dr. Wilson will make determination and a 100% of current disability of the

cervicothoracic and lumbosacral spine was attributable to nonindustrial causation. 50% of the applicant's current disability for hands and wrist, namely the carpal tunnel syndrome is attributable to nonindustrial causation. 50% current disability of hands and wrist is attributable to nonindustrial causation in the form of weightlifting and other exercises of repetitive nature involving repetitive gripping and resulting in tendinitis and secondary carpal tunnel syndrome. 50% of the current disability for shoulders attributable to weightlifting and other exercises that is nonindustrial. 50% of current disability attributable to work related activities as detailed in his AME report. Applicant was permanent and stationary when evaluated by Dr. Wilson . . . assuming he did not wish to proceed with carpal tunnel releases. Applicant was precluded from performing repetitive climbing manipulation movements that the thing is more than one hour without the ability to rest for 15 minutes after each one hour of repetitive movements. No specific work restrictions for the shoulders. Future medical should authorize bilateral carpal tunnel release if he elects to do so industrial basis. Splints whenever they wear off. He does not require surgery on his shoulders, but would benefit from therapeutic exercises in combination with OTC meds, ice, and heat. Multiple pages of treatment criteria and WCAB guidelines reviewed.

. . . , Medical Letter from Laura Huang, LAC.

On initial exam there was no obvious intrinsic atrophy, however they did find that his left shoulder was exquisitely sensitive. He describes his upper extremities as being weak resulting in inflammation of both tendons and nerves that lead to this abnormality. Acupuncture had helped greatly in reducing pain levels of his upper extremities.

. . . , Treatment Authorization Request by PTP Robert Glover D.C.

Assessment:

1. Bilateral carpal tunnel syndrome.
2. Right partial rotator cuff tendon tear, mild degenerative changes.
3. Left small thickness rotator cuff tendon tear, mild degenerative

changes.

- 4. Cervical segmental dysfunction.
- 5. Cervical brachial syndrome.
- 6. Associated mild spasm.
- 7. Lumbar radiculopathy secondary to lumbar disk herniation.
- 8. Lumbar segmental dysfunction.

Applicant states he never suffered an injury to his low back, but has noted gradual increased pain in the lower back since before . In , he underwent series of lumbar epidural steroid injections provided at Mulligan Medical Clinic. He reported two years of complete resolution of his pain following this treatment. He was seen by Dr. Deckey. He underwent MRI of lumbar spine , which he states he had confirmed a focal 7 mm paracentral disk protrusion at L4-L5 with mild central canal stenosis and moderate right lateral recess stenosis etc. MRI of the cervical spine from was reviewed. MRI of the bilateral shoulders from June 2005 was noted. Apparently we will request authorization for additional chiropractic treatment. Applicant was TTD.

, PR-2 report from Robert Glover, D.C.

Diagnoses:

- 1. Bilateral rotator cuff rupture/carpal tunnel syndrome.
- 2. Cervical brachial syndrome/ thoracalgia.
- 3. Cervical-lumbar segmental dysfunction/mild spasm.

Continue chiropractic treatment and acupuncture and Tens unit etc.
Modified duties.

, Consultation by Hand Specialist Dr. Andres Taleisnik.

Date of injury listed as F Applicant reports she has developed symptoms in bilateral upper extremities approximately , . They became more severe and approximately by continued . Applicant began his employment with of XXXXXX in

. He is an accounting supervisor. Job duties involve extensive mailing. He also types and operates mail post machines. He performs extensive sorting and must lift boxes weight 45 to 55 pounds. He states he has been performing his usual duty since

Additional past history note of bunion surgery Current medications as Zetia and Lopid. Applicant is married with . . . children. Nonsmoker. Family history is positive for multiple sclerosis in applicant's

On exam, upper extremity measurements and biceps 34.0cm/35.0cm. Forearms 34/34 cm, wrist 18.5/18.5 cm. Normal range of motion of bilateral shoulders although internal rotation was painful bilaterally. There is tenderness noted over the anterior and lateral aspect of the right shoulder and over the anterior aspect of the left shoulder. Normal symmetric range of motion bilateral elbows with slight tenderness over the lateral epicondyle bilaterally with none over the medial epicondyle. Pronation 90/90, supination 90/90, dorsiflexion 63/80, palmar flexion 59/70 degrees, radial deviation 19/21 degrees, ulnar deviation 44/37 degrees. Wrist exam revealed tenderness over the volar aspect bilaterally, with slight diffused tenderness over the dorsum of the right wrist as well. Finkelstein test and axial grind test of the thumbs were not painful. No swelling or instability bilaterally. Hands show normal symmetric range of motion. He is able to make a complete fist. Full opposition of thumb tips to metacarpal head from fifth. Grip strength on the right 149/150/130, on the left 139/143/128. Light touch sensation was described as "tingly" in the right middle and ring fingers, and in the radial fourth digits of the left hand, sparing the small finger. There was possibly mild left thenar atrophy. Provocative test at carpal tunnels were all positive bilaterally including Tinel's sign, carpal compression test and Phalen's test.

Diagnoses:

1. Bilateral carpal tunnel syndrome.
2. Bilateral shoulder pain with MRI evidence of rotator cuff injury.
3. Mild bilateral lateral epicondylitis.

In discussion, the applicant has already used wrist braces with incomplete symptomatic relief. He does not wish to attempt

corticosteroid injections and prefers to proceed directly with surgery.

He would like to do left side first. Applicant also complains of persistent pain in the shoulders. Dr. Wilson, AME, suggested the applicant received orthopedic consultation to supervise treatment likely to begin with supervised therapy. We will recommend evaluation with Dr. Ghalambor. Continue regular duties pending authorization for surgery.

History and Physical from Dr. Taleisnik at Main Street Surgery Center.

Exam unchanged.

Diagnosis: Bilateral carpal tunnel syndrome.

Proceed with left side first.

, Operative Report from Dr. Andres Taleisnik.

1. Complete left wrist flexor tenosynovectomy.
2. Left carpal tunnel release.

Diagnoses:

1. Left carpal tunnel syndrome.
2. Proliferative, hypertrophic flexor tenosynovium, left wrist.

In findings, applicant is noted to have very thick transverse carpal ligament, with a very significant muscular component. There was also marked thickening and edema of the flexor tenosynovium that created a rind of tissue around the flexor tendons at the carpal tunnel level. Discharge instruction sheet with Vicodin. Weight pounds.

Handwritten PR-2 Report from Dr. Andres Taleisnik.

Wounds are healing illegible. We will schedule right side.

Preop History And Physical from Dr. Andres Taleisnik.

Diagnosis: Right carpal tunnel syndrome.

Operative Report from Dr. Andres Taleisnik.

1. Complete, foraminal right wrist flexor tenosynovectomy.
2. Right carpal tunnel release.

Diagnoses:

1. Severely edematous, hypertrophic right wrist flexor tenosynovium.
2. Right carpal tunnel syndrome.

PR-2 report from Dr. Andres Taleisnik's office.

Three days postop. Handwriting is difficult.

PR-2 report from Dr. Andres Taleisnik.

15 days postop. On the left he felt immediate improvement after surgery on the right still feeling some numbness like preop. Rest is completely illegible.

Handwritten PR-2 Report from Dr. Andres Taleisnik.

Right hand is still hypersensitive in median nerve distribution with no improvement in numbness since surgery. Left hand is doing well. Repeat electrodiagnostic studies. Off work.

Electrodiagnostic Study from Dr. Hakimian.

1. Entrapment neuropathy of the medial nerves at both wrists with moderate slowing of the nerve conduction velocity, carpal tunnel syndrome. Applicant is status post bilateral carpal tunnel release. There is no previous study available for comparison.
2. No evidence to support distal peripheral neuropathy in the upper

extremities. No evidence to support motor radiculopathy in the upper extremities.

PR-2 Report from Dr. Andres Taleisnik.

Applicant is last seen [redacted]. An electrodiagnostic studies are reviewed. Right side is hypersensitive. Plan is to inject right carpal tunnel apparently. Modified duties of no lifting, pushing, or pulling over 10 to 20 pounds.

PR-2 Report from Dr. Andres Taleisnik's office.

He states since injection to right hand he is feeling more hypersensitive. Also has pain in left arm. Very difficult to read. Range of motion okay. Modified duties. Recommend repeat left CTR surgery with more extensive exposure as he is "absolutely" sure that median nerve is not compressed by a band of scar tissue.

PR-2 Report from Dr. Andres Taleisnik's office.

Again right hand is worse. Very difficult to read. Awaiting authorization for repeat right CTR not left. Request cold therapy unit.

Office Note from Dr. Andres Taleisnik's office.

Applicant is TTD beginning [redacted]. I do not know what else to do keep him working in same capacity. We received detailed faxes from the applicant saying that he cannot do his job duties provided for him.

Office Note from the Hand Care Center Shoulder and Elbow Institute.

Employer cannot accommodate restrictions therefore he is TTD until surgery.

X-Rays of Left Hand Three Views from UCI.

Normal exam of the left hand. Right hand three views, unremarkable.

UCI Progress Note

Recommend home medications are Zetia and Lopid. Want second opinion on bilateral hands. Grip strength on the right 105/105/100, on the left 105/100/95. Handwritten chart note is very difficult.

Notice of Temporary Work Restrictions.

No handwriting with upper extremities. No keyboarding with left upper extremity.

MRI of the Left Wrist without Contrast from Dr. Ohanian. Referred by Dr. Gupta Rajan.

1. Small intra osseous ganglion cyst in the capitate and hamate. These were benign incidental findings.
2. Intact triangular fiber cartilage.
3. Abnormal hyper intensity and mild swelling of the median nerve consistent with carpal tunnel syndrome. This appearance was similar to the right wrist.
4. Volar convexity of the flexor retinaculum presumably related to prior carpal tunnel release. Note that volar convexity can also be seen in the setting of the carpal tunnel syndrome without prior surgery.

MRI of the Right Wrist without Contrast from Dr. Ohanian.

1. Abnormal hyper intensity and mild swelling of the median nerve consistent with carpal tunnel syndrome.
2. Volar convexity of the flexor retinaculum presumably related to prior carpal tunnel release. Note that volar convexity can also be seen in the setting of carpal tunnel syndrome without prior surgery.
3. Intact triangular fiber cartilage.

, Return to Work Note from Gateway Regional Medical Center Dr. Chuan Nguyen.

Applicant has carpal tunnel syndrome of the left hand. He may return to work

, Letter from Dr. Andres Taleisnik, addressed to Ms. Benson at Gates McDonald.

This follows, as you recall from our numerous discussion by telephone, the applicant contacted our office to cancel surgery scheduled for 6:30 AM on . Doctor's office has spent considerable time attempting to determine if the applicant would in fact have surgery or not and then attempting to determine why it has been postponed. These inquires have not been successful. As you may recall, your office has instructed our office to bill for no shows for surgery given the extremely short notice for cancellation. Obviously, the time cannot be utilized.

, Off Work Notice from Gateway Regional Medical Center, apparently Dr. Chuan Nguyen.

Applicant has been taken off work because of increased symptoms of pain, discomfort due to overuse of the hands while working within his restrictions per Dr. Taleisnik. Off work till to allow his symptoms to decrease.

, Letter from the applicant addressed to

Applicant was writing due to serious concerns he has as the way he has been neglected. He states he has not been able to see workers comp physician regarding his concerns since . He has been to treating physician Dr. Gupta on two occasions, but was not examined because Gates McDonald did not provide the necessary paper work, even after it had been determined that this particular doctor had been assigned as my "treating physician." He further states that he has

incurring unnecessary pain and discomfort because you guys are constantly dropping the "ball" by not allowing me to have my concerns address in a timely manner. Applicant reports that he has sent faxes and voice mails to _____, who asked him to send information regarding his rights etc. He goes on to state that his personal doctor and psychologist can allow him for appropriate method to relieve his ongoing aches and pains. From _____ his pain and discomfort dropped dramatically. When he returned to work _____, he has increased dramatically again.

PTP Progress Report from Dr. Ranjan Gupta.

Applicant is reporting very severe hyper sensitivity right upper extremity. He was taken off work by his primary care physician, which he states has helped some quite a bit. However, he states his symptoms are returned and quite disabling. He underwent electrodiagnostic studies with Dr. Hakimian. Apparently his study showed evidence of a severe carpal tunnel syndrome bilaterally, however, there was no comment as to whether or not there was persistent slowing relative to previous decompression. Handwritten note to the side please address Dr. Gupta. On exam, clear grip strength on the right is 90/90/90, on the left 100/100/100. Wrist extension 80/80, flexion 70/85, radial deviation 20/20, ulnar deviation 30/30. He reports on direct palpation that he is very hyper sensitive. When Dr. Gupta touched the applicant's hands, there is evidence of hyperhidrosis and evidence of increased motion in both hands in the median nerve distribution. He was sensitive to touch. MRI apparently of bilateral wrist from _____ was reviewed.

Diagnosis: Bilateral carpal tunnel syndrome.

Plan is to request updated electrodiagnostic studies to pay particular attention to whether or not there is any persistent entrapment or any nerve injury present after carpal tunnel releases. This study will help to determine whether or not nay surgical intervention will be possible. After the study, he will return and then we will pursue lidocaine injection test. Modified duties. No keyboarding or handwriting with right upper extremity. Must take 10 minute breaks after 50 minutes regular work

with left upper extremity.

PTP Progress Report from Dr. Ranjan Gupta.

He has not received authorization yet for repeat electrodiagnostic studies. He has questions about possible injections as his hands are quite painful. Grip strength on the right is 80/80/88, on the left 100/95/110. Again there is hyperesthesia in both hands in the median nerve distribution.

Diagnosis: Bilateral carpal tunnel syndrome, possible reflux sympathetic dystrophy.

Applicant is given injection to each hand of 1 cc Kenalog 40 mg and 1 cc lidocaine. Modified duties.

Supplemental Report from Dr. Ranjan Gupta.

Dr. Gupta notes that he has not made applicant permanent and stationary as our report would indicate. He requires and request treatment for both hands. This is Dr. Gupta's understanding that he has received authorization to have Dr. Gupta as his primary treating physician. As such he has not reached MMI. Modified duties are continued.

PTP Progress Report from Dr. Ranjan Gupta.

Applicant states prior injections helped markedly improve his symptoms bilaterally. However, they have returned on both sides. Electrodiagnostic studies have been denied as they were performed in April. On exam today grip strength on the right is 115/105/110, on the left 113/105/105. He has normal range of motion of cervical spine, bilateral shoulders and elbows. Wrist extension 50/80, flexion 70/85. He has digital motion.

Diagnosis: Possible recurrent carpal tunnel syndrome versus neural injury.

Dr. Gupta once again request authorization for electrodiagnostic studies. He has had positive response objective treatment of injections to both hands.

Electrodiagnostic Study from Dr. Mozaffar at UCI.

Impression: Abnormal study.

There was evidence of residual demyelination in the median nerves bilaterally though it can be determined based on this study alone whether this demyelination was related to nerve damage occurring prior to or after the prior carpal tunnel surgeries. In addition, there was evidence of mild denervation in the right cervical paraspinal muscles. Clinical correlation was suggestive.

EMG diagnosis.

Carpal tunnel syndrome.

Examination Report from Dr. Ranjan Gupta.

Original electrodiagnostic study show evidence of abnormal exam with evidence of fibrillation potentials and there was evidence of demyelination whether it is nerve damage or occurring prior to or after carpal tunnel surgery. There is no way to differentiate between the two. Furthermore the applicant also has had prior MRIs done of his right shoulder, which showed evidence of partial thickness rotator cuff tear. Left shoulder showed a small full thickness rotator cuff tear. On exam today, grip strength on the right is 145/145/135, on the left 130/125/125. There is near full range of motion of both shoulders with weakness with external rotation bilaterally left greater than right. Normal range of motion of elbows and wrist. He reports hypersensitivity to both hands.

Diagnoses:

1. Bilateral recurrent carpal tunnel syndrome versus possible

persistent neurological deficits.

2. Bilateral rotator cuff pathology.

At this point, the applicant would like to discuss this with his wife as the appropriate time point when surgery can be performed.

Supplemental Report from Dr. Ranjan Gupta.

Applicant was seen today. He has been seen by Dr. Bhatia in the past and has numerous symptoms associated to his left shoulder, low back, neck, and hands. He presents today for evaluation of left shoulder, which is bothering him quite significantly. He has had some intermittent therapy. On exam today, grip strength on the right is 40/80/80, on the left 80/85/60.

He was able to forward flex 160/160, abduct 140/80. On the left side with his arm abducted 80 degrees, he externally rotates 40 degrees and internally rotates 20 degrees. On the contralateral side, he is able to abduct 90 and has ER and IR 90 degrees each direction. Normal range of motion of elbows and wrists with hypersensitivity both hands and also sensation.

Diagnoses:

1. Left shoulder adhesive capsulitis.
2. Bilateral carpal tunnel syndrome.
3. Cervical DDD and foraminal stenosis.
4. Lumbar DDD with foraminal stenosis, back pain and leg pain.

Dr. Gupta has discussed with the applicant in detail that he has significant frozen shoulder at this point and in need to have three rehabilitative services to improve his potential outcome. As his symptoms on both sides, we will request authorization for left as well as right as of now. He is to follow up with Dr. Bhatia within the next four weeks. Dr. Gupta was going to discuss the cervical as well as lower back. He will be seen in four weeks to see how much progression he has made for his left shoulder. Continue modified duties. Physical therapy ordered.

, Work Status Notice.

Modified duties are limited lifting and carrying up to 10 pounds. Limited pulling and pushing up to 10 pounds. No keyboarding and writing with the right hand. Stretch left hand every 15 minutes.

, PTP Supplemental Report from Dr. Ranjan Gupta.

Applicant is currently been seen Dr. Bhatia for his lumbar problems. Currently, his shoulders and back have not been authorized however, he has failed continue conservative therapy for carpal tunnel surgery and he had a positive lidocaine injection test on both sides. He would like to have surgery on the left. Exam shows altered sensation in the median nerve distribution. Well-healed surgical scars with altered sensation on the median nerve distribution. Grip strength on the right is 115/100/105, on the left 80/90/80.

Diagnoses:

1. Bilateral carpal tunnel syndrome left greater than right.
2. Bilateral rotator cuff tendinitis.
3. Cervical SS.
4. Lumbar SS.

Operative Report from Dr. Ranjan Gupta. UCI.

1. Revision of left carpal tunnel release.
2. Left wrist flexor tenosynovectomy.
3. Application of neural tube around the median nerve at the left wrist.

Diagnosis: Recurrent left carpal tunnel syndrome.

In findings, there is extensive scar tissue in the area of the left carpal tunnel and also extended distally and proximally into the palmar fascia and fascia of the forearm, respectively. There were extensive adhesions

surrounding the left median nerve within the carpal tunnel and proximal to the wrist.

Operative Report from Dr. Nitin Bhatia, UCI.

Procedures:

1. Posterior spinal fusion at L4 to S1.
2. Posterior interbody fusion L4-L5.
3. Posterior interbody fusion L5-S1.
4. Posterior spinal decompression including laminectomies, vasectomies, and left trans facet decompressions of L4 to S1.
5. Posterior spinal osteotomy of L4, L4.
6. Posterior spinal instrumentation of L4 to S1, bilateral.
7. Application of biomechanical devices of L4-L5 interspace, L5-S1 interspace.
8. Autologous bone graft.
9. Morselized allograft bone graft.
10. Left autologous iliac crest bone graft.
11. Intraoperative fluoroscopy and spinal cord monitoring.

Diagnoses:

1. Lumbar intervertebral disk disease.
2. Lumbar spinal stenosis.
3. Bilateral lower extremity radiculopathy and low back pain.

Supplemental Report from Dr. Ranjan Gupta.

Applicant has age , status post revision of left carpal tunnel release, and spine surgery on . He reports while his hand and back were improving, he is still having problems with the shoulder. Left shoulder has been quite troublesome. Grip strength on the right is 90/95/85, on the left 35/30/25. He has pain with forward flexion and abduction on the left. Surgical scar on the volar aspect is well healed but still sensitive to touch.

Diagnoses:

1. Left carpal tunnel syndrome status post revision.
2. Left shoulder impingement syndrome with rotator cuff tendinitis/partial-thickness rotator cuff tear.
3. Lumbar spine surgery.

The applicant is requesting left shoulder surgery as this has been bothering him. Please note that the applicant's bilateral hand problems are industrially approved. Therefore, he is TTD. We are cognizant that he had his lumbar spine surgery on his own personal insurance that in no way, shape, or form, and effect that he has accepted industrial related claims involving both of his hands.

Orthopedic AME from Dr. Lynn Edward Wilson.

Last report from Dr. Rosen is [redacted], [redacted]. Dr. Rosen had no opinion regarding issues of injury AOE/COE. Applicant is status post lumbar laminectomy, [redacted], left carpal tunnel release, [redacted], and left carpal tunnel release, [redacted], [redacted]. Both operative reports are reviewed. Applicant also has evidence of severe DDD with cervical spine. He would like to proceed with surgical intervention. Job analysis was reviewed in detail. Applicant asked Dr. Rosen's comment on the operative reports from [redacted]. He asked Dr. Rosen if he had made decision for his findings today and if he could please forward them in allotted timeframe because all of delays have caused hardship to him and his family. On exam today, cervical spine shows flexion to 40 degrees, extension 40 degrees, rotation 55 degrees to the left and 50 to the right. He has positive Spurling sign bilaterally. There is muscle guarding and asymmetric motion of the cervical spine with focal tenderness between the posterior spinous processes. Shoulder shows Hawkins, Neer, and supraspinatus testing negative. No shoulder click or AC joint pain. Yergason test is normal. Shoulder flexion 160/160, abduction 160/160, adduction 40/40, IR 60/60, ER 80/80, extension 40/40. Normal painless range of motion bilateral elbows and forearms. Digital motion bilaterally is full. No atrophy of intrinsic or thenar muscles. Tinel's sign, Allen's, Finkelstein's, Phalen, and Foreman's tests

are negative.

Two point discrimination testing was negative in the metacarpal trapezoidal joint of both hands. No swelling or nodules. Grip strength on the right is 55, 51, and 50 kg, on the left 44, 41, and 40 kg. Arm and forearm measurements equal bilaterally. Dorsiflexion 65/65, palmar flexion 70/70, ulnar deviation 40/40, radial deviation 20/20. Finger and thumb exam intact. He has 5/5 strength to the upper extremities bilaterally. 2+ DTRs. He also has bilateral index finger, middle finger, and thumb numbness and pain and subjective weakness in the arms especially in the deltoids and wrist function. Gait is normal. He is able to toe and heel walk. There is surgical scar in the midline of the lower back from L4 to the sacrum, nontender. Lumbar flexion 30 degrees, extension 10 degrees, rotation 10 degrees bilaterally. There is minimal focal tenderness. Negative SLR 70 degrees bilaterally both sitting and supine. Thigh and calf circumference equal bilaterally. Motor strength 5/5. Normal range of motion of bilateral hips. Knee exam unremarkable. DTRs are 1+ and symmetric in lower extremities. Sensory exam intact.

Impression:

1. Cervical DDD with spinal stenosis and right greater than left radiculopathy, C5-C6, C6-C7.
2. Lumbar DDD L4 to the sacrum with postop status, lumbar fusion L4 to the sacrum.
3. Recurrent carpal tunnel syndrome with double crush syndrome and persistent radiculopathy, bilateral upper extremities.
4. Bilateral shoulder pain with tendinopathy, supraspinatus and AC arthritis.

In discussion, applicant is alleging injury CT through to spine, both upper extremities, and psyche. His claim has been denied. The claim as recently amended to react to , continuing. This alleges injuries to both upper extremities, hands, shoulders, cervical and thoracic spine, and lumbar spine, and psyche. Date of injury of February 2004 alleges injury to the back but this is denied and will be reconsidered based on Dr. Wilson's review. Also, date of injury of . alleges to injury, shoulders, and hands. In discussion, clearly there is a longstanding history of chronic

problems involving the neck, shoulders, and lower back with headaches of muscle tension type dating back to . There have been multiple medical records reviewed both in the applicant's personal positions and it is clear he has significant problems involving DDD in the neck and lower back. He has now undergone surgery to the lumbar spine, carpal tunnel release on two occasions with persistent radiculopathy. He also has DDD and history of other severe involving the cervical spine, two levels. Dr. Wilson has changed his opinion regarding the issue described in his report that he had prepared on that day after reviewing the job description submitted on by the way of RU-91.

In his opinion, the applicant sustained cumulative trauma from * and continuing as it relates to cervical spine, lumbar spine, hands, and shoulders. Dr. Wilson has also changed his issue of apportionment based on extensive review of job description and taking a consideration of actual job duties.

He has now had the opinion with 50% current disability for cervical spine and 50% of the lumbar spine is attributable to industrial causation in the form of cumulative trauma. 50% is attributable to non-industrial causation including previous motor vehicle accident of 1985, as well as activities of daily living including history of weightlifting and degenerative changes.

Applicant has neck problem that was severe and he went to Anaheim Memorial Hospital in approximately because his neck pain was killing him. This was in part due to nonindustrial MVA from industrial aggravation from CT. Dr. Wilson has now had the opinion that 100% of current disability for hands and wrist are caused from double crush syndrome from the cervical spine as well as bilateral carpal tunnel syndrome which in large part has caused by repetitive use of the hands and wrists due to his activities at work began . It appears that he has significant problems with cervical and lumbar spine for which he has required surgery for the lumbar spine. Although, he was declared permanent and stationary because at that time, he did not wish to undergo further carpal tunnel surgery, Dr. Wilson believes in retrospect that his completion permanent and stationary then and he would not remain permanent and stationary until when Dr. Wilson estimated

that he would be sufficiently recovered from carpal tunnel surgery to be considered permanent and stationary. Future medical should be authorized for the applicant's cervical spine and lumbar spine on a lifetime basis. He does not require surgery on his shoulder but may require therapeutic exercises and medications. He should have as access to pain management physician for his neck and lower back problems. He should be authorized surgery in the future for his neck if he elects to do so. Lumbar spine disability has given him 13% whole person impairment, cervical spine 15% whole person impairment, bilateral carpal tunnel syndrome 5% to each upper extremity. Applicant will continue to be TTD until _____ for the left hand which is industrial and compensable.

Examination Report from Dr. Nitin Bhatia.

Applicant continues with left greater than right-sided neck pain which is getting worse. Pain is radiating to both shoulders. He is much improved after lumbar surgery.

Diagnoses:

1. Status post L4 to S1 posterior decompression and instrumented fusion, doing well.
2. Cervical DD with foraminal stenosis.

At this point, he is to continue physical therapy and may increase his weightlifting approximately to 30 pounds. He is very happy with the outcome of his lumbar spine. He is given a prescription for Vicodin. He will wait workers comp approval for cervical surgery.

Examination Report from Dr. Ranjan Gupta.

Applicant has positive Hawkins and Neer sign on the left shoulder.

Diagnoses:

1. Bilateral shoulder impingement syndrome left more than right.
2. Bilateral carpal tunnel syndrome status post revision of left carpal

- tunnel release.
3. Status post L4 to S1 posterior decompression and instrumented fusion.
 4. Cervical DDD and foraminal stenosis.

Applicant continues to see Dr. Bhatia for his lumbar and cervical spine. Awaiting authorization for left shoulder surgery. Applicant is requested as benefits be continued as well as being paid during postop period of time.

X-Rays of Left Shoulder, Two Views from UCI.

Essentially unremarkable. Left hand, three views, unremarkable.

Operative Report from Dr. Ranjan Gupta

1. Left shoulder diagnostic arthroscopy.
2. Left shoulder subacromial decompression.
3. Left shoulder extensive debridement.

Diagnosis:

Left shoulder pain.

Examination Report from Dr. Nitin Bhatia.

Applicant is complaining of bilateral sided neck pain, left greater than right. On exam, normal gait. He is able to heel walk and toe walk and heel-to-toe walk. He has 40% loss of range of motion of the cervical spine. Increased pain with extension and lateral flexion bilaterally. Mild-to-moderate paraspinal muscle spasm and cervical spine trapezial muscles. Lumbar incision is well healed. He has full range of motion of lumbar spine without pain. He has 4/5 muscle strain, left intrinsic hand muscles. Negative Spurling, negative Hoffman sign bilaterally. Negative SLRs bilaterally. He reports limited range of motion of left shoulder and wrist. Incision is well healed. He reports hypersensitivity to touch in the left shoulder.

Diagnoses:

1. Bilateral shoulder impingement syndrome left more than right.
2. Bilateral carpal tunnel syndrome status post revision of left carpal tunnel release.
3. Status post L4 to S1 posterior decompression and instrumented fusion.
4. Cervical DDD and foraminal stenosis.

Plan is for MRI of the cervical spine.

Supplemental Report from Dr. Ranjan Gupta.

Applicant is undergoing therapy and doing reasonably well. He still has neck and low back pain but doing okay with it. Grip strength on the right is 80/65/60, on the left 45/40/30. He has some mild weakness with internal rotation. Near normal range of motion with weakness with extreme motion.

Diagnoses:

1. Left shoulder impingement syndrome with rotator cuff tendonitis.
2. Carpal tunnel syndrome.
3. Cervical spondylosis with radicular symptoms.
4. Lumbar spondylosis with radicular symptoms.

Applicant can continue with formal therapy as he is making strides. He is to the strengthening type activities. He remains TTD. Again, no weight or medications noted.

Supplemental Report from Dr. Ranjan Gupta.

Applicant is status post left shoulder surgery, making good strides. He is near full range of motion. He is waiting MRI of the cervical spine. Continue therapy.

Occupational Therapy Notes at UCI.

Status post left shoulder subacromial decompression and extensive debridement from Dr. Gupta.

, Supplemental Report from Dr. Ranjan Gupta.

Applicant has still not had MRI of the cervical spine as he needs IV sedation for this.

Diagnoses: Unchanged.

Grip strength on the right is 65/45/55, on the left 50/35/50. He has pain with positive Spurling. Decreased impingement sign and well healed surgical scars on left shoulder. He remains TTD.

MRI of the Cervical Spine, page 1, from UCI.

1. There was interspace narrowing and anterior osteophyte at C5-C6, C6-C7, and C7-T1.
2. There was a broad-based disk osteophyte at C5-C6 which narrowed the canal and cause mild right-sided cord compression.
3. There was a broad posterior disk osteophyte at C6-C7 which narrowed the canal and caused borderline cord compression.
4. There was a 2-mm disk osteophyte paracentral to the left at C7-T1 which does not appear to significantly affect the canal or neural foramen.
5. There was bilateral moderate narrowing at C3-C4 neural foramina.
6. There was bilateral moderate narrowing at C5-C6 neural foramina.
7. There was moderate narrowing of the left C6 neural foramen.

Supplemental Report from Dr. Nitin Bhatia.

When last seen, he was sent to obtain an MRI of the cervical spine. Blood pressure today is 139/66, pulse 79, and weight should be 326 pounds. He has normal posture and normal gait. He is able to toe walk and heel walk and has had slightly difficult with heel-to-toe walk. He had 40% loss of range of motion of the cervical spine with increased

pain and extension of lateral flexion bilaterally. Mild-to-moderate paraspinal muscle spasm in the cervical spine and trapezius muscles bilaterally. There is good range of motion of the lumbar spine without pain. There is 4/5 muscle strength in the left biceps and intrinsic hand muscles, otherwise 5/5. Negative Spurling's bilaterally. Negative SLRs. There was a positive Hoffman sign on the left and negative on the right. DTRs are 2+ in upper and lower extremities throughout. Sensation to light touch was increased in the ventral aspect of the left hand.

Diagnoses:

1. C5-C6 and C6-C7 cervical spinal stenosis with radiculopathy.
2. Degenerative disease of the cervical spine.
3. Status post L4-S1 posterior lumbar decompression, doing well.
4. History of left rotator cuff repair.
5. History of left carpal tunnel release.

Applicant sent for preop clearance for cervical spine surgery.

Supplemental Report from Dr. Ranjan Gupta.

Applicant is scheduled to have cervical spine surgery with Dr. Bhatia on November 3, but this has been denied and there are lost as to why. At this point, he remains TTD relative to industrial related pathology of the cervical spine. This has been documented and seen by the chief of spine surgery at UCI, Dr. Bhatia who concurs and has recommended operative intervention.

Cervical Spine X-Ray Series from Dr. Burns.

No significant intervertebral change, anterior fusion C5 to C7 with stable appearing mild lucency around the C5 and C6 fixation screws.

Supplemental Report from Dr. Ranjan Gupta.

Applicant underwent cervical spine surgery on He recently started physical therapy less than a week ago. He notes he has

some intermittent symptoms of numbness and tingling, but is doing reasonably well. Both shoulders have full range of motion.

Supplemental Orthopedic AME Report from Dr. Lynn Edward Willson.

Multipage list of previously reviewed records noted including operative report of cervical spine. On exam, there is limited range of motion of cervical spine measured by dual inclinometers. He has flexion to 40 degree, extension 40 degrees. Rotation 55 degrees to the left and 50 degrees to the right. There is a 1-inch surgical left-sided transverse scar at the level of C5-C6 and well-healed on the left side of the neck was cosmetically acceptable without keloid and nontender. Negative Spurling's bilaterally. He had muscle guarding and asymmetric motion of the cervical spine with focal tenderness between the posterior spinous processes. Of note, right shoulder healed arthroscopic and skin incisions (?) should be left. No atrophy or swelling noted.

Impression:

1. Cervical DDD with spinal stenosis, right greater than left radiculopathy C5-C6 and C6-C7.
2. Lumbar DDD L4 to the sacrum of postop status of lumbar fusion L4 to the sacrum.
3. Recurrent carpal tunnel syndrome with double crush syndrome and persistent radiculopathy, bilateral upper extremities.
4. Bilateral shoulder pain with tendinopathy, supraspinatus, and AC arthritis.
5. Anterior cervical decompression of C5 to C7 including partial corpectomies of C5, C6, and C7 with discectomy of C5-C6 and C6-C7.
6. Radiculopathy of left upper extremity.
7. Anterior cervical fusion of C5 to C7.
8. Anterior cervical instrumentation C5 to C7.
9. Application of distraction device to C5 corpectomy site, C5 and C6 discectomy site, C6 corpectomy site, C6-C7 discectomy site and C7 corpectomy site.

10. Structural allograft bone graft.
11. Intraoperative fluoroscopy.
12. Intraoperative spinal cord monitoring.
13. Use of intraoperative microscope.
14. Lumbar interbody fusion L4 to sacrum.
15. Recurrent carpal tunnel syndrome with median neuropathy, bilateral wrist.
16. Postop status arthroscopy for impingement syndrome.

Applicant is permanent and stationary for rating purposes,

1. He is precluded from heavy work with respect to the cervical spine. Bilateral hands and wrists preclude prolonged repetitive fine manipulation, movements, and preclude repetitive forceful grasping and repetitive heavy lifting. Lumbar spine precludes applicant from heavy lifting, repetitive bending and stooping, and prolonged sitting and standing. Calculated WPI was 43%. We will defer issues of sleep disorder to psychiatry and AME.

2. Cervical Spine X-rays Series from Dr. Jimmy Shih.

1. No significant interval change from _____
2. Frontal and neutral lateral views of cervical spine re-demonstrate anterior fusion C5 through C7 with anterior metallic plates and screws.
3. C5-C6 and C6-C7 disk spaces were noted. Alignment was similar to prior studies and no evidence of hardware failure.

3. Lumbar Spine X-Ray Series from Dr. Jimmy Shih.

Stable L5-S1 posterior fusion with no evidence of hardware failure.

4. Notice of Release to Return to Work without Restrictions regarding date of injury _____ by Dr. Myron Nathan.

5. Supplemental Report from Dr. Ranjan Gupta.

Applicant was recently seen by Dr. Bhatia on . He states injection in his wrist had helped him significantly. He is making good strides and he is willing to return to work.

On exam, he is ambulating without a cane. Grip strength on the right is 50/45/45, on the left 45/40/45. Good motion of the neck, shoulders, and elbows.

Diagnoses:

1. Bilateral shoulder pain with impingement syndrome.
2. Bilateral carpal tunnel syndrome.
3. Cervical spondylosis with radicular symptoms.
4. Lumbar SS.

Plan is for modified duties and no pushing, pulling or lifting greater than 5 pounds, bilateral upper extremities. No overhead activities. Limited standing and typing for the next 30 days or so. Again, no history on injections reference.

Interactive Process Meeting Letter. by

Addressed to the applicant regarding interactive process meeting. As follows, you have been off work since . You recently see the notice of permanent restrictions dated from Insurance, (XXXXX workers comp claim administrator). Apparently, restrictions for cervical spine preclude heavy work. Bilateral hands and wrists preclude prolonged repetitive fine manipulation movements, repetitive forceful grasping and repetitive heavy lifting. Lumbar spine precludes heavy lifting, repetitive bending and stooping, prolonged sitting and prolonged standing. Meeting is scheduled on .

Supplemental Report from Dr. Ranjan Gupta.

Applicant is looking quite well. He has lost pounds since last visit. He feels well. His pain is distributed in the medium nerve distribution,

still increased hypersensitivity, difficulty walking around the house, difficulty with the shoulders. Exam shows grip strength on the right 40/40/40, on the left 30/40/40. He is doing quite well. The radial, median, and ulnar nerve distribution is intact with altered sensation in the median nerve distribution.

Diagnoses: Unchanged.

Modified duties are listed, but he is scheduled to meet with his adjustor and his work in the middle of September, remained TTD.

Human Resources' Note from

Same modified duties. The interactive process meeting took place on (). Initially, applicant expressed interest in working at the () office. However, it was discussed and ultimately they agreed that the order of control () unit would be more appropriate. Return to work day apparently () Several pages of job descriptions.

Supplemental Report from Dr. Ranjan Gupta.

Applicant is scheduled to start work on () no change.

Supplemental Report from Dr. Nitin Bhatia.

Applicant states he returned to work on (). After that, he developed gradual increase in leg pain which became severe this past (). Pain occurs in the posterior aspect of the cervical spine and the paraspinal muscles radiating to the trapezius muscle bilaterally, right more than left. Before he returned to work, he was off of all pain medications and now he started back on Vicodin as well as tramadol and Valium to help him deal with the pain. His current job duties involved working on computers as well as moving up and down excessively throughout the day. Exam shows he has normal posture and gait. Again, there is slight difficulty with heel-to-toe walk. No ataxia. There

is TTP of the cervical paraspinal muscles, right greater than left, TTP of the trapezius muscles bilaterally, right more than left, and TTP of the lumbosacral junction and cervicothoracic junction. Muscle strength is 5/5 upper and lower extremities bilaterally. Negative Hoffman sign bilaterally. Negative finger escape bilaterally. Negative SLRs. Radiographs of the lumbar spine reviewed show no apparent hardware complications and the fusion was solid. X-rays, four views of the cervical spine including AP, lateral extension, and forward flexion views show increased motion with flexion, extension views at C5-C7. Applicant appears to have increased intervertebral disk disease at C7-T1.

Diagnoses:

1. Status post L4-S1 posterior spinal decompression, interbody fusion, and instrumentation, doing well.
2. Status post C5-C7 ACDF, with possible pseudoarthrosis and neck pain.
3. Lumbosacral pain.
4. At this point, the fusion appears to be solid at L4-S1 levels.

His lumbosacral junction pain may be related to lumbar strain at this time. As per cervical spine, there is increased motion with flexion and extension views which indicate possible pseudoarthrosis. We will recommend CT scan. At this point, he may continue keep working and continue restrictions per AME. Refills of Valium, tramadol, and Vicodin.

, Cervical Spine X-Ray Series, 2-3 Views, from Dr. Phan.

Unstable appearance status post fusion. Fusion was progressive, but incomplete. Mild degenerative disease at C5-T1. Alignment, minimal grade 1 anterolisthesis C4 and C5 of 1 mm of flexion becomes 1 mm retrolisthesis and extension was demonstrated on the same day flexion extension films.

Lumbar Spine X-Rays Series from Dr. Son Phan.

Stable appearance.

Supplemental Report from Dr. Ranjan Gupta.

He has lost even more weight since being seen. He is doing quite well. On exam, grip strength on the right is 25/30/27, on the left 30/25/30. Today, he has a positive Spurling sign over the neck. Well-healed scars.

Diagnoses:

1. Cervical SS.
2. Lumbar SS.
3. Bilateral shoulder pain with impingement.
4. Bilateral carpal tunnel syndrome.

Applicant is doing quite well and working with restrictions. Awaiting CAT scan apparently for cervical spine.

CT of Cervical Spine without Contrast from Dr. Raymond Kuo.

1. Postop changes status post ACDF of C5 through C7.
2. Foraminal stenosis of upper cervical levels mostly associated with bone spur formation and facet arthropathy. Endplate spurring mostly at fused levels without visible stenosis.

Supplemental Report from Dr. Nitin Bhatia.

Applicant's CT of the cervical spine from shows evidence of C5-C7 anterior cervical discectomy and fusion with no apparent hardware complications. Fusion status was unclear.

Diagnoses:

1. History of C5-C7 anterior cervical discectomy and instrumented fusion, doing well.
2. Possible cervical strain.
3. History of L4-S1 posterior spinal decompression, instrumented fusion, doing well.
4. Possible lumbar strain.

Discussion: on current CT, it is unclear what the solid fusion at C5-C6 and C6-C7. It does appear to have facet degenerative joint disease of the cervical spine. Dr. Bhatia felt the applicant's current exacerbation of pain was likely due to workstation after having ergonomically corrected. We placed off work until ergonomic workstation evaluation.

..., Supplemental Report from Dr. Ranjan Gupta.

Applicant is waiting for a new test to be developed. On exam today, there is pain in neck, limited motion of neck, shoulders, elbows, and wrists with fair amount of discomfort today, but no values given. Dr. Bhatia has requested epidural injections which Dr. Gupta concurs. He has also been given some pain medication along with muscle relaxants. Remains TTD.

, Supplemental Report from Dr. Nitin Bhatia.

Applicant is to be referred to Dr. Miller, in pain management, for possible injection therapy of the cervical spine with trigger point injections. Also recommend TENS unit for home use and home exercises as much as possible. Here, he is currently working. Unknown medications. He is awaiting ergonomic workstation evaluation.

Employer's Report of Occupational Injury or Illness for date of injury listed as

Strain, repetitive motion of wrist and hands. He was proofreading and collection list and entering check mark.

Work Status Notice, County Health Services.

Modified duties are limited lifting and carrying up to 10 pounds, limited pulling and pushing up to 10 pounds. Limited use of bilateral hands and wrists. Permanent restrictions with no stooping or bending per worker's comp. No writing or typing.

, Supplemental Report from Dr. Ranjan Gupta.

Diagnoses:

1. Status post cervical spine surgery.
2. Status post lumbar spine surgery.
3. Status post bilateral carpal tunnel syndrome.
4. Status post left shoulder arthroscopy.

In discussion, applicant states his hands at this point are unbearable and he would like to have repeat injections to each hand. Therefore, as Dr. Gupta cannot have both of his hands numb, we will inject the both hands; however, only one will have lidocaine in it. He was given 1 cc of Kenalog 4 mg and 1 cc of lidocaine into the right wrist. On the left side, 1 cc of Kenalog injected. He is going to attend the continued modified duties. Awaiting workstation evaluation.

, Doctor's First Report of Occupational Injury or Illness for date of injury listed as from Dr. Brian Capeloto.

Applicant had previous surgeries with complaints of pain and discomfort of the hands. He has tenderness of bilateral hands. Unable to use a pen.

Diagnosis: Neuropathy, cervical.

No lifting over 10 pounds and no formal exam.

, Initial Pain Management Evaluation from Lawrence Miller referred by Dr. Bhatia.

History of injury and treatment today were reviewed. Current medications are Vicodin, Diazepam, Ambien, and tramadol. On exam, he was slightly anxious with his mood. Gait was normal. Heel and toe walk with difficulty. There was cervical diminished lordosis. Diffuse posterior cervical spine tenderness, left greater than right, axial head compression positive bilaterally left more than right. Spurling's and facet

tenderness negative. Cervical lateral rotation 40/40, normal 70; lateral flexion 20/20, normal 30; extension 30 normal 60; flexion 35, normal 60. It is painful especially with extension of the left lateral rotation. Well-healed surgical scars.

There is bilateral wrist tenderness, left greater than right. No swelling noted. Shoulder abduction 160/160, forward flexion 160/160, normal 180. Internal rotation, external rotation, cross shoulder adduction, and Apley's scratch test normal bilaterally. Impingement sign is positive on the left only. Brachial plexus stretch test positive bilaterally. Normal painless range of motion of bilateral elbows with negative testing. Normal range of motion of bilateral wrist with negative testing bilaterally. Grip strength on the right is 25/25/27, on the left 20/20/18. There was dysesthesias to pinwheel testing on the left. Median nerve distribution distal to the wrist. Of note, upper extremity motor testing, 4/5 bilaterally throughout. DTRs are 2+ bilaterally. Lumbar spine shows diminished lordosis. Diffuse tenderness throughout. Facet tenderness negative. Piriformis test and sacroiliac test negative bilaterally. In record review is the CT scan of the cervical spine. Preop MRI of the cervical and preop MRI of the lumbar spine from _

Impression:

1. Status post anterior discectomy, cervical fusion, C5-C7 with persistent cervical radiculitis and pain.
2. Status post posterior L4-S1 instrumented fusion with persistent lumbar radicular pain.
3. Status post bilateral carpal tunnel release with residuals, left greater than right with probable left median neuritis.
4. Status post left shoulder arthroscopic decompression.

Authorization requested for trial of posterior cervical interlaminar epidural injections C5-C6 and C6-C7 level. Authorization was requested for lumbar epidural catheter caudal technique. Ultimately, applicant may come to spinal cord stimulation treatment.

_____, Transitional Modified Duties Note from Human Resources.

Supplemental Report from Dr. Bhatia.

Applicant has been seen by Dr. Miller. Review of systems notes a weight loss of pounds over one week due to increased work-related stress. No details. Depression also due to work-related conditions. On exam, normal posture and gait. 30% loss of range of motion of the cervical and lumbar spine.

Diagnoses:

1. History of C5-C7 anterior cervical discectomy and fusion with resolution of preop symptoms.
2. History of L4-S1 posterior spinal decompression and instrumented fusion with resolution of preop radiculopathy.
3. Work-related cervical and lumbar sprain with worsening neck and lumbar pain.

Plan is to follow up with Dr. Miller. At this point, he will be placed off work. No actual medication listed.

Physician's Statement Disability for XX Retirement from Dr. Nitin Bhatia.

History of cervical and lumbar spine surgeries. Applicant is not permanently disabled from this occupation. From his ergonomic workstation, reduced stress, no sitting or standing greater than half an hour to one hour at a time, no pushing, pulling, or lifting greater than five to eight pounds and no repetitive motions.

Supplemental Report from Dr. Ranjan Gupta.

Applicant was placed TTD due to continued discomfort and extreme pain. Hopefully, he and his employment and attorney can come up with a reasonable solution until the applicant is not at this level of pain.

Physician's Statement for XX retirement from Dr. Ranjan Gupta.

He has work restrictions. He is not permanently disabled from his occupation.

Agreed Medical Examination from Dr. Lynn Wilson.

Several pages are missing. Multipage record review is noted.

Diagnoses:

1. Cervical SS syndrome, current superimposed on previous anterior cervical fusion C5 through C7 with instrumentation.
2. Postop status, subacromial decompression, left shoulder, he underwent left shoulder arthroscopic surgery.
3. Post status carpal tunnel releases, bilateral, with revision of left hand carpal tunnel release. Bilateral carpal tunnel releases by Dr. Taleisnik and repeat carpal tunnel release by Dr. Gupta.
4. Anterior cervical decompression C5-C7 including partial corpectomy C5, C6, and C7 with discectomies at C5-C6 and C6-C7, he underwent anterior cervical decompression with instrumentation C5-C6 and C6-C7.
5. Anterior cervical fusion C5-C7.
6. Anterior cervical instrumentation C5-C6 and C6-C7 with structural allograft and bone graft.
7. Postop status L4 to S1 posterior decompression and spinal fusion with Dr. Bhatia on June 19, 2007.
8. Posterior lumbar fusion L4 to sacrum with residual lumbar SS syndrome.
9. Left foot bunion surgery, non-industrial, per Dr. Lyman Wilson.
10. Nonorthopedic diagnoses including chronic stress syndrome, deferred to psychiatric AME.

In discussion, there are numerous periods of TTD which previously were cited in this report based on treating orthopedic physicians Dr. Gupta and Dr. Bhatia, which have been adopted and are reasonable given that they were there and have the opportunity to actually examine the applicant and had much confirmation going on to find than Dr. Wilson has there.

Total whole person impairment is 45% on an orthopedic basis.

... Electrodiagnostic Study from Dr. Anthony Ciabarra.

There was no evidence of cervical radiculopathy or generalized polyneuropathy. Page #2 is difficult to read. Mononeuropathies of the wrist would consistent with clinical diagnoses of carpal tunnel syndrome.

Supplemental Report from Dr. Nitin Bhatia.

Applicant is now complaining of increasing lower back pain and radiating pain to the lower extremities in the posterolateral aspect of the calf. He also reports his legs are buckling. Initially, it was only the left leg, but now the right leg is involved. General examination is benign. Gait is normal. He has guarded motion of the cervical spine with positive Spurling's bilaterally. He has 4/5 muscle strength in upper extremities throughout bilaterally. Negative Hoffman's sign bilaterally. 5/5 muscle strength in lower extremities. Negative SLRs.

Diagnoses:

1. History of C5-C7 anterior cervical diskectomy and fusion.
2. Worsening neck pain and diffuse upper extremity symptoms including weakness.
3. History of L4-S1 posterior spinal decompression and fusion.
4. Worsening lower back pain and lower extremity radiculopathy and subjective weakness.

Plan is to obtain an MRI of the cervical spine and lumbar spine with and without contrast to reevaluate spinal cord and nerves. Additionally, he will be referred to neurologist. We will recommend him to Headache and Pain Institute for evaluation of worsening neck and lower back pain. He remains off work.

Cervical Spine X-Ray Series, Multiple Views, from Dr. Yoshioka.

Stable exam. No acute hardware failure or spondylolisthesis.

Employer's Statement of Disability for XX Retirement.

Injury date listed here is _____ Notation regarding _____
_____, _____. Five-day suspension without pay, from _____ 5 to
_____. No details. _____ file filed for retirement
apparently effective _____. Additional series of previously
reviewed notes regarding work accommodations, work restrictions, and
job analysis.

Supplemental Report from Dr. Ranjan Gupta.

Applicant is scheduled to undergo an MRIs of cervical spine and lumbar spine and follow up with Dr. Bhatia. Most recent electrodiagnostic study showed residual bilateral carpal tunnel syndrome. He has some questions regarding this. Again, examination on the right shows grip strength 30/20/25, on the left 30/30/25. He has pain with issues with grasping and grabbing type of activities. Normal gait and normal posture.

Diagnoses:

1. C5-C7 anterior cervical discectomy and fusion.
2. Worsening neck pain and diffuse upper extremity symptoms and weakness.
3. History of L4 to S1 posterior spinal decompression and fusion.
4. Worsening low back pain.
5. Bilateral shoulder pain.

MRI of Cervical Spine with and without Contrast at Anaheim Regional Medical Center, Dr. Roy Dorman.

1. Disk osteophyte, asymmetric to the right at C4-C5 that produced moderate spinal canal narrowing and coming close to possibly just touching the ventral surface of the spinal cord.

2. Postop changes were present at C5-C6 and C6-C7 which create some artifact.
3. Other findings as described.

At C4-C5, there was disk osteophyte, asymmetric to the right which narrows moderately the spinal canal and efface the ventral thecal sac coming close to and possibly just touching the ventral surface of the spinal cord. On postgadolinium images, there was some enhancement in this region suggesting some granulation tissues. C6-C7 again noted was postop changes. There were some unconvertible osteophytes, especially on the left with mild left neuroforaminal stenosis.

MRIs of Lumbar Spine with and without Contrast, by Dr. Roy Dorman.

1. No recurrent disk protrusion was seen.
2. Status post laminectomy at L4-L5 and L5-S1 with orthopedic hardware which degrades the quality images to some extent. Some amount of enhancing granulation tissue was present at surgical site, L5-S1. No obvious recurrent disk herniation identified.

Letter of Treatment and Medical Status from Dr. Richard Paicius.

The applicant was referred for initial consultation here on [redacted]. He had complaints of pain in his neck, with radiation to his throat and hands as well as low back pain with radiation to his legs. At that visit, he was started on Cymbalta and advised to increase his physical activity. I requested for epidural steroid injection in C5 and C7 bilaterally as well as L5-S1, cath caudal bilaterally. Discussion regarding adding prescription for Lyrica was postponed for following visits. Applicant was seen in the office again on [redacted]. He reported he was working on his walking and increasing his ADLs with slow progress. He found some benefit with Cymbalta. He was then started on Lyrica. ESI procedures were pending. On [redacted] the applicant underwent ESI both at the cervical and lumbar spine levels. On followup in the office on [redacted], he noted 70 to 75% reduction in pain with

increased range of motion of the cervical spine and 70% reduction in pain in the lumbar spine/legs. He reported that he continued to try to increase his ADLs. He was given refill on Cymbalta 60 mg, Lyrica 50 mg with instructions to titrate up to 75 mg of Lyrica. He was just continued on hydrocodone.

Supplemental Report, Dr. Ranjan Gupta.

History: He is a very pleasant man who unfortunately has consistent symptoms and pain, mainly in the wrists and his forearms at this point. Vital signs are stable but not listed. Grip strength on the right is 20/20/20 and on the left 25/20/20. There is reasonable range of motion of the shoulders, elbows, and wrist but he does have pain with resisted forearm pronation and resisted wrist flexion and extension.

Diagnoses:

1. C5-C6 anterior discectomy and fusion.
2. Worsening neck pain, diffuse upper extremity pain and weakness.
3. History of L4-S1 posterior spinal decompression and fusion.
4. Worsening low back pain.
5. Bilateral shoulder pain.
6. Bilateral carpal tunnel syndrome.
7. Bilateral lateral epicondylitis.

Treatment Plan: The applicant is never going to be able to return to level of work that he was in the past. He is appropriate for medical treatment due to multiple medical injuries and issues associated with cumulative trauma type disorder involving two extremities, cervical, and low back. Per his request, Dr. Gupta gives him injections to the elbow, one on each side of Celestone and Lidocaine. Follow up in two weeks.

DIAGNOSTIC IMPRESSIONS

1. Right wrist tenosynovitis.

2. Right carpal tunnel syndrome.
3. Status post right carpal tunnel release.
4. Left wrist tenosynovitis.
5. Left carpal tunnel syndrome.
6. Status post left carpal tunnel release.
7. Status post revision left carpal tunnel release.
8. Congenital cervical central canal stenosis.
9. Multilevel cervical degenerative disc disease.
- 10 Multilevel cervical facet arthropathy.
- 11 Multilevel cervical foraminal narrowing.
- 12 Status post C5 to C7 anterior decompression and fusion.
- 13 Multilevel lumbar degenerative disc disease.
- 14 Multilevel lumbar facet hypertrophy.
- 15 Status post L4 to S1 posterior decompression and fusion.
- 16 Left shoulder rotator cuff tear.
- 17 Status post left shoulder arthroscopic subacromial decompression and debridement.
- 18 Left Achilles tendon tear. (new non-work related injury).

SUMMARY

Mr. XXXXXXXX states that he developed pain in his neck, shoulders, hands, wrists and low back from his employment with the XXXXXXXX. He received treatment from Dr. Deckey, Dr. Taleisnik, Dr. Gupta and Dr. Bhatia. His treatment consisted of rest, medications, therapy, injections and surgeries.

Subjectively, he complains of pain in his neck, shoulders, hands, low back and in his left calf and heel.

Objectively, he has a well-healed surgical scar across his neck compatible with having undergone cervical spine surgery. He has loss of cervical spine motion. He has a well-healed surgical scar along the left shoulder. He has full range of motion of the shoulder without signs of rotator cuff pathology. He has slight tenderness along the right radial forearm and outer elbow. He has well-healed scars across the carpal canals. There is left thenar muscle atrophy. He reports altered sensation in his hands. He has a well-healed surgical scar along the lumbar spine. There is tenderness along the lumbosacral junction. He has decreased lumbar motion. He has evidence of a left Achilles tendon rupture.

Electrodiagnostic studies of his upper extremities showed neurodiagnostic evidence of median compressive neuropathy.

Imaging studies of the cervical spine showed multilevel cervical degenerative disc disease and congenitally short pedicles. Imaging studies of the lumbar spine showed multilevel lumbar degenerative disc disease and spondylosis. MRI of the shoulders showed partial rotator cuff tears.

INCAPACITY –

The conditions that cause Mr. XXXXXXXX' work incapacity are multilevel cervical degenerative disc disease, multilevel lumbar degenerative disc disease and bilateral carpal tunnel syndrome.

Mr. XXXXXXXX underwent surgeries to his neck and to his low back to alleviate the symptoms in those areas. He underwent surgeries to alleviate symptoms of bilateral carpal tunnel disease. He also underwent other surgeries related to his left shoulder and to his left foot over the last few years.

These conditions left him with the inability to bend,... repeatedly and with force.

As a result of these surgeries, the general conditioning of his body became reduced. I believe the combinations of degenerative changes and surgeries left him with substantially decreased stamina; this decrease in conditioning and stamina compromised his ability to work an eight-hour job.

In sum, I conclude that Mr. XXXXXXXX is unable to return work as a _____ due to the degenerative changes in his spinal column and loss of general conditioning.

SERVICE CONNECTION –

I reviewed the job description for _____ . The physical demands of this job are not overly strenuous or physically demanding. The job involves mainly sedentary and clerical work.

His prior _____ position as an _____ did involve continuous and repetitive use of his hands for sorting, lifting and carrying.

It is my opinion there is a real and measurable connection between the carpal tunnel syndrome in his hands and wrists due to his _____ employment.

I do not believe there is a measurable connection between the condition in his cervical spine and his lumbar spine to his _____ employment.

The physical demands of his job positions would not have lead to degenerative changes on the imaging studies; these changes are more likely due to the natural aging process.

RE: XXXXXXXXXXXXXXX

63

XX, 20XX

Should you have any questions, please do not hesitate to contact my office.

Very truly yours,

Jason J. Chiu, M.D.
Board Certified, Orthopaedic Surgery

Qualified Medical Examiner

JJC:lm

JASON J. CHIU, M.D.
Board Certified, Orthopaedic Surgery

1220 HEMLOCK WAY, SUITE 205
SANTA ANA, CALIFORNIA 92707
[714] 755-0224 [714]755-0578[FAX]

3816 WOODRUFF AVENUE, SUITE 100
LONG BEACH, CALIFORNIA 90808
(562) 938-8494 [562] 429-9080 (FAX)

*Sample Report
#2*

Attention:

RE:
OCC:
EMP:

CHART:

**COMPREHENSIVE ORTHOPEDIC
INDEPENDENT MEDICAL EVALUATION**

Dear Ms. :

Mr. was seen in comprehensive orthopedic independent medical evaluation in my Santa Ana office located at 1220 Hemlock Way, Suite 205, Santa Ana, California 92707, today

IDENTIFICATION

 is a -year-old (born on ,) left-handed male who stands feet inches tall and whose stated weight is , pounds.

RE: 2

HISTORY OF INJURY

filed an Application for Disability Retirement with the . He worked as a for . He was an employee of from to

states that he sustained injuries to his knees and ankles at work on ..

"I fell through an open hatch of a boat that was driverless. The boat engine was in gear and headed toward a concrete bridge abutment in Newport Harbor. I was attempting to take the engine out of gear and steer it away from the bridge."

He states that his legs did the "splits" when he fell through the open hatch of the boat. He states that he finished his work assignment that day. He reported this injury to his supervisor and

TREATMENT HISTORY

On , he saw Dr. , who he pre-designated as Primary Treating Physician for Orthopedic evaluation. He underwent x-ray examinations of his left knee. He underwent x-ray examinations of his left ankle. He underwent MRI examinations of his left knee. His treatment consisted of modified work duties, medications and physical therapy. He was released from care on

left knee symptoms grew worse after he returned to work. He underwent arthroscopic left knee surgery on . He received physical therapy to rehabilitate his post surgical left knee. He received Synvisc injections to his left knee after surgery. He also received cortisone injection to his left knee. He returned to work.

Once again, left knee symptoms grew worse when he returned to work after the left knee arthroscopic surgery. He

RE:

3

underwent x-ray examinations of both knees. Dr. recommended left total knee replacement. The surgery took place on [redacted] could not return to work at his job because of work restrictions. He chose to retire from his position with [redacted] on [redacted].

PRESENT COMPLAINT

[redacted] complains of frequent achy throbbing pain with activity in his left knee. He rates the severity of his left knee pain at 2 to 4 out of 10 at its baseline. He complains of swelling and stiffness in his left knee. He states that his ankles "*gets sore*" on some days.

Standing up/walking for 30 minutes, sitting still for 30 minutes, driving for a long period of time, bending his knees, pushing, pulling and stooping aggravate his symptoms. Taking pain medications and stretching alleviate them.

He states that he can carry out Activities of Daily Living without help.

He states that "*sometimes it is painful to walk up and down stairs.*"

PRIOR INJURY

Work-Related Injuries: [redacted], lower back injury while working for [redacted]

[redacted], right knee injury while on foot pursuit of a burglary suspect.

He underwent arthroscopic right knee surgery by Dr. [redacted] on [redacted]

[redacted], left knee injury while loading marijuana plants onto helicopter cargo net on a hillside. He stepped into a hole and twisted his left knee. he underwent arthroscopic left knee surgery by Dr. [redacted] on [redacted]

RE: 4

Continuous trauma injuries to lower back, neck, hands.

Non-work-Related Injuries:

left ankle sprain while running.

left knee injury from playing basketball. He underwent left knee arthroscopic surgery by Dr. on

PAST MEDICAL HISTORY

Major Illnesses/Serious Diseases: Knee arthritis.

Hypertension.

Surgeries:

Cholecystectomy.

Nose/throat surgery.

Left knee arthroscopic surgeries x 3

Right knee arthroscopic surgery.

Left total knee replacement.

Current Medications:

Atenolol.

Verapamil.

Lipitor.

Lexapro.

Androgel.

Aspirin.

Norco twice daily.

Flexeril, daily.

Allergies to Medication: Motrin.

FAMILY HISTORY

has brothers and sister.

RE: 5

His father is 60 years of age. His mother is 65 years of age.
There is a family history of Hypertension.

SOCIAL HISTORY

He does not smoke tobacco. He drinks wine and beer occasionally.

He is married and has 2 children.

He was born in the United States.

Highest level of education he completed was College. He has
Bachelor's of Science degree in

He never served in the military.

RECREATIONS, SPORTS AND HOBBIES

In his spare time, he enjoys fishing, hunting, wood working and going
to the gym.

OCCUPATIONAL HISTORY

1.

2.

states before becoming a in , he worked as
and . He worked in South , in , in
and in .

He states that he no longer works for . He retired on

JOB DESCRIPTION

states that as a he worked 12 hour days 3-4 days
per week on varying shifts.

RE:

6

His job duties involved supervising . He performed law enforcement, marine firefighting functions, rescue and lifesaving functions. He states that he alternated between standing, sitting and walking while doing this job. He states that he frequently lifted and carried up to 50 pounds of weight (fire equipment and safety equipment); he occasionally lifted and carried up to 100 pounds of weight. He states that he wears a Sam Browne belt with handguns. He also have desk duties as the . He rode on a patrol boat while at sea. He drove a patrol car while on land.

PHYSICAL EXAMINATION

General Appearance:

has tall stature and overweight body build.

He sits comfortably. He requires no assistance getting up and down the exam table.

He is not wearing a supportive device on the body.

He appears to be in no acute distress. He displays appropriate emotional affect.

Posture:

He stands with a level pelvis, level shoulders, and straight spine. His head is centered over the shoulders.

Gait:

His ambulates with a normal gait with good heel strike and toe off.

RE: 7

HIPS

Palpation:

There is no tenderness to palpation over the greater trochanter, anterior aspect of the groin, sciatic notch, or adductor muscles.

Range of Motion:

There is no discernible limitation or pain with movements of the hip joints.

<u>Special Testing:</u>	<u>Right</u>	<u>Left</u>
FABER/Patrick's test	Negative	Negative
Pelvic Rock test	Negative	Negative

KNEES

Inspection:

There are well healed arthroscopic portal surgical scars on both knee. There is a well healed vertical surgical scar on the anterior aspect of his left knee.

There is arthritic changes on his right knee.

There is effusion in the left knee joint.

There is no sign of prepatellar bursitis.

Palpation:

There is no increase in local temperature to touch over the knee.

He reports vague sense of pain "*inside*" his knee joints.

There is no tenderness with palpation over the medial joint line.

There is no tenderness with palpation over the lateral joint line.

There is no tenderness over the lateral femoral condyle.

RE: 8

There is no tenderness with patellofemoral compression.
There is no grinding or crepitus beneath the patella.

<u>Range of Motion:</u>	<u>Right</u>	<u>Left</u>
Extension	0°	0°
Flexion	110°	100°

<u>Deep Tendon Reflexes:</u>	<u>Right</u>	<u>Left</u>
Knee (L4)	2+	2+
Ankle (S1)	2+	2+
Clonus	Negative	Negative

Sensory:

He reports altered sensibility along the right anterior thigh to the posterolateral calf.

He reports decreased sensibility lateral to the left knee surgical incision (normal result of surgery).

<u>Motor:</u>	<u>Right</u>	<u>Left</u>
Quadriceps (L4)	5/5	5/5
Hamstrings	5/5	5/5

<u>Special Testing:</u>	<u>Right</u>	<u>Left</u>
Patellar Apprehension	Negative	Negative
McMurray Sign	Negative	
Thessaly Test	Negative	
Drawer Sign	Negative	
Valgus instability	Negative	Negative
Varus instability	Negative	Negative

RE:

9

ANKLES AND FEET

Inspection:

Visual inspection reveals no deformity, abrasion, scars, or puncture wounds.

There is no swelling noted.

Palpation:

Palpation of the feet and ankles reveal no areas of tenderness.

The malleoli, lesser toes, big toes, heels, and metatarsals are non-tender.

Ankle Range of Motion:

There is no discernible limitation or pain with movements of the ankle joints.

Motor:

Right

Left

Tibialis Anterior (L4)

5/5

5/5

Extensor Hallucis Longus (L5)

5/5

5/5

Gastroc Soleus Complex

5/5

5/5

Peroneals (S1)

5/5

5/5

Special Testing:

Right

Left

Ankle Drawer's test

Negative

Negative

Heel Rise

Negative

Negative

RE: 10

<u>Measurements:</u>	<u>Right</u>	<u>Left</u>
Quadriceps muscle mass 10 cm above superior margin of patella	51.5 cm	51.5 cm
Calf muscle mass at Point of maximum growth	45.0 cm	45.0 cm

REVIEW OF RECORDS

DOCTOR'S FIRST REPORT, - DOI:
Description: I was opening rolling door and caught my middle finger of
left hand in door. Diagnosis: Subungual hematoma. TXPLAN:
Examination and redress. WORK STAT: regular work. (p. 4)

:Take Home Instructions, M.D. (St. Joseph Hospital)
- Diagnosis: General sprain/strain/bruise. (p.5)

DOCTOR'S FIRST REPORT, (St. Joseph
Hospital) - DOI: . Description: Ran after 3 felony suspects
while on duty as . Afterwards, slight pain in right knee. Pain
increased to right knee about 6-8 hours later. Possible strain the knee
while running. (p. 10)

HISTORY & PHYSICAL, M.D. (Saddelback
Memorial Medical Center) - History: He works as an . He was at
his watch commander's office and was standing up and states that he
felt his heart stop beating. He felt markedly light headed and dizzy. He
became flushed. He felt near fainting. He started to walk out of the
office to get some air. He felt his heart racing quite rapidly and then
this subsequently terminated. Diagnoses: (1) Near syncope. (2)
Hyperlipidemia. (3) Status post right knee meniscus tear. (p. 12)

RE: 11

: CHEST X-RAY – CC: Shortness of breath. Impression:
Within normal limits. (p. 11)

STIPULATIONS WITH REQUEST FOR AWARD (WCAB)
– DOI: Right knee. 0% Permanent Disability. Future
Medical Care to the right knee. (p. 4 MR2)

Consultative Rating Determination (DWC DEU) – No
apportionment. (p. 6 MR2)

Order Suspending Action on Stipulation with Request
for Award (WCAB) – Raise to 2%. (p.7 MR2)

Letter, Claim Examiner – We are in agreement to the
2% increase based on the rating by the Evaluation Unit. (p. 8 MR2)

Award (WCAB) – 2% Permanent Disability.(p. 9 MR2)

INITIAL ORTHOPEDIC EVALUATION, , M.D. –
DOI: CC: Left knee pain. History: He is a . He was
moving marijuana plants under the rotor blade of a helicopter. As he
was doing so, he lost balance, twisting his left knee. He had sharp
acute pain to the medial aspect of the knee. He had pain and
discomfort going up and down stairs. He had previous left knee
arthroscopic surgery to document a meniscus tear.
Past Medical: Hypertension. Mitral valve prolapsed.
Past Surgery: L knee arthroscopy.
Special Study: STANDING X-RAYS OF BOTH KNEES = slight medial
joint narrowing of left knee. Normal in right knee.
Diagnoses: (1) left knee medial meniscus tear. (2) Left knee internal
derangement. (3) Left knee chondromalacia patella.
TXPLAN: MRI of left knee. (p. 15)

RE:

12

Impressions: MRI OF LEFT KNEE – Impressions: (1) Joint effusion with patchy full thickness cartilage loss at the apex of patella and lateral femoral condyle. There is focal marrow contusion along the lateral aspect of lateral femoral condyle. (2) No evidence of meniscus tear. The medial and lateral meniscus demonstrate normal morphology and signal without evidence of tear. (p. 22)

Orthopedic Evaluation, M.D. – DOI:

CC: Pain and discomfort continues to be frequent moderate. He has pain with any exercise. He has to avoid deep knee bend. Diagnoses: (1) Left knee internal derangement. (2) Left knee previous meniscus tear. (3) Left knee chondromalacia. (4) Left knee contusion.

TXPLAN: Left knee arthroscopy and chondroplasty. (p. 27)

PR-2, M.D. – DOI: 3. CC: Left knee

pain with any exercise. Objective: MRI showed new lateral FC full thickness defect. TXPLAN: Request left knee arthroscopic surgery and chondroplasty. (p. 26)

OPERATIVE PROCEDURE, M.D. –

Procedure: (1) Left knee arthroscopic partial medial meniscectomy. (2) Left knee partial lateral meniscectomy. (3) Microfracture of trochlea. (4) Chondroplasty of trochlea, medial facet of patella and synovectomy. Diagnoses: (1) Left knee posterior horn medial meniscus tear. (2) Posterior horn lateral meniscus tear. (3) Chondromalacia medial patellar facet. (4) Chondromalacia trochlea. (5) Synovitis. (p. 32)

PR-2, M.D. – DOI: . CC: Moderate

pain. TXPLAN: PT. WORK STAT: TTD (p. 34)

PR-2, M.D. – DOI: . CC: Moderate

pain. TXPLAN: PT. WORK STAT: TTD (p. 35)

RE:

13

Notice of Temporary Restrictions – WORK STAT:
No pushing, pulling or lifting over 10 lbs. limited standing, walking or sitting. No stair climbing. (p. 36)

PERMANENT AND STATIONARY EVALUATION, M. D.
– DOI: [REDACTED]. CC: very little complaint. No pain with normal activity and ADL and function. Mild discomfort going down steps.
Diagnoses: (1) Left knee medial and lateral meniscus tears. (2) Chondromalacia of patella. (3) Chondromalacia of knee. Causation: The above diagnoses are the result of the [REDACTED] incident.
Disability Status: MMI. Work Restrictions: None. Apportionment: 60% of his present left knee impairment due to [REDACTED] incident and 40% due to prior non-industrial injury to left knee. **His prior knee injury and surgery on [REDACTED] was medial meniscus tear, chondromalacia of patella.** Impairment Rating: 3% WPI. Future Medical Care: Surgery (arthroscopy and total knee replacement) medication, physical therapy. (p. 37)

SUPERVISOR'S INVESTIGATION OF EMPLOYEE INJURY – DOI: [REDACTED] Employee was walking on the deck of a 29 foot motorboat that was adrift when he accidentally stepped into an open hatch and fell approximately 3 feet. He strained both knees and both ankles. (p. 46)

EMPLOYERS REPORT OF OCCUPATIONAL INJURY OF ILLNESS – DOI: [REDACTED]. Walking on deck of private boat. He fell approximately 3 feet into an open hatch of a boat that he accidentally stepped into. Attempting to secure a boat that was adrift. (p. 47)

EMPLOYEES REPORT OF OCCUPATIONAL INJURY OR ILLNESS – Strained/sprained both knees and both ankles. Attempting to secure an adrift 29' motorboat and falling approximately 3 feet into an open deck hatch while walking on deck of same boat. (p. 48)

RE:

14

.....: INITIAL ORTHOPEDIC EVALUATION REPORT, M.D. –
DOI: CC: Left knee and ankle pain. History: He works as
a He was on for the
throttle when he stepped into an open deck hatch. He fell
approximately 3 feet sustaining significant left knee injury and left
ankle sprain. He had medial joint line pain to his left knee. he had
swelling of left ankle with any inversion and twisting activity caused
him to have pain. Examination: L knee mild effusion. Moderate medial
joint line tenderness. Positive McMurray's and Apley's testing. L ankle
pain laterally and swelling. Lateral anterior/inferior talofibular ligament
tenderness. No drawer sign. Diagnoses: (1) Left knee internal
derangement. (2) left ankle sprain, Grade 1. TXPLAN: Relafen.
Physical therapy for L knee and L ankle. MRI of left knee. Relafen.
Physical therapy for L knee and L ankle. MRI of left knee. x-rays of
knees. X-rays of left ankle. X-rays of knees. X-rays of left ankle.
WORK STAT: No suspect contact. Limited stooping, bending and
squatting. No climbing stairs. (p. 49)

..... X-RAYS OF LEFT ANKLE, THREE VIEWS – Impressions:
(1) Moderate degenerative joint disease. (2) Calcaneal spurring. (3)
Accessory ossicle or old un-united fracture fragment adjacent to tip of
medial malleolus. Negative for acute fracture. (p.55)

..... Physical Therapy Daily Note (Brockton Physical
Therapy) – (p. 56)

.....: Physical Therapy Daily Note (Brockton Physical
Therapy) – (p. 57)

..... Physical Therapy Daily Note (Brockton Physical
Therapy) – (p. 58)

.....: PR-2, M.D. – DOI: CC: No pain.
Objective: MRI showed synovitis and effusion with mild
tricompartamental OA. Pain is > 90% better with PT, medication and
modified work. He wants to return to U&C work. Diagnoses: (1) Left
knee internal derangement. (2) Left ankle sprain. (p. 59)

RE: 15

Treating Physician's Progress Report, , M.D. –
DOI: . CC: Occasional and slight pain and stiffness in left knee
and in left ankle. Objective: L knee full ROM, no effusion. Mild lateral
snapping. L ankle full ROM and neurosensory intact. **He is P&S**. He
can return to work duties. (p. 60)

Workers Compensation Interim Evaluation for Surgery,
, M.D. – **DOI**: . CC: Increasing left knee pain. History:
More painful left knee. no new injury. let ankle stiffness because of
knee pain. Diagnoses: (1) Left knee internal derangement. (2) Left
ankle sprain. (3) Left knee arthroscopic surgery in _ and
TXPLAN: Left knee arthroscopy. Disability Status: P&S as of
(p. 43)

Treating Physician's Progress Report, M.D. – DOI:
. CC: Occasional slight left knee pain. WORK STAT: TTD
until (p. 61)

OPERATIVE REPORT, , M.D. – Procedures: (1)
Left knee arthroscopic partial medial meniscectomy at juncture of
middle and posterior horn medial meniscus. (2) Limited synovectomy.
(3) Chondroplasty of two separate area (trochlea and medial femoral
condyle) Diagnoses: (1) Left knee posterior horn medial meniscus tear.
(2) Grade 4 chondromalacia of trochlea and lateral femoral condyle.
(3) Grade 4 chondromalacia of medial femoral condyle on weight
bearing surface. (4) Synovitis. (p. 62)

Treating Physician's Progress Report, , M.D. –
DOI: . CC: L knee 1st post op. swelling stiffness and give
way. Objective: Wound no infection. NV intact. ROM decreased.
TXPLAN: Begin PT. WORK STAT: TTD. (p. 64)

Treating Physician's Progress Report, , M.D. – DOI:
. CC: 2nd post op visit. Residual weakness. Completed PT.
TXPLAN: Self PT to increase strength and functional balance. Do

RE: 16

figure 8 and balance rehab. WORK STAT: TTD. Start work (p. 65)

Treating Physician's Progress Report, , M.D. – DOI:
CC: 3rd post op visit. L knee stiffness, dull ache. Objective:
Crepitation of left knee 0-130°. Medial knee pain. mild swelling.
TXPLAN: Vicodin. Synvisc injection. WORK STAT: Working. (P. 66)

Treating Physician's Progress Report, , M.D. –
DOI: CC: L knee pain. authorized for Synvisc injection.
TXPLAN: Vicodin. Synvisc injection when product arrives. WORK
STAT: Working. (p. 68)

Treating Physician's Progress Report, , M.D. –
DOI: CC: L knee pain. TXPLAN: L knee Synvisc injection.
WORK STAT: Working, not disabled (p. 69)

Treating Physician's Progress Report, , M.D. –
DOI: CC: L knee pain. medial joint still hurt. Synvisc helped
50%. Objective: Crepitation. Osteophytes palpable. TXPLAN: Try
Celebrex. WORK STAT: Working, not disabled. (p. 70)

Workers Compensation Interim Evaluation For
Reevaluation, , M.D. – DOI: . CC: L knee pain. He is
responding to Celebrex. He still has medial joint line pain with certain
boat movements. Synvisc not as helpful as he would have liked. No
lateral joint line pain. Diagnoses: (1) Left knee internal derangement.
(2) Left ankle sprain. (3) Left knee medial joint line arthrosis. (4)
Left knee arthroscopic meniscectomy. TXPLAN: Dynamic medial
unloader brace. WORK STAT: Usual and customary work without
limitation.(p. 71)

RE:

17

..... Treating Physician's Progress Report,, M.D. –
DOI: CC: L knee pain. Awaiting brace and orthotics. Sleep
pain helped with Vicodin. Motrin gave him nightmares. Naprosyn and
Celebrex failed. Objective: L knee pain and swelling. Medial joint line
pain. TXPLAN: Cortisone injection to L knee. Great relief after
injection. (p. 74)

..... Treating Physician's Progress Report,, M.D. –
DOI: CC: Left knee pain. Objective: Increasing knee pain
and getting ready for surgery. TXPLAN: Surgery recommended. (p. 12
MR2)

..... X-RAYS OF BOTH KNEE STANDING AP VIEW –
Impressions: Mild-moderate bilateral medial compartment osteoarthritic
changes. Findings: There is mild to moderate bilateral medial
compartment joint space narrowing. Small bilateral medial
compartment osteophyte and tibial spine sharpening are present. The
lateral compartment joint spaces are preserved. Bone alignment is
anatomic. Soft tissue are within normal limits. (p. 159)

..... : OPERATIVE REPORTS,, M.D. – Procedure: Left
total knee arthroplasty. Diagnosis: Left knee degenerative joint
disease, severe bone-on-bone pathology. (p. 160)

..... X-RAYS OF LEFT KNEE – Impressions: Postoperative
changes following left total knee replacement. (p. 13 MR2)

..... : Acute Pain Service Progress Note,, M.D. –
TXPLAN: Continuous saphenous nerve catheter. (p. 164)

..... Acute Pain Service Progress Note,, M.D. –
TXPLAN: Discontinue femoral and saphenous nerve catheter. (p.16
MR2)

RE:

18

..... Treating Physician's Progress Report,, M.D. –
DOI: CC: 1st post op. L knee pain stomach irritation from
Norco. TXPLAN: Begin PT of left knee. Toradol. WORK STAT: TTD.
(p. 167)

..... Workers Compensation Interim Evaluation For
Reevaluation,, M.D. – DOI: CC: Decreasing left knee
pain, intermittent and moderate. TXPLAN: He needs more physical
therapy. (p. 170)

..... Workers Compensation Interim Evaluation For
Reevaluation,, M.D. – CC: Frequent moderate left knee pain.
Pain level is down. PT helping. TXPLAN: Ambien, Norco, Celebrex.
More physical therapy. WORK STAT: TTD. (p. 173)

..... Workers Compensation Interim Evaluation For
Reevaluation,, M.D. – CC: Responding to physical therapy.
occasional and slight knee pain. He had Cholecystectomy on Monday.
Off narcotics for left knee. TXPLAN: more physical therapy. WORKS
STAT: TTD. (p. 176)

..... AGREED MEDICAL EVALUATION,, M.D.
(Internal Medicine) – DOI: CT; Diagnoses: (1)
Hypertension. (2) Cardiac arrhythmia. (3) Cardiac study pending. (p.
179)

..... Physical Therapy Daily Note (Body Basic Physical
Therapy) – (p. 192)

..... Treating Physician's Progress Report,, M.D. –
CC: Left knee pain and stiffness. Hard to sleep at night with some
pain. Doing too much in the day time. TXPLAN: finish remaining PT.
WORK STAT: TTD. (p. 194)

RE: 19

24 HOUR HOLTER MONITOR STUDY – Impression:
Normal 24 hour Holter Monitor study. (p. 195)

ECHOCARDIOGRAM – Summary: (1) Non-dilated non-hypertrophic left ventricle with normal wall motion and ejection fraction. (2) Left ventricular ejection fraction was approximately 70%. (3) Normal filing pressure. (p. 196)

Physical Therapy Daily Note (Body Basic Physical Therapy) – (p. 199)

Physical Therapy Daily Note (Body Basic Physical Therapy) – (p. 201)

Physical Therapy Daily Note (Body Basic Physical Therapy) – (p. 203)

Physical Therapy Daily Note (Body Basic Physical Therapy) – (p. 205)

Treating Physician's Progress Report, M.D. –
CC: Left knee spasm, pain. Right knee a little pain. reduced activity but still need Vicodin at night time. TXPLAN: Neurontin for chronic pain. WORK STAT: TTD. (p. 207)

AGREED MEDICAL SUPPLEMENTAL REPORT,
M.D. (Internal Medicine) – Disability Status: MMI at
Impairment Rating: 12%WPI. Apportionment: Not applicable. Future Medical Care: Follow up 2 to 3 times a year. Annual testing. (p. 208)

AGREED MEDICAL EVALUATION, M.D.
– DOI: CC:
Constant left knee pain. Non-constant right knee pain. Constant neck pain that radiated into the interscapular region of the upper back. Non-constant low back pain that periodically radiates into both legs. Non-constant tingling at the ends of his finger. Job Description: He began working for Department on . He retired on . The last job he did was Sergeant/Watch Commander. He

RE:

20

held this position between _____, _____, _____. When he was out on the boat (30 to 50% of his work time), the physical demands of this job were as strenuous as the most strenuous work he performed at his other positions in the past. He worked 12 hours a day, 36 to 48 hours per week. He was assigned to _____. It was his job to supervise patrol deputies in three harbors, the dispatcher, and office staff. He performed law enforcement functions, marine firefighting functions, as well as rescue/lifesaving functions. He was in a patrol/firefighting watercraft when he was on the boat. He patrolled the harbors, along the shoreline, and the open sea. The job required occasional sitting, walking, standing, bending at the neck and waist, squatting, kneeling, crawling, and twisting at the neck and waist. There was frequent grasping with both hands. Occasionally, both hands were used for power grasping, fine manipulation, pushing and pulling, and reaching above and below shoulder level. The lifting demands for the job were occasionally in the range of 26 to 50 pounds. During emergencies, he was required to lift 200 pounds or more when he had to rescue individuals. He wear a uniform, a ballistic vest protector, firearm magazines, baton, pepper spray, taser, handcuffs, radio pac-set in a Sam Browne duty belt at all times. His Sam Browne belt was made of nylon. Prior to _____, _____, _____ his Sam Browne belt was leather. The nylon Sam Browne belt weight an average of 30 to 32 pounds. History of _____ injury: Right fifth metacarpal fracture as a child. He fell forward, landing with his right hand in front of his chest. He had residual clicking of the proximal joint of the right little finger. History of _____ back injury: He worked for _____. It was a strenuous job fighting fires. The job entailed hauling heavy equipment on his back in rough terrain. History of _____ Digital injury: He smashed the left middle finger in a door in _____. History of _____ Right knee injury: He was in pursuit on foot after an individual. After running ½ to ¾ mile, he noted right knee pain. he had surgery to right knee. He received 2% permanent disability and future medical care. _____ Left ankle injury: He was running on a field for exercise. He twisted his left ankle in a gopher hole. History of _____ left knee injury: He

RE:

21

was assigned as an . He was on his lunch hour when he and other officers went to the to play a basketball game. He jumped up for a rebound. He landed on his left leg. His left knee became swollen. He underwent left knee surgery on History of Left knee injury: He was loading marijuana onto a cargo net which was being hoisted up by a helicopter. He was on a hillside. He accidentally stepped into a hole. He twisted his left knee. He underwent left knee surgery. History of injury: He was out on patrol and fell into an open hatch of a moving boat. This primarily injured his left knee, but he also sustained injuries to both legs. History on left foot injury: He accidentally kicked a humidifier in his father's house. History of CT: Low back which he attributes to having to wear a Sam Brown belt for prolonged period of time while sitting in his police car. Neck pain from physical demands of his work. Bilateral knee pain from specific injuries and progressively worsened as time passed.

Special Study: X-RAYS OF CERVICAL SPINE = Osteopenia. C5-6 loss of disc height and large anterior osteophyte. C6-7 moderate loss of disc height with moderate anterior and moderate posterior spurring. Retrolisthesis of C6 on C7 in neutral that corrected on flexion. X-RAYS OF LUMBAR SPINE = moderate to severe loss of disc height at L5-S1 with moderate anterior spurring. There as a vacuum disc effect. X-RAYS OF PELVIS = normal. X-RAYS OF RIGHT KNEE = narrowing of medial joint space; quadriceps tendon calcification. X-RAYS OF LEFT KNEE = total knee arthroplasty. X-RAYS OF RIGHT ANKLE = ankle joint space of 3.3 mm. Large spurring from distal anterior right tibia. X-RAYS OF LEFT ANKLE = ankle joint space of 3.5 mm. Moderate anterior distal tibia spur.

Review of Records (p. 110- 128)

Diagnoses: (1) Neck sprain/strain with C5-6 and C6-7 disc disease. (2) Low back sprain/strain with L5-S1 DDD. (3) Status post right knee arthroscopy, partial medial meniscectomy and chondroplasty on . (4) Status post left knee arthroscopy, partial medial meniscectomy and partial synovectomy on . (5) Status post left knee arthroscopy, medial and lateral meniscectomy with

RE:

22

debridement and micro fracture of trochlea on 10/2007. (6) Status post left knee arthroscopy partial medial meniscectomy on 10/2007. (7) Status post left total knee arthroplasty on 10/2003. (8) Status post bilateral ankle sprains. (9) No electrodiagnostic evidence of cervical radiculopathy.

Disability Status: Neck, back, R knee and ankles reached P&S on 10/2007. L knee reached MMI on 10/2007.

Work Restrictions: Neck precluded from very heavy lifting and prolonged bending. Lower back precluded from very heavy work. Right knee precluded from very heavy lifting, kneeling, repetitive squatting and repetitive climbing. Left knee precluded from weight bearing > 4 hours in an 8 hour day, very heavy lifting, kneeling, repetitive squatting and repetitive climbing. No work restrictions for ankles.

Impairment Rating: Cervical spine 8% WPI. Lumbar 8% WPI. R knee 4.5% WPI. Left knee 20% WPI. R ankle 1.4% WPI. L ankle 1% WPI.

Future Medical Care: Neck needs medication, therapy, chiropractic care, acupuncture, cervical pillows, surgery if disease progress; CESI. Low back needs medications, therapy, chiropractic care, acupuncture, lumbar roll, surgery if DDD progress and LESI. Right knee needs medications, therapy, acupuncture, cortisone injections, Synvisc injections, TKA if DJD progressed. L knee needs medications, revision TKA surgery. Physical therapy, acupuncture. Ankles needs medications.

Return to Work: He cannot resume work as a [redacted].

Apportionment: Neck is 90% CT and 10% non-industrial DDD. Lower back is 85% CT, 5% [redacted] and 10% non-industrial DDD. Right knee is 20% due to [redacted] injury; 70% to CT and 10% to non-industrial DJD. Left knee is 20% to 2003 injury; 40% to [redacted] injury; 20% to [redacted] injury; 10% to CT and 10% to non-industrial DJD. Right ankle is 90% to CT and 10% to non-industrial DJD. Left ankle is 20% to [redacted] injury; 70% to CT and 10% to non-industrial DJD. (p. 75)

RE:

23

EMG/NCV OF BILATERAL UPPER EXTREMITIES –

Impressions:

Mild to moderate bilateral sensory/motor median nerve carpal tunnel syndrome at the wrists. The study is normal for neuropathy. The EMG is normal for cervical radiculopathy. (p. 213)

EMG/NCV OF BILATERAL LOWER EXTREMITIES –

Impressions: A low grade chronic bilateral L5 lumbar radiculopathy pattern without active denervation. Normal for neuropathy, plexopathy or lumbar disc disease at other levels. EMG changes may be due to nerve irritation, disc disease or related pathologies. (p.17 MR2)

MRI OF CERVICAL SPINE WITHOUT CONTRAST –

Impressions: Multilevel cervical spondylosis. Findings: 2 mm posterior subluxation of C6 relative to C7. There is moderate to severe disc degeneration at C6-7. There is moderate disc degeneration at C5-6. There is slight anterior wedging of C6 vertebral body that may be related to chronic degenerative change. (p. 221)

Treating Physician's Progress Report, , M.D. –

CC: Left knee pain. Right knee pain.. Marked improvement with Neurontin and Vicodin. Sleeping well in the night. Less pain and swelling. Decreasing Neurontin down to 2. TXPLAN: decrease Neurontin and Vicodin. Increase self PT. WORK STAT: RETIRED. (p. 300)

Treating Physician's Progress Report, , M.D. –

CC: Left knee pain.. Right knee pain. nigh pain. TXPLAN: Self PT to gain full ROM. Use Tylenol and Cosamin DS. WORK STAT: RETIRED. (p. 301)

Prescription, , M.D. – Cosamin DS. (p. 302)

RE:

24

PERMANENT & STATIONARY REPORT, M.D.
- DOI: 1. Diagnoses: (1) Left knee DJD. Left knee TKA. (2) Left ankle sprain. (3) Left knee medial joint line arthrosis. Left knee arthroscopic meniscectomy. Causation: The diagnoses are the result of the industrial incident on .
Disability Status: He is P&S today. Return to Work: He is not disabled. He is returned to his usual and customary work without limitation. Subjective Factors: Occasional slight left knee pain. Right knee stiffness compensating for the left knee. He takes Neurontin and Vicodin at night. Objective Factors: Some residual pain and well healed surgical scar. Work Restriction: He is retired. Apportionment: 100% of his impairment is due to the industrial injury.
Impairment Rating: 20% WPI for left TKA. Future Medical Care: Neurontin. Vicodin. Revision TKA. NSAIDs. Physical therapy. (p. 304)

OCERS PHYSICIAN'S STATEMENT OF DISABILITY, M.D. -
CC: Bilateral knee pain. Objective: Effusion, persistent pain.
Diagnoses: (1) Left knee degenerative joint disease. (2) Left ankle sprain. Limitations: Avoid cramped/unusual positions, bending, stooping, squatting, operate heavy equipment. Some limitation balancing, stairs, ladders, operate truck/car, operate electric equipment. Disability: He is permanently disabled for the duties of his occupation. (p. 150)

OCERS EMPLOYEE'S STATEMENT OF DISABILITY - I am limited to desk duty only. No weight bearing on left knee. No bending, stooping, or squatting. No marine fire fighting; law enforcement duties while operating a department vessel on jurisdiction waterways. I am unable to perform the full law enforcement duties of a Sergeant with Homeland Security Division. I was place on Labor Section 4850 benefits. (p. 154)

AUTHORIZATION FOR DISCLOSURE AND USE OF PROTECTED HEALTH INFO. EMPLOYEE - (p. 157)

RE: 25

DIAGNOSTIC IMPRESSIONS

1. Left ankle sprain, not work related. ()
2. Left knee sprain and medial meniscus tear, not work related.
3. Status post left knee arthroscopic partial medial meniscectomy.
4. Left knee sprain and meniscus tears. ()
5. Status post left knee arthroscopy
 - a. Partial medial & lateral meniscectomy.
 - b. Chondroplasty of trochlea, medial patellar facet.
 - c. Microfracture of trochlea.
6. Left knee sprain and meniscus tears. ()
7. Left ankle sprain. ()
8. Status post left knee arthroscopy
 - a. Partial medial and lateral meniscectomy.
 - b. Synovectomy.
 - c. Chondroplasty of trochlea and medial femoral condyle.
9. Left knee post-traumatic degenerative joint disease.
10. Status post left total knee arthroplasty.
11. Left ankle degenerative joint disease.

SUMMARY & DISCUSSION

filed an Application for Disability Retirement with the County of Orange. He suffered a left ankle sprain that was not related to work in . He suffered a left knee sprain with medial meniscus

RE:

26

tear in [redacted]. He suffered a work-related left knee sprain with meniscus tears on [redacted]. He states that he injured his knees and ankles at work on [redacted]. His treatment consisted of rest, medications, physical therapy and knee surgeries.

Subjectively, [redacted] complains of frequent achy throbbing pain with activity in his left knee. He complains of swelling and stiffness in his left knee. He states that his ankles "*gets sore*" on some days.

Objectively, [redacted] ambulates with a normal gait. There are well healed arthroscopic portal surgical scars on both knee. There is a well healed vertical surgical scar on the anterior aspect of his left knee. There is arthritic changes on his right knee.

There is effusion in the left knee joint. He reports a vague sense of pain "*inside*" his knee joints. The left knee has slight loss of flexion. He reports altered sensibility along the right anterior thigh to the posterolateral calf. He reports decreased sensibility lateral to the left knee surgical incision (normal result of surgery). His left ankle examination is grossly normal.

Standing x-rays of both knees taken on [redacted] showed medial joint narrowing in the left knee; normal in the right knee.

MRI of left knee taken on [redacted] showed joint effusion, patchy full thickness cartilage loss at the apex of patella and at lateral femoral condyle; there is focal marrow contusion along the lateral aspect of the lateral femoral condyle.

X-rays of left ankle taken on [redacted] showed moderate degenerative joint disease, calcaneal spurring and signs of old trauma at the tip of medial malleolus.

Standing x-rays of both knees taken on [redacted] showed bilateral medial compartment osteoarthritis.

RE: 27

X-rays of left knee taken on [redacted] showed post operative changes following total knee replacement.

X-rays of right knee taken on [redacted] showed narrowing of medial joint space.

X-rays of left knee taken on [redacted] showed total knee arthroplasty.

X-rays of right ankle taken on [redacted] showed degenerative changes.

X-rays of left ankle taken on [redacted] showed degenerative changes.

EMG/NCV of lower extremities obtained on [redacted] showed low grade bilateral L5 radiculopathy.

PERMANENT INCAPACITY

Given my current understanding of [redacted] left knee condition, it is my opinion that he has left knee physical limitations which would impact his ability to work effectively as a [redacted]. He underwent left total knee replacement. Although he can still perform the administrative portion of the job, it is my opinion that he does not have the agility to respond quickly at times for suspect apprehension or during marine firefighting. The prosthetic knee replacement is not designed to withstand the forces of running, jumping or uncontrolled twisting during suspect apprehension or during marine firefighting. **Therefore, I conclude with reasonable medical probability that cannot substantially perform the most physical demanding duties of his [redacted] job because of the current condition in his left knee.**

Given my current understanding of [redacted] left ankle condition, it is my opinion that he does not have left ankle physical limitations which would impact on his ability to work effectively as a [redacted]. He has very mild subjective complaints about his left ankle. He demonstrates benign left ankle physical examination. He has degenerative bony

RE:

28

spurs along the anterior distal tibia. **Therefore, I conclude with reasonable medical probability that [redacted] left ankle condition does not substantially interfere with his ability to perform the usual duties of his county job.**

SERVICE CONNECTION

[redacted] had both work-related and non work-related injuries to his left knee. He had degenerative arthritis in his left knee; he also has degenerative arthritis in the right knee. It is my opinion that he had a genetic predisposition to develop degenerative arthritis in his knee joint.

It is my opinion that his work-related left knee injuries as a [redacted] accelerated the natural history of the degenerative arthritis in his left knee.

He underwent multiple arthroscopic partial meniscectomy to relieve the aftereffects of his work-related left knee injuries. Loss of the cushioning effect from partial meniscectomy in his left knee accelerated the arthritic condition in that joint.

Therefore, it is my opinion that [redacted] on-the-job left knee injuries were real and measurable factors in contributing to his left knee permanent incapacity to perform the duties of [redacted]

[redacted] provided a comprehensive history of both injury and treatment during my evaluation. I found the applicant to be forthright and his physical findings supported his subjective complaints.

RE:

29

Thank you for the opportunity to evaluate . I trust that this report answers your questions, however, if I can be of further assistance in this regard or others, please do not hesitate to contact me at your earliest convenience.

Very truly yours,


Jason J. Chiu, M.D.
Board Certified, Orthopaedic Surgery

Qualified Medical Examiner

JJC:jh

January 20, 2016

TO: Each Member
Board of Retirement

FROM: Ricki Contreras, Manager 
Disability Retirement Services Division

FOR: February 3, 2016 Board of Retirement Meeting

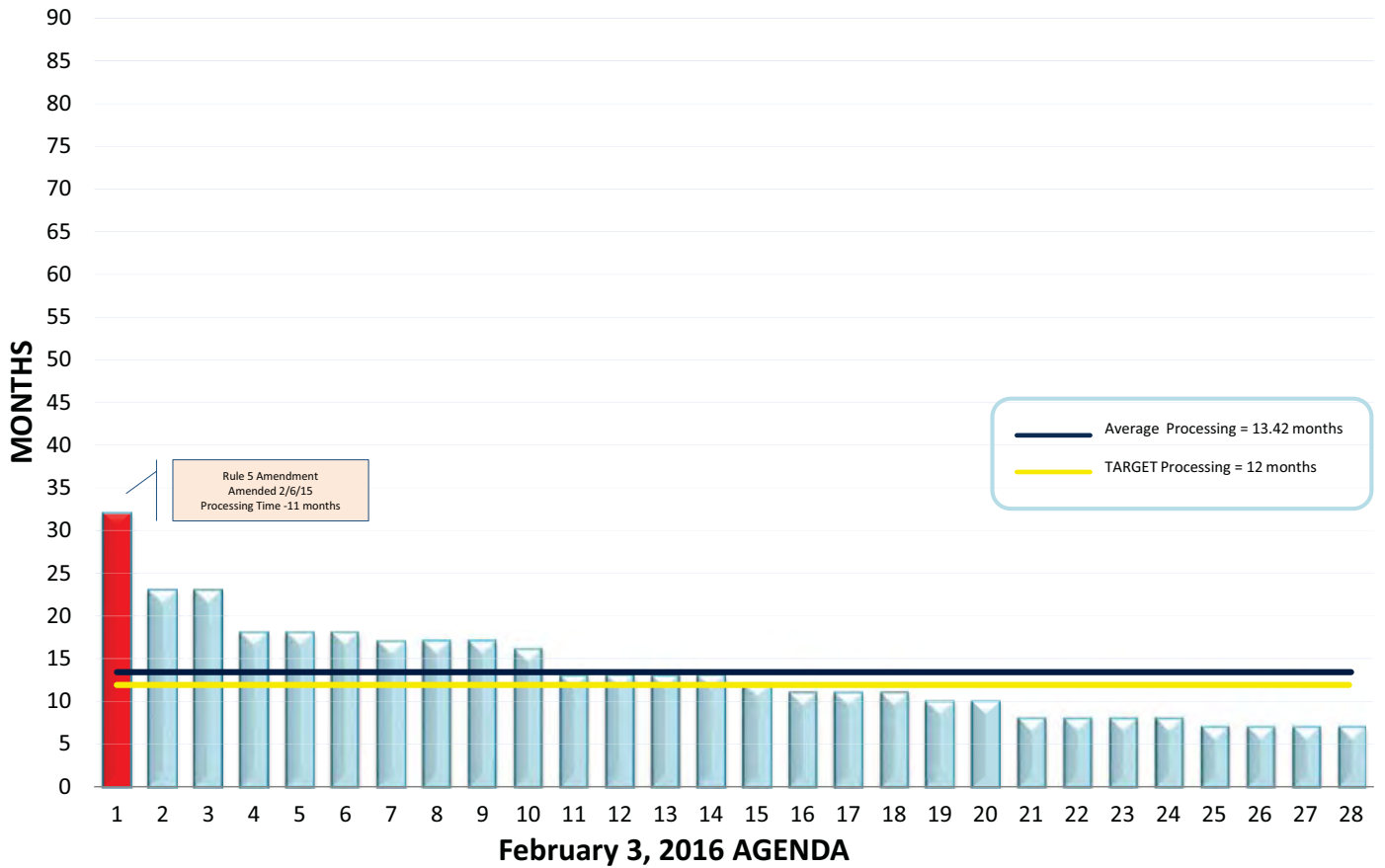
SUBJECT: **Application Processing Time Snapshot Reports**

At the February 4, 2015 meeting, the Disability Procedures & Services Committee voted to add two additional snapshot reports addressing application processing times and pending applications by elapsed time since application date. These reports will now be provided on a monthly basis along with the current snapshot that provides a look at application processing time before and after procedural changes were made to the disability application process. The Board adopted proposed changes on July 12, 2012. The chart breaks down the periods for cases processed under the old procedures vs. the new procedures with the associated monthly processing timeframes.

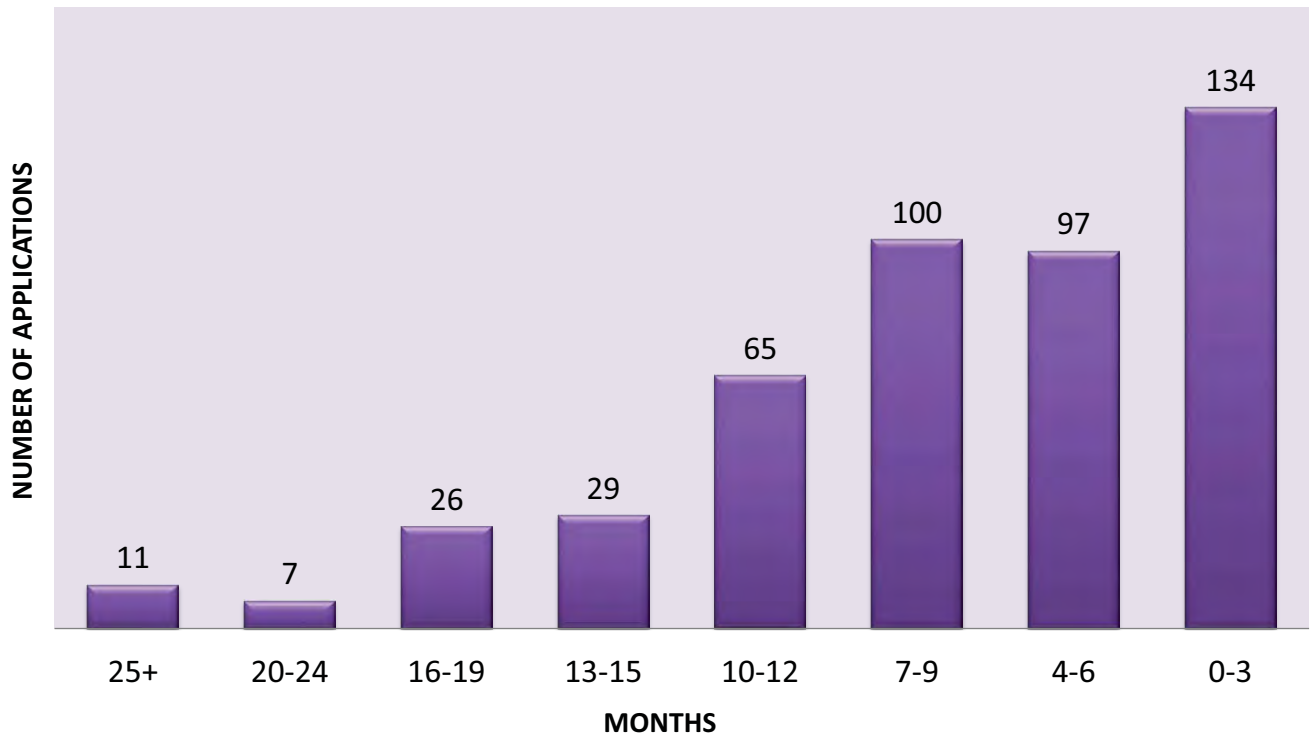
The following chart shows the total time from receipt of the application to the first Board action for the month in question.

Consent & Non-Consent Calendar			
Received <u>Prior</u> to July 12, 2012		Received <u>After</u> July 12, 2012	
Number of Applications	Processing Time (in Months)	Number of Applications	Processing Time (in Months)
0	0	27	12.67
Revised/Held Over Calendar			
<i>Rule 5 Amendment</i> total average processing time since receipt of amendment (case in process including Appeal - 32.0 months)			Case 1 11.0
<i>Average Processing Time for Revised/Held Over Calendar</i>			11.0

ACTUAL vs. AVERAGE PROCESSING TIME



TIME ELAPSED FOR PENDING APPLICATIONS





Documents not attached are exempt from disclosure under the California Public Records Act and other legal authority.

**For further information, contact:
LACERA
Attention: Public Records Act Requests
300 N. Lake Ave., Suite 620
Pasadena, CA 91101**



Documents not attached are exempt from disclosure under the California Public Records Act and other legal authority.

**For further information, contact:
LACERA
Attention: Public Records Act Requests
300 N. Lake Ave., Suite 620
Pasadena, CA 91101**



Documents not attached are exempt from disclosure under the California Public Records Act and other legal authority.

**For further information, contact:
LACERA
Attention: Public Records Act Requests
300 N. Lake Ave., Suite 620
Pasadena, CA 91101**



Documents not attached are exempt from disclosure under the California Public Records Act and other legal authority.

**For further information, contact:
LACERA
Attention: Public Records Act Requests
300 N. Lake Ave., Suite 620
Pasadena, CA 91101**



Documents not attached are exempt from disclosure under the California Public Records Act and other legal authority.

**For further information, contact:
LACERA
Attention: Public Records Act Requests
300 N. Lake Ave., Suite 620
Pasadena, CA 91101**