

# AGENDA

## A REGULAR MEETING OF THE BOARD OF RETIREMENT

### LOS ANGELES COUNTY EMPLOYEES RETIREMENT ASSOCIATION

300 N. LAKE AVENUE, SUITE 810, PASADENA, CA

9:00 A.M., WEDNESDAY, JULY 6, 2016

*The Board may take action on any item on the agenda,  
and agenda items may be taken out of order.*

- I. CALL TO ORDER
- II. PLEDGE OF ALLEGIANCE
- III. APPROVAL OF MINUTES
  - A. Approval of the Minutes of the Regular Meeting of June 1, 2016
- IV. REPORT ON CLOSED SESSION ITEMS
- V. PUBLIC COMMENT
- VI. CONSENT AGENDA
  - A. Ratification of Service Retirement and Survivor Benefit Application Approvals.
  - B. Requests for an administrative hearing before a referee.  
(Memo dated June 21, 2016)
  - C. Recommendation as submitted by Vivian H. Gray, Chair, Disability Procedures & Services Committee: That the Board approve Noam Drazin, M.D. – Board Certified Oncologist to the LACERA Panel of Physicians for the purpose of examining disability retirement applicants. (Memo dated June 10, 2016)

July 6, 2016

Page 2

VI. CONSENT AGENDA (Continued)

- D. Recommendation as submitted by Vivian H. Gray, Chair, Disability Procedures & Services Committee: That the Board approve Jonathan T. Nassos, M.D. – Board Certified Orthopaedist to the LACERA Panel of Physicians for the purpose of examining disability retirement applicants. (Memo dated June 10, 2016)
- E. For Information Only as submitted by Ricki Contreras, Division Manager, Disability Retirement Services, regarding the Application Processing Time Snapshot Reports. (Memo dated June 24, 2016)

VII. REPORT ON STAFF ACTION ITEMS

VIII. GOOD OF THE ORDER  
(For information purposes only)

IX. DISABILITY RETIREMENT APPLICATIONS ON CONSENT CALENDAR

X. DISABILITY RETIREMENT CASES TO BE HELD IN CLOSED SESSION

- A. Applications for Disability
- B. Referee Reports
- C. Staff Recommendations

- 1. Recommendation as submitted by Eugenia W. Der, Senior Staff Counsel, Disability Litigation: That the Board find **Arnold Leon** permanently incapacitated for service-connected reasons and grant him a service-connected disability retirement. (Letter dated June 15, 2016)

XI. EXECUTIVE SESSION

- A. Conference with Legal Counsel - Existing Litigation (Pursuant to Paragraph (1) of Subdivision (d) of California Government Code Section 54956.9)

- 1. Marlena Graves v. Board of Retirement

July 6, 2016

Page 3

## XII. ADJOURNMENT

*Documents subject to public disclosure that relate to an agenda item for an open session of the Board of Retirement that are distributed to members of the Board of Retirement less than 72 hours prior to the meeting will be available for public inspection at the time they are distributed to a majority of the Board of Retirement Members at LACERA's offices at 300 N. Lake Avenue, Suite 820, Pasadena, CA 91101, during normal business hours of 9:00 a.m. to 5:00 p.m. Monday through Friday.*

*Persons requiring an alternative format of this agenda pursuant to Section 202 of the Americans with Disabilities Act of 1990 may request one by calling Cynthia Guider at (626) 564-6000, from 8:30 a.m. to 5:00 p.m. Monday through Friday, but no later than 48 hours prior to the time the meeting is to commence. Assistive Listening Devices are available upon request. American Sign Language (ASL) Interpreters are available with at least three (3) business days notice before the meeting date.*

MINUTES OF THE REGULAR MEETING OF THE BOARD OF RETIREMENT

LOS ANGELES COUNTY EMPLOYEES RETIREMENT ASSOCIATION

300 N. LAKE AVENUE, SUITE 810, PASADENA, CA

9:00 A.M., WEDNESDAY, JUNE 1, 2016

PRESENT:       Shawn R. Kehoe, Chair  
  
                  Vivian H. Gray, Vice Chair  
  
                  William de la Garza, Secretary  
  
                  Marvin Adams  
  
                  Anthony Bravo  
  
                  Yves Chery  
  
                  David L. Muir (Alternate Retired)  
  
                  William Pryor (Alternate Member)  
  
                  Les Robbins (Mr. Robbins left at 10:05 a.m.)

ABSENT:        Joseph Kelly  
  
                  Ronald A. Okum

STAFF ADVISORS AND PARTICIPANTS

Gregg Rademacher, Chief Executive Officer

John Popowich, Assistant Executive Officer

Dr. Vito Campese, Medical Advisor

Steven P. Rice, Chief Counsel

STAFF ADVISORS AND PARTICIPANTS (Continued)

Ricki Contreras, Division Manager  
Disability Retirement Services

Tamara Caldwell, Specialist Supervisor  
Disability Retirement Services

Francis J. Boyd, Senior Staff Counsel  
Legal Division

Eugenia W. Der, Senior Staff Counsel  
Disability Litigation

Thomas J. Wicke, Attorney at Law  
Lewis, Marenstein, Wicke & Sherwin, LLP

I. CALL TO ORDER

The meeting was called to order by Chair Kehoe at 9:00 a.m., in the Board Room of Gateway Plaza.

II. PLEDGE OF ALLEGIANCE

Mr. Adams led the Board Members and staff in reciting the Pledge of Allegiance.

III. APPROVAL OF MINUTES

A. Approval of the Minutes of the Special Meeting of May 5, 2016

Mr. Adams made a motion, Mr. de la Garza seconded, to approve the minutes of the special meeting of May 5, 2016. The motion passed unanimously.

IV. REPORT ON CLOSED SESSION ITEMS

No items were reported.

V. PUBLIC COMMENT

There were no requests from the public to speak.

VI. CONSENT AGENDA

Chair Kehoe made a motion, Mr. Chery seconded, to approve the following agenda items. The motion passed unanimously.

- A. Ratification of Service Retirement and Survivor Benefit Application Approvals.
- B. Requests for an administrative hearing before a referee.  
(Memo dated May 19, 2016)
- C. Recommendation as submitted by Ricki Contreras, Division Manager, Disability Retirement Services: That the Board dismiss with prejudice the appeal for a service connected disability retirement in the case of **Bertha F. Luna**. (Memo dated May 19, 2016)
- D. Recommendation as submitted by Vivian H. Gray, Chair, Disability Procedures & Services Committee: That the Board approve Arthur H. Fass, DPM – Board Certified Podiatrist to the LACERA Panel of Physicians for the purpose of examining disability retirement applicants. (Memo dated May 17, 2016)
- E. For Information Only as submitted by Ricki Contreras, Division Manager, Disability Retirement Services, regarding the Application Processing Time Snapshot Reports. (Memo dated May 20, 2016)

VII. REPORT ON STAFF ACTION ITEMS

There was nothing to report on staff action items.

VIII. GOOD OF THE ORDER  
(For information purposes only)

Messrs. Chery and Robbins shared their experience in attending the IFEBP

Washington Legislative Update conference.

Mr. Muir shared the passing of Martin Golds who served on RELAC's Board of Directors for 20 years.

IX. DISABILITY RETIREMENT APPLICATIONS ON CONSENT CALENDAR

Safety Law Enforcement  
Service-Connected Disability Applications

On a motion by Chair Kehoe, seconded by Ms. Gray, the Board of Retirement approved a service-connected disability retirement for the following named employees who were found to be disabled for the performance of their duties and have met the burden of proof:

<u>APPLICATION NO.</u>	<u>NAME</u>
482C	ANTHONY FORLANO
483C*	CORY A. KENNEDY
484C	JEFF M. MOORE
485C**	DUSTIN A. STILLWELL
486C**	JAMES N. BITETTO
487C	CRYSTAL N. CARTER

\* Granted SCD – Retroactive

\*\* Granted SCD – Employer Cannot Accommodate

IX. DISABILITY RETIREMENT APPLICATIONS ON CONSENT CALENDAR

Safety Law Enforcement (Continued)  
Service-Connected Disability Applications

<u>APPLICATION NO.</u>	<u>NAME</u>
488C	DONALD H. RASMUSSEN
489C	PETER MOE
490C**	WAYNE V. SWEENEY
491C	MICHAEL J. JACKSON
492C*	GARY B. GREENWOOD
493C**	KEVIN L. BOOTHE
494C*	FREDERICK J. MC NUTT
495C**	JOHN F. PIAZZA

Safety-Fire, Lifeguard  
Service-Connected Disability Applications

On a motion by Mr. Pryor, seconded by Mr. Chery, the Board of Retirement approved a service-connected disability retirement for the following named employees who were found to be disabled for the performance of their duties and have met the burden of proof:

<u>APPLICATION NO.</u>	<u>NAME</u>
1767A	THOMAS R. VALDEZ

\* Granted SCD – Retroactive

\*\* Granted SCD – Employer Cannot Accommodate



IX. DISABILITY RETIREMENT APPLICATIONS ON CONSENT CALENDAR

Safety-Fire, Lifeguard (Continued)  
Service-Connected Disability Applications

<u>APPLICATION NO.</u>	<u>NAME</u>
1768A	SHAWN E. IVIE
1769A*/**	MATTHEW T. LEWIS
1770A	DANIEL A. ERTEL
1771A	WILLIAM P. MCHALE
1772A	JAMES O. MCDONALD
1773A	CHARLES D. BOYD
1774A***	GINO E. ZENI (DECEASED)
1775A****	THOMAS D. JONES
1776A****	DANIEL J. MARTIN
1777A	VICTOR J. YANEZ
1778A	MANUEL ROBLES

\* Applicant Present

\*\* Granted SCD – Employer Cannot Accommodate

\*\*\* Granted SCD – Survivor Benefits

\*\*\*\* Granted SCD – Retroactive

IX. DISABILITY RETIREMENT APPLICATIONS ON CONSENT CALENDAR

General Members

Service-Connected Disability Applications

On a motion by Mr. Chery, seconded by Mr. Bravo, the Board of Retirement approved a service-connected disability retirement for the following named employees who were found to be disabled for the performance of their duties and have met the burden of proof:

<u>APPLICATION NO.</u>	<u>NAME</u>
2617B	HORTENCIA MAYNES
2618B*	ELVIRA M. SANCHEZ
2619B	DAKOTA SANDS
2621B	ZENOLA F. JOHNSON
2622B**/**	LA TONYA D. JACKSON
2623B*	ANNETTE M. MOTLEY
2624B	MARIE N. FOBI
2625B**/**	PATRICK J. BLANKENSHIP
2626B****	ANTHONY T. TILL

\* Granted SCD – Retroactive

\*\* Applicant Present

\*\*\* Granted SCD – Salary Supplement

\*\*\*\* Granted SCD – Employer Cannot Accommodate

IX. DISABILITY RETIREMENT APPLICATIONS ON CONSENT CALENDAR

General Members

Non-Service-Connected Disability Applications

On a motion by Mr. Adams, seconded by Mr. de la Garza, the Board of Retirement approved a non-service connected disability retirement for the following named employees who were found to be disabled for the performance of their duties and have met the burden of proof:

<u>APPLICATION NO.</u>	<u>NAME</u>
4342	ERIC C. SERVIN
4343*	DESERIE M. VASQUEZ

X. DISABILITY RETIREMENT CASES TO BE HELD IN CLOSED SESSION

A. Applications for Disability

<u>APPLICATION NO. &amp; NAME</u>	<u>BOARD ACTION</u>
2620B – MELVIN IRVIN	This case was pulled from the agenda by the request of staff.
6891A – CATHERINE J. PETRILLO	Mr. Chery made a motion, Mr. Bravo seconded, to grant a service connected disability retirement.  Ms. Gray made a substitute motion, Mr. Chery seconded, to refer back to staff for additional information. The motion passed with Mr. de la Garza voting no.

X. DISABILITY RETIREMENT CASES TO BE HELD IN CLOSED SESSION

A. Applications for Disability (Continued)

<u>APPLICATION NO. &amp; NAME</u>	<u>BOARD ACTION</u>
6892A – MARION C. FIGUEROA	Mr. de la Garza made a motion, Mr. Pryor seconded, to grant a non-service connected disability retirement pursuant to Government Code Section 31720. The motion passed unanimously.
6893A – JUDIT HARRIS*	Chair Kehoe made a motion, Mr. Chery seconded, to refer back to staff for additional information.  Mr. Pryor made a substitute motion, Mr. Adams seconded, to grant a service connected disability retirement. The makers of the motion withdrew their motion.  The motion to refer back to staff passed unanimously.
6894A – ANDREA M. JACKSON*	Ms. Gray made a motion, Mr. Chery seconded, to grant a service connect disability retirement with a two year review. The motion passed unanimously.
6842A – JERRY BROWN	Mr. de la Garza made a motion, Ms. Gray seconded, to grant a non-service connected disability retirement pursuant to Government Code Section 31720 since the employer cannot accommodate. The motion passed unanimously.

\* Applicant Present

X. DISABILITY RETIREMENT CASES TO BE HELD IN CLOSED SESSION

A. Applications for Disability (Continued)

<u>APPLICATION NO. &amp; NAME</u>	<u>BOARD ACTION</u>
6886A – VICTORIA I. ORTIZ	Chair Kehoe made a motion, Mr. Adams seconded, to grant a non-service connected disability retirement with a salary supplement pursuant to Government Code Sections 31725.5 and 31720. The motion passed unanimously.
6873A – TERESA R. ANDERSON	Chair Kehoe made a motion, Mr. Chery seconded, to grant a service connected disability retirement pursuant to Government Code Section 31720 and grant the option for an earlier effective date pursuant to Government Code Section 31724. The motion passed unanimously.

(Mr. Robbins left the Board meeting at 10:05 a.m.)

B. Referee Reports

<u>APPLICATION NO. &amp; NAME</u>	<u>BOARD ACTION</u>
MARIAN E. PAEZ – Scott E. Wheeler for the applicant Allison Barrett for the respondent	Ms. Gray made a motion, Mr. Adams seconded, to grant a non-service connected disability retirement. The motion passed unanimously.

X. DISABILITY RETIREMENT CASES TO BE HELD IN CLOSED SESSION

B. Referee Reports (Continued)

APPLICATION NO. & NAME

BOARD ACTION

SERGIO J. HERNANDEZ – Thomas J. Wicke for the applicant  
Eugenia W. Der for the respondent

Chair Kehoe made a motion, Mr. Pryor seconded, to grant a non-service connected disability retirement. The motion failed (roll call) with Mr. de la Garza voting yes; and Messrs. Adams, Bravo, Chery, Ms. Gray, and Chair Kehoe voting no.

Ms. Gray made a motion, Chair Kehoe seconded, to refer back to staff for additional information. The motion passed (roll call) with Messrs Adams, Bravo Chery, Ms. Gray, and Chair Kehoe voting yes; and Mr. de la Garza voting no.

C. Staff Recommendations

1. Recommendation as submitted by Eugenia W. Der, Senior Staff Counsel, Disability Litigation: That the Board find that **Gloria Ramirez** delayed in the filing of her application for disability retirement because she was unable to ascertain the permanency of her incapacity and that her application be deemed filed on the day after the last day of regular compensation in accordance with Government Code Section 31724. (Letter dated April 28, 2016)

Ms. Der was present to answer questions from the Board.

Mr. de la Garza made a motion, Mr. Chery seconded, to approve the recommendation. The motion passed unanimously.

June 1, 2016

Page 12

Green Folder Information (Information distributed in each Board Member's Green Folder at the beginning of the meeting)

1. Retirement Board Listing dated June 1, 2016

XI. ADJOURNMENT

There being no further business to come before the Board, the meeting was adjourned at 10:26 a.m.

---

WILLIAM DE LA GARZA, SECRETARY

---

SHAWN R. KEHOE, CHAIR



June 21, 2016

TO: Each Member  
Board of Retirement

FROM: Ricki Contreras, Manager   
Disability Retirement Services Division

SUBJECT: **APPEALS FOR THE BOARD OF RETIREMENT'S MEETING OF  
July 6, 2016**

**IT IS RECOMMENDED** that your Board grant the appeals and requests for administrative hearing received from the following applicants and direct the Disability Retirement Services Manager to refer each case to a referee:

6894A	Andrea Jackson	In Pro Per	SCD 2yr Review – No Option of an Earlier Effective Date
6842A	Jerry Brown	In Pro Per	Deny SCD – Grant NSCD
6886A	Victoria I. Ortiz	In Pro Per	Deny SCD – Grant NSCD Salary Supplement





June 10, 2016

TO: Each Member  
Board of Retirement

FROM: Disability Procedures & Services Committee  
Vivian H. Gray, Chair  
William de la Garza, Vice Chair  
Yves Chery  
Les Robbins  
David Muir, Alternate

FOR: July 6, 2016 Board of Retirement Meeting

SUBJECT: **CONSIDER APPLICATION(S) FOR LACERA PANEL OF EXAMINING PHYSICIAN(S)**

On June 1, 2016, the Disability Procedures & Services Committee reviewed the attached application for the LACERA Panel of Examining Physicians.

The application package has been reviewed by the Committee. After discussion, the Committee voted to accept the application of the following physician and submit to the Board of Retirement for approval to the LACERA panel.

**IT IS THEREFORE RECOMMENDED THAT** the Board approve the following physician to the LACERA Panel of Physicians for the purpose of examining disability retirement applicants.

**NOAM DRAZIN, M.D. - Board Certified Oncologist**


Attachments

VG:RC/mb



May 17, 2016

TO: Disability Procedures & Services Committee  
Vivian H. Gray, Chair  
William de la Garza, Vice Chair  
Yves Chery  
Les Robbins  
David Muir, Alternate

FROM: Ricki Contreras, Manager   
Disability Retirement Services

FOR: June 1, 2016, Disability Procedures and Services Committee Meeting

SUBJECT: **CONSIDER APPLICATION OF NOAM DRAZIN, M.D., AS A LACERA  
PANEL PHYSICIAN**

On April 29, 2016, Debbie Semnanian interviewed Noam Drazin, M.D., a physician seeking appointment to the LACERA Panel of Examining Physicians.

Attached for your review and consideration are:

- Staff's Interview Summary and Recommendation
- Panel Physician Application
- Curriculum Vitae
- Sample Report(s).

**IT IS THEREFORE RECOMMENDED THAT THE COMMITTEE** accept the staff recommendation to submit the application of Noam Drazin, M.D., to the Board of Retirement for approval to the LACERA Panel of Examining Physicians.

Attachments

JJ:RC/mb

NOTED AND REVIEWED:


  
\_\_\_\_\_  
JJ Popowich, Assistant Executive Officer

Date: 5/23/16



May 17, 2016

TO: **Ricki Contreras, Manager**  
Disability Retirement Services

FROM: **Debbie Semnanian**   
Disability Retirement Specialist Supervisor

**Debbie Semnanian, WCCP**  
Supervising Disability Retirement Specialist

SUBJECT: **INTERVIEW OF ONCOLOGIST APPLYING FOR  
LACERA'S PHYSICIAN'S PANEL**

On April 29, 2016, I interviewed **Noam Drazin, M.D.** at his office at 8631 W. Third Street, Suite #540E, Los Angeles, CA 90048. The office space is located within the Cedars-Sinai Medical Center complex, with patient paid parking in the lot underneath the well-maintained high-rise building.

Dr. Drazin is Board Certified in both internal medicine and oncology, and has been in private practice for over ten years. Dr. Drazin's office has four examination rooms. He estimates that 90 percent of his practice is devoted to patient treatment, while the other 10 percent of his time is devoted to IME evaluations for other retirement systems. Dr. Drazin shares office space with five other physicians; three internists and two gastrointestinal specialists. Dr. James Sherman, who is a LACERA panel internal physician, also works at this office.

As referenced in his Curriculum Vitae, Dr. Drazin graduated from Albert Einstein College of Medicine, New York, with his Medical Degree in 1997. He completed an Internship, Residency, and Chief Residency/Junior Faculty (all of these in internal medicine) at Cedars Sinai Medical Center, Los Angeles in 2001. Dr. Drazin completed a Fellowship in Medical Oncology and Hematology at Cedars Sinai Medical Center in 2004. From 2004 to present, Dr. Drazin has been in private practice at Cedars Sinai Medical Center, Samuel Oschin Comprehensive Cancer Center, Department of Hematology/Oncology.

The office was clean with ample seating. A handicap accessible restroom is located within the office. Dr. Drazin has an office staff of three office personnel.

Staff reviewed the LACERA Disability Retirement procedures and expectations in its evaluation of County Employees applying for both service connected and non-service connected disability retirements. The importance of preparing impartial and non-discriminatory reports that are clear and concise and address issues of causation and incapacity was discussed with the doctor. He understood that he

would adhere strictly to the HIPAA laws that would also apply for LACERA reports. Staff reviewed with Dr. Drazin the Panel Physician Guidelines for evaluating LACERA applicants and defined the relationship between workers' compensation and disability retirement. Staff discussed the need to rely on his own objective and subjective findings rather than the opinions of previous physician reports and/or comments.

Dr. Drazin agreed to adhere to LACERA's standard of having his evaluation reports sent to us within 30 days of examination. Staff confirmed that Dr. Drazin is agreeable with accepting payment pursuant to LACERA's contract and billing procedures. Dr. Drazin was informed that if he is approved by the Board to be on our panel of physicians, he is required to contact the specialist assigned to the case for approval of any special tests or extraordinary charges. He has also been advised of the requirement to immediately notify LACERA if any license, Board certification, or insurance coverage is lapsed, suspended or revoked. He was informed that a Quality Control Questionnaire is sent to each applicant regarding their visit.

**RECOMMENDATION**

Based on our interview and the need for his specialty, staff recommends Dr. Drazin's application be presented to the Board for approval as a LACERA Panel Physician.



300 N. Lake Ave., Pasadena, CA 91101 ■ Mail to : PO Box 7060, Pasadena, CA 91109-706 626/564-2419 • 800/786-6464

**GENERAL INFORMATION** Date 3-31-16

Group Name:	Physician Name: <u>NOAM DRAZIN, MD</u>
I. Primary Address: <u>P.O. Box 1157 SANTA MONICA, CA 90406</u>	
Contact Person <u>RICK ALBERT</u>	Title <u>GENERAL MANAGER</u>
Telephone: <u>310-593-4920 X102</u>	Fax <u>310 392-0831</u>
II. Secondary Address <u>8631 W. THIRD ST #540 E LA, CA 90048</u>	
Contact Person <u>RICK ALBERT</u>	Title
Telephone <u>310 593-4920 X102</u>	Fax

**PHYSICIAN BACKGROUND**

Field of Specialty <u>INTERNAL MEDICINE</u>	Subspecialty <u>ONCOLOGY</u>
Board Certification <input checked="" type="checkbox"/> Yes <input type="checkbox"/> No	License #
Expiration Date	

**EXPERIENCE**  
Indicate the number of years experience that you have in each category.

**Evaluation Type**

I. Workers' Compensation Evaluations

<input type="checkbox"/> Defense	How Long? _____	<input checked="" type="checkbox"/> IIME	How Long? <u>5 mos</u>
<input type="checkbox"/> Applicant	How Long? _____	<input type="checkbox"/> QME	How Long? _____
<input checked="" type="checkbox"/> AME	How Long? <u>5 mos</u>		

II.  Disability Evaluations      How Long? 5 mos

For What Public or Private Organizations? SBCERA + SBCERS

Currently Treating?  Yes  No

Time Devoted to:                      Treatment      90 %                      Evaluations      10 %

<b>Estimated Time from Appointment to Examination</b> <input type="checkbox"/> 2 weeks <input checked="" type="checkbox"/> 3-4 Weeks <input type="checkbox"/> Over a month	<b>Able to Submit a Final Report in 30 days?</b> <input checked="" type="checkbox"/> Yes <input type="checkbox"/> No
---	---


**LACERA's Fee Schedule**

Examination and Initial Report by Physician	\$1,500.00 flat fee
Review of Records by Physician	\$350.00/hour
Review of Records by Registered Nurse	\$75.00/hour
Supplemental Report	\$350.00/hour

Other Fees	
Physician's testimony at Administrative Hearing (includes travel & wait time)	\$350.00/hour
Deposition Fee at Physician's office	\$350.00/hour
Preparation for Expert Testimony at administrative Hearing	\$350.00/hour
Expert Witness Fees in Superior or Appellate Court	\$3,500.00 half day \$7,000 full day
Physician agrees with LACERA's fee schedule?	Yes No
Comments	

Name of person completing this form:

RICK ALBERT Title: PHYSICIAN'S REPRESENTATIVE  
(Please Print Name)

Physician Signature:  Date: 4/4/16

FOR OFFICE USE ONLY	
Physician Interview and Sight Inspection Schedule	
Interview Date: <u>4/28/16</u>	Interview Time: <u>1:00pm</u>
Interviewer: <u>Walter Semmanian</u>	

# First Medical Experts, Inc.

(310) 593-4920  
Fax: (310) 392-0831  
[www.FirstMedicalExperts.com](http://www.FirstMedicalExperts.com)  
[Rick@FirstMedicalExperts.com](mailto:Rick@FirstMedicalExperts.com)

**Name:** Drazin, Noam, Z. , MD

**Personal History:** Work Address:  
200 N. Robertson Blvd, Suite #300  
Beverly Hills, CA 90211  
[noam.drazin@cshs.org](mailto:noam.drazin@cshs.org)

Home Address:  
9539 Oakmore Road  
Los Angeles, CA 90035  
310-876-1250 (h)  
310-948-1252 (c)  
Date of Birth; Place of Birth: , Los Angeles, CA  
Citizenship: USA  
Marital Status: Married

**Education:** B.A. – Boston University, Boston, MA  
May 1992, magna cum laude

M.D. – Albert Einstein College of Medicine, NY, NY  
June 1997

Internship  
Cedars Sinai Medical Center, Los Angeles, CA 1997  
Internal Medicine

Residency  
Cedars Sinai Medical Center, Los Angeles, CA 1998-2000  
Internal Medicine

Chief Residency/Junior Faculty  
Cedars Sinai Medical Center, Los Angeles, CA 2000-2001  
Internal Medicine

Fellowship  
Cedars Sinai Medical Center, Los Angeles, CA  
UCLA Medical Center/San Fernando Valley, Sylmar, CA  
2001-2004  
Medical Oncology  
Hematology

**Licensure:** California Medical License – A066067 (current, originally issued 1998)  
Drug Enforcement Agency Practitioner License - BD5937187 (current, c.1998)

**Board Certification:** American Board of Internal Medicine (Board Certified) – valid through 2020  
American Board of Medical Oncology (Board Certified) – valid through 2024  
American Board of Hematology (Board Eligible) – date of eligibility 2004

**Professional Experience:** Present Position  
**Cedars Sinai Medical Center, Los Angeles, CA**  
Samuel Oschin Comprehensive Cancer Center  
Department of Hematology/Oncology  
Attending Physician in good standing  
**2004-Present (10+ years in private practice)**

**David Geffen/UCLA School of Medicine, Los Angeles, CA**

Department of Internal Medicine  
Division of Hematology/Oncology  
Clinical Instructor  
2004-Present

**Cedars Sinai Medical Group/Medical Group of Beverly Hills, Inc. Beverly Hills, CA**

Department of Hematology/Oncology  
Private practice Physician  
2004-Present

Previous Positions:

Hospice Care of the West, Inc., Los Angeles, CA  
*Consulting Physician*  
2008-2010

Cedars Sinai Medical Group, Beverly Hills, CA

*Urgent Care physician*  
1998-2001

Colony Care Partners, Malibu, CA

*Urgent Care Physician*  
1998-2001

Concentra Healthcare, Los Angeles, CA

*Urgent Care Physician*  
1998-2001

Cedars Sinai Medical Center, Los Angeles, CA

Department of Internal Medicine, Division of Endocrinology  
*Research Associate*  
1992-1993

Cedars Sinai Medical Center, Los Angeles, CA

Department of Internal Medicine, Division of Endocrinology  
*Research Assistant*  
Summer 1991  
Summer 1992

**Professional  
Activities:**

Committee Service

-Department of Internal Medicine – Performance Improvement Committee (PIC)  
Cedars Sinai Medical Center, Medical Staff  
Elected by medical staff vote, 2011

•CSlink Advisory Board – Electronic Medical Record committee

Cedars Sinai Medical Group

Collaboration with physician and hospital leadership with implementation and optimization  
Elected 2010

•Transfusion Committee

Cedars Sinai Medical Center, Department of Blood bank  
Utilization of appropriate transfusion protocols

•CSlink – SuperUser MD

Cedars Sinai Medical Center, Information Systems

Assist in implementation and utilization of inpatient EMR (2011-Present)



Community Service

American Society of Clinical Oncology (Member)

American Medical Association (Member)

American College of Physicians (Member)

California Medical Society (Member)

Los Angeles County Medical Association (Member)

Medical Oncology Association of Southern California (Member)

Samuel Oschin Comprehensive Cancer Institute at Cedars Sinai (Member)

**Honors and Special Awards:**

Alpha Omega Alpha, National Honor Society (elected 1996)

Member of Neurosurgery **Center of Excellence** at Cedars Sinai (current member)

Member of Colorectal Cancer **Center of Excellence** at Cedars Sinai (current member)

Patient customer service award ("Gordon") – 2010, 2011, 2012, 2013

**Lectures/Presentations:**

Medicine Grand Rounds – Cedars Sinai Medical Center. December 16, 2005. Gastric and Esophageal Cancer – Update.

Medicine Grand Rounds – Cedars Sinai Medical Center. January 11, 2008. Genetic predisposition to Cancer

CME – Monthly Meeting, Cedars Sinai Medical Group, January 10, 2010, BRCA1/2 mutations and introduction to medical genetic testing.

Nurse education Meeting, Cedars Sinai Medical Group, June 2012. Cancer and the Aging population.

Nurse education Meeting. Cedars Sinai Medical Group, August 2012. Oncologic advances in metastatic melanoma.

**Advisory Boards:**

Eli Lilly, Inc.

Thoracic Virtual Advisory Board - October 2014

Ladies Bikur Cholim Board of Directors

Charitable care delivery

**BIBLIOGRAPHY/PUBLICATIONS:**

"Neurosurgical management for complicated catastrophic antiphospholipid syndrome," by Doniel Drazin, Westley Phillips, Ali Shirzadi, Noam Drazin, David Palestrant and Wouter Schievink  
**J Clin Neurosci. 2014 Apr;21(4):680-3. doi: 10.1016/j.jocn.2013.05.016. Epub 2013 Aug 8**

Drazin, Doniel, Noam Z. Drazin, Amin J. Mirhadi, and Eli M. Baron. "Classification, Staging, and Management of Spinal Tumors." Decision Making in Spinal Care (2012): 371. (Chapter 48)

T. Patel, N. Drazin, A. Nguyen, H. Hool, R. Agajanian, A. Pakanati, S. Song, N. Feldman, L. Pinter-Brown, L. Powell. Treatment of Burkitt Lymphoma: A Single Institution's Experience. PASCO 2005. Abstract #6742.

Herman VS, Drazin N, Nepomuceno L, and Melmed S Normal pituitary growth hormone gene restriction analysis in acromegaly. Clinical Research. Volume 40, Number 1, February 1992. [abstract]

Herman VS, Drazin NZ, Gonsky R, and Melmed S. Molecular screening of pituitary adenomas for gene mutations and rearrangements. Journal of Clinical Endocrinology and Metabolism. 77(1):50-55, 1993 Jul.

**RESEARCH CONDUCTED:**

"The Utility of MIBI and FDG scanning in the detection of non-hodgkins lymphoma" Michael Lill, M.D., Alan Waxman. Cedars-Sinai Medical Center, Los Angeles, CA  
Research conducted: 1999-Present

"Characterization and cloning of the SSAT gene in microsporidia species E. cuniculi" Louis Weiss, M.D., M.P.H. Albert Einstein College of Medicine, Bronx NY.  
Research Conducted 1996-1997

"T. Vaginalis: In vitro drug assays of metronidazole resistant strains using novel therapeutics." Murray Wittner, M.D. Ph.D. Albert Einstein College of Medicine,  
Research conducted 1996-1997

Noam Z. Drazin, MD

Sample  
Report  
#1

Board Certified, Internal Medicine  
Board Certified, Medical Oncology

[REDACTED]

[REDACTED]  
[REDACTED]  
[REDACTED]  
[REDACTED]

ATTENTION: [REDACTED]

Patient: Xxx Xxxxx (SS# xxx-xx-xxxx)

Examination Date: [REDACTED]

**Comprehensive Consultation Report**

The patient presents for evaluation on behalf of the [REDACTED] Employees Retirement System regarding his current diagnosis, treatment and incapacity from metastatic melanoma and current treatment.

Job Description:

Mr. Xxxx is a [REDACTED]-year-old man who has been working as a [REDACTED] and subsequently a [REDACTED] for the past 30 years. His usual tasks that he was responsible for were: Supervising staff, performing inspections, managing maintenance schedules, coordinating remodel projects, maintaining equipment inventory, coordinating repairs, staff training, records maintenance, and ensuring staff and building safety. Occasionally he was responsible for attending meetings, filling in for other supervisors, and responding in emergency situations.

History of Illness:

[REDACTED] Application Summary. The applicant claims to be permanently incapacitated to perform his duties as a [REDACTED] due to his cancer diagnosis, specifically stage IV metastatic melanoma. He claims his condition is the result of cumulative trauma from a significant amount of sun exposure while working outdoors. Current symptoms include fatigue, sluggishness/lethargy, inability to think clearly, lack of concentration, lack of energy, lack of stamina, moderate to severe muscle aches, physical and mental weakness and difficulty sleeping.

## Noam Z. Drazin, MD

Board Certified, Internal Medicine  
Board Certified, Medical Oncology

Claimed Functional Limitations: Unable to think clearly and effectively perform the job duties due to the above symptoms; interact with the public or co-workers; plan projects and coordinate with staff and vendors; maintain pace necessary for work; meet deadlines and regularly and consistently present himself for work.

History: Earliest treatment records are unfortunately unavailable, but according to his deposition testimony, applicant had three melanoma spot removals prior to [REDACTED] and according to the [REDACTED] report of dermatologist Gary Novatt, applicant also had a skin cancer removed in approximately [REDACTED]. During this same consultation with Dr. Novatt, applicant reported a recurrence of skin cancer on his nose, and spots on his sternum and upper back. Dr. Novatt diagnosed recurrent basal cell carcinoma (BCC), and two superficial BCCs. He excised the sternum and back lesions completely and performed a punch excision on the nose. All specimens were positive and surgery to remove the nose lesion was performed on [REDACTED] by Dr. Richard Hammond.

Applicant returned to Dr. Hammond the following year and then 16 months later for screening and was found to be clear of skin cancers. He was strongly advised by Dr. Hammond on [REDACTED] to wear sunscreen due to the significant change of a second BCC. He was next screened by Dr. Peter Ford on [REDACTED] who found no evidence of skin cancer. The records are silent regarding any screenings or recurrences until [REDACTED] when applicant consulted dermatologist Mark Loan about a lesion on his left ear. Dr. Logan removed it and biopsy revealed it to be squamous cell carcinoma. Applicant next appeared before Dr. Logan on [REDACTED] for evaluation of a few lesions. A pearly nodule on the upper left arm was removed and biopsied, revealing basal cell carcinoma. Nearly three years later, [REDACTED], applicant again consulted Dr. Logan for screening. A black, irregular nodule was shaved and biopsied. It was determined to be a malignant melanoma in situ and was excised on [REDACTED]. Applicant began to have more regular screenings. On [REDACTED] two lesions next to the nose were found to be benign. However, on [REDACTED], lesions from the head, abdomen and back were found to be malignant melanoma and basal cell carcinoma. They were surgically removed the following month. The removal of the abdominal lesion, on the left flank near the groin, included removal and biopsy of a sentinel lymph node. It was diagnosed as metastatic melanoma, BRAF mutation not detected.

Applicant then began treating with oncologist Mukul Gupta on [REDACTED] who ordered a PET scan and recommended chemotherapy. After the scan, surgery was performed by Dr. Rosa Choi to remove lymph nodes in the left groin. These lymph nodes were negative for metastatic melanoma. Applicant reported to Dr. Choi on [REDACTED] and he was recovered from the surgery and was feeling well. On [REDACTED], applicant returned to Dr. Gupta to discuss chemotherapy. He was started on a regimen of weekly adjuvant subcutaneous interferon pegylated. Applicant reported to Dr. Gupta on [REDACTED] that he had two to three days of fatigue and joint pains after the injections, but no other side effects. Applicant continued skin screenings with Dr. Logan. On [REDACTED] a couple lesions on the mid upper back (nape of the neck) were shaved, biopsied and diagnosed as malignant melanoma. Dr. Choi excised them on [REDACTED]. Further diagnosis found residual melanoma in situ, but negative for invasive melanoma.

## Noam Z. Drazin, MD

---

Board Certified, Internal Medicine

Board Certified, Medical Oncology

Another lesion on the left upper arm on [REDACTED] was found to be malignant melanoma in situ. It was completely excised by Dr. Logan

on [REDACTED]. At the next screening on [REDACTED] no suspicious lesions were found. On [REDACTED] Dr. Logan excised a nodule from applicant's right ear. It was determined to be Chondrodermatitis Nodularis Helicis (CNH). Applicant was referred to endocrinologist Mark Wilson on [REDACTED] after a PET scan, [REDACTED], showed evidence of a possible nodule on his thyroid. Applicant also complained of increasing fatigue, muscle pain after chemotherapy and worsening memory to Dr. Wilson. He did report more energy in the morning and the ability to walk 3.5 miles daily. Applicant continued to report substantial daytime fatigue at the next visit, [REDACTED], despite having begun testosterone replacement therapy which should have increased his energy. Applicant reported to Dr. Gupta on [REDACTED] that after a recent iron infusion he felt really good and had increased energy and so Dr. Gupta recommended continuing to receive them. On [REDACTED], Dr. Gupta discussed with applicant a lesion at the porta hepatis that was being monitored since its discovery on a PET scan. Subsequent scans showed a gradual enlarging; biopsy determined it to be metastatic melanoma with BRAF mutations detected and he was referred to surgery for removal, which was performed on [REDACTED].

Dr. Gupta started him on Ipilumimab (Yervoy) therapy after his next visit, [REDACTED]. After his first cycle, applicant reported headaches, but no nausea. A recent skin screening by Dr. Logan ([REDACTED]) did not find any suspicious lesions. On [REDACTED], applicant reported additional fatigue, aches and pains since starting Yervoy but there were no abnormal lab findings. After the fourth and final cycle, applicant reported diminishing side effects. He was started on Leuproline as of [REDACTED] but was cautioned that if PET scans showed worsening disease he would be switched to Keytruda. Applicant reported to Dr. Gupta on [REDACTED] that after the first leuproline cycle he felt additional fatigue. He was, however, able to walk 3.5 miles per day. A shave biopsy from applicant's left forearm on [REDACTED] was positive for squamous cell carcinoma. At the next visit to Dr. Gupta, [REDACTED], applicant was referred to radiation after a restaging CT found enlarging splenic tumors. Applicant consulted radiation oncologist George Chen-Ho Cheng on [REDACTED]. Dr. Cheng concluded that the amount of radiation necessary was prohibitive, and that laparoscopic splenectomy would be more useful.

Applicant returned to Dr. Gupta on [REDACTED] to begin Keytruda treatment. He was referred to surgery and consulted Dr. James Dunn, who performed the laparoscopic splenectomy on [REDACTED]. Pathology determined the samples to be metastatic melanoma that was similar to applicant's prior metastatic melanoma. Applicant then returned for his second cycle of Keytruda and saw Nurse Practitioner Hangama Abassi on [REDACTED]. He reported he tolerated the splenectomy well. He returned for subsequent cycles without any complaints other than increasing fatigue. At his next skin screening with Dr. Logan, no suspicious lesions were found. The next restaging PET/CT scan on [REDACTED] did not reveal any new lesions. Applicant returned for his next cycle on [REDACTED] and reported to NP Abassi that he had good energy, and was exercising daily. On [REDACTED] prior to his 10<sup>th</sup> Keytruda treatment, applicant reported to NP Abassi that in addition to body aches, the hot flashes were occurring several times during the day and night. In his [REDACTED] deposition, applicant testified that he has not been told by any doctor that his

## Noam Z. Drazin, MD

---

Board Certified, Internal Medicine

Board Certified, Medical Oncology

cancer was a result of his County employment. He also testified that his mother had melanoma and would continually have in office removal of melanoma spots.

Job History: Applicant's [REDACTED] employment began on [REDACTED]. In his application, applicant states that he spends 25% of his time in the office and 75% of his time walking job sites, working at job sites and supervising staff. According to his supervisor, during the time outside of the office, applicant spends 50% of his time outdoors (which roughly translates to 25% of the workday). Applicant's own estimation is also that 50% of his time in the field is spent outdoors. He was taken off work as of [REDACTED] to undergo surgery and did not return. Summary of applicant's medical treatment was included.

[REDACTED] - [REDACTED] - Application for Disability Retirement. Most recent county job title was [REDACTED]. Date of Hire [REDACTED]. Date Last Worked [REDACTED]. Years of service, 31. He claims cumulative trauma injury resulting in cancer - Stage IV Metastatic Melanoma. Applicant believes that his [REDACTED] employment caused or aggravated his disabling condition. He states that, "I worked a significant amount of time outdoors during my 30+ year employment with the County. I did not receive education, training or sun protection in the form of lotion, hats, clothing or gloves until it was too late to prevent the development of my condition." Date of Injury: [REDACTED]. He states that he suffers daily from fatigue, sluggishness, inability to think clearly, lack of concentration, lack of energy and lethargy, lack of stamina, moderate to severe muscle aches, physical and mental weakness, difficulty sleeping. He states that his condition is worsening and prognosis is not good. Applicant is currently being treated with Keytruda and chemotherapy. It was noted that his incapacitating condition was the result of non-industrial sun exposure. He states that his symptoms are the same as for his industrial injury. He states that the only condition he suffers from is the cancer, which he believes arose out of sun exposure. The applicant noted that his job duties for the last 10 years have been fairly consistent. He spends 75% of his time walking job sites, working at job sites, supervising staff at job sites and coordinating the work (Project Management). The remaining 25% of his work is in the office doing paperwork, phone calls, vendor coordination and meetings. His work requires "hands on" supervision. His Stage IV Melanoma and chemotherapy present a danger to himself and others on the job site. He is unable to think clearly and effectively perform his duties due to his fatigue, sluggishness, physical and mental weakness, lack of energy, lack of stamina, inability to think clearly or concentrate properly, interact with the public or co-workers, plan projects, and coordinate with staff and vendors, among many other duties. He is pretty wiped out and cannot maintain a workpace or meet deadlines. He is unable to regularly and consistently present himself for work on a daily basis. His course of treatment requires his full attention. In [REDACTED] [REDACTED] he was diagnosed with Stage 3 Melanoma. He underwent multiple surgeries over a two-month period, and managed to will himself back to work in [REDACTED]. In [REDACTED] his cancer metastasized and progressed to stage IV. He was started on a new chemotherapy regime which failed and he developed a tumor and underwent surgery in [REDACTED]. Since then, he has started a new chemotherapy regimen. He has been advised that his condition will not likely improve. He cannot think of anything that his employer can do that he believes would enable him to perform his duties. He was

## Noam Z. Drazin, MD

---

Board Certified, Internal Medicine

Board Certified, Medical Oncology

asked to explain whether he requested any reasonable accommodation from the County and, if so, how did the County deal with his request and he replied, "The County allowed me to return after my cancer diagnosis and surgeries and worked with me as best it could

to allow me to perform my job. In hindsight, I question whether I was actually thinking clearly and effectively to perform my work during this period, although no one at the County implied otherwise."

██████████ – ██████████ ██████████ – Treating Physician's Statement. Physician: Mukul Gupta, M.D. The doctor has treatment the patient every three weeks for three years. The applicant's incapacitating condition is metastatic melanoma. His limitations include fatigue, nausea, vomiting, and pain. Side effects from chemotherapy. Disability is permanent. The examiner recommends full disability because the patient is on neoplastic chemotherapy. The incapacitating condition is metastatic melanoma to spleen.

██████████ – ██████████ ██████████ Job Factors Form. Job Classification: ██████████. Work hours: full time (40 hours/week), applicant works Monday-Friday from 8 a.m. to 5 p.m. with a one-hour lunch break and two 15 minutes breaks. Rare overtime. Applicant is on call 24/7 for emergencies, but these are very rare. Usual tasks include supervising staff; performing inspections, managing maintenance schedules, coordinating removal projects, maintaining equipment inventory, coordinating repairs, staff training, maintaining records and ensuring staff and building safety. Rare or infrequent tasks include attending meetings and trainings, filling in for other supervisors and emergency response. Physical Demands: Daily intermittent lifting/carrying under five pounds and rare lifting/carrying 6-51+ pounds; daily pushing/pulling, rare reaching above shoulders, occasional and/or rare stooping or bending, rare kneeling, rare crawling, rare climbing, daily sitting, daily standing, daily walking/even ground, infrequent walking on uneven ground, occasional and/or rare twisting, daily driving for short intervals, daily grasping, daily handwriting, intermittent keyboarding, and daily wrist use side to side and up and down. Reasonable Accommodation: Physical modifications – ergonomic keyboard and track ball mouse, adjustable computer screen, ergonomic pens, electric stapler and hole punch, ergonomic stapler removal, phone headset and swivel chair and floor mat. Items may be relocated to eliminate or the need to reach above shoulders or to bend/stoop. Modified physical demands include a raised writing surface to allow writing in a standing position. Also able to adjust computer screen and keyboard to various heights to allow use in either a standing or sitting position.

██████████ – Medical History. The patient has a history of left and right torn Achilles tendons. He does not have a difficulty with hearing or vision. He does not take any medications. He does not have any defect, deformity or disease which may interfere with his work. He had a positive chest x-ray in ██████████

██████████ – Gary Novatt, M.D. – Dermatology Visit. The patient is concerned about a skin cancer on the left side of his nose. About seven years he had a skin cancer reviewed by Dr. Clark. He thinks it is back.

## Noam Z. Drazin, MD

---

Board Certified, Internal Medicine

Board Certified, Medical Oncology

He is also concerned about a spot on his sternum, as well as his left upper back. Impressions: Recurrent BCC, left medial canthus. Superficial BCCs x 2; sternum and back. Plan: 4 mm punch excision.

██████████ - Gary Novatt, M.D. - Pathology Report. Specimens: Punch biopsy from the left malar area. Shave biopsy from the upper back followed by ED&C. Diagnosis: BCC.

██████████ - Richard Hammond, M.D. - Dermatology Visit. The patient was referred to the examiner for MOHS. ██████████ years ago he had a basal cell epithelioma removed from the left upper lateral nose. It has recurred. Biopsy was sclerosing basal cell. He is scheduled for MOHS.

██████████ - Richard Hammond, M.D. - MOHS Microscopic Controlled Surgical Note. First stage - Pathology revealed tumor on both pieces. Second stage - It was cut into four pieces, tumor on three. Third stage - It was cut clear. The resulting defect was a little over 2 cm in diameter and extended from the supramedial cheek up onto the nose.

██████████ - Richard Hammond, M.D. - Progress Report. Dressing changed, looks fine.

██████████ - Richard Hammond, M.D. - Progress Report. Alternate sutures removed, especially some near the tip of the graft, to allow it to pull back just a little, and then alternate sutures under the eye and along the side of the nose removed. A little bit of redness in the area. Diclox 250 was prescribed.

██████████ - Richard Hammond, M.D. - Progress Report. Sutures removed, steri-stripped. Looks good.

██████████ - Richard Hammond, M.D. - Progress Report. The patient looks very good. Flattening out nicely now, there is still a little web along the side of the upper nose that should soften over time.

██████████ - Richard Hammond, M.D. - Progress Report. No evidence of recurrence of tumor on the face. There is an actinic keratosis left shin treated with liquid nitrogen. The examiner sees nothing of any concern.

██████████ - Richard Hammond, M.D. - Progress Report. The patient is totally clear; he was looked over all his skin from head to toe. There are a few scattered seborrheic keratoses on the legs. He is still getting too much sun. He was strongly encouraged sunscreen and pointed out the significant chance of a basal cell carcinoma.

██████████ - Peter Ford, M.D. - Dermatology Visit. The patient presented for recheck for skin cancers and notes a rough spot on his right ear. On examination, there is a keratotic papule on the right ear. Assessments: History of skin cancer, none today. Actinic keratosis on right ear, which was treated with cryotherapy. Plan: Post cryotherapy wound care.

██████████ - Mark Logan, M.D. - Dermatology Visit. The patient presented for evaluation of several lesions. He has a 2 cm nodule on the posterior neck which bothers him when he sleeps. He will schedule a 30-minute surgery time for removal. This is likely an epidermal cyst. The left lateral helix has a 7 mm keratotic papule, diagnosis: rule out squamous cell carcinoma. Shave biopsy sent for pathology. He also



## Noam Z. Drazin, MD

---

Board Certified, Internal Medicine

Board Certified, Medical Oncology

has five erythematous scaly patches of the forearms. Diagnosis: Actinic keratoses. Treatment with liquid nitrogen.

██████████ – Mark Logan, M.D. – Pathology Report. Specimen: Left lateral helix shave biopsy. Diagnosis: Invasive well differentiated squamous cell carcinoma, at least 1 mm in depth, extending to the deep dermal margin.

██████████ – Mark Logan, M.D. – Progress Report. The patient was seen for a few lesions. He has an 8-mm pearly nodule on the left upper lateral arm and an erythematous scaly patch on left neck. Diagnoses: Rule out basal cell carcinoma – shave biopsy sent for pathology. Actinic keratosis – treatment with liquid nitrogen.

██████████ – ██████████ – Anne Wilkerson, M.D. – Pathology Report. Specimen: Skin, left upper arm, shave biopsy. Diagnosis: Basal cell carcinoma, ulcerative, pigmented, nodular/micronodular type with morpheaform features with multicentric superficial components, extending to the deep and peripheral dermal margin.

██████████ – Mark Logan, M.D. – Progress Report. The patient's exam of the trunk, extremities and face shows: The right upper back has a 1-cm black irregular nodule with diagnosis of rule out melanoma and eight erythematous scaly patches of the cheeks, forehead, ears, and right dorsal hands with diagnosis of actinic keratoses. Deep shave biopsy was sent for pathology. Actinic keratoses were treated with liquid nitrogen.

██████████ – ██████████ – Hugh Byers, M.D. Specimen: Skin, right upper back, shave biopsy. Diagnosis: Malignant melanoma in situ, superficial spreading type, Clark's level I, narrowly excised.

██████████ – Mark Logan, M.D. – Progress Report. The patient presented for excision of biopsy-proven melanoma in situ. The original lesion was 1 cm on the right upper back. The area was shaved, marked, and infiltrated with lidocaine and epinephrine and then cleansed. The lesion was excised and the wound was closed in two layers. Dressing was placed.

██████████ – ██████████ – Hugh Byers, M.D. – Pathology Report. Specimen: Skin, right upper back, excision. Diagnoses: Residual lentiginous melanocytic proliferation with severe atypia, consistent with residual radial growth phase of malignant melanoma in situ, superficial type, completely excised. Adjacent central re-epithelializing ulcer with subjacent early scar formation, completely excised. Small separate incidental intradermal melanocytic nevus, close to a peripheral margin.

██████████ – Mark Logan, M.D. – Progress Report. The patient presented for suture removal; area healing nicely without evidence of infection.

## Noam Z. Drazin, MD

---

Board Certified, Internal Medicine

Board Certified, Medical Oncology

██████████ – Mark Logan, M.D. – Progress Report. There have been two lesions in the last two months: Right inferior melolabial fold, 5 mm pearly nodule, BCC shave biopsy and right nasal root with 4 mm crusty papule, SCC shave biopsy.

██████████ – ██████████ – Hugh Byers, M.D. – Pathology Report. Specimens and Diagnoses: Skin, right melolabial fold, shave biopsy: Benign bulbous endophytic squamous epithelial proliferation consistent with benign adnexal tumor and suggestive of trichilemmoma, present at deep biopsy margin. Skin, right nasal root, shave biopsy: Comedone with mild perifollicular lymphocytic infiltrate. Solar elastosis and telangiectasia.

██████████ – Mark Logan, M.D. – Progress Report. The patient's skin exam shows the following: Left lateral abdomen 1.4 cm black/red irregular nodule, rule out melanoma; right lateral occipital scalp 8 mm pearly nodule; and left lateral back 8 mm dark brown irregular macula, irregular nevus. Plan: Shave biopsies.

██████████ – ██████████ – Bruce Ragsdale, M.D. – Pathology Report. Specimens and Diagnoses: Skin, left lateral abdomen, shave biopsy: Malignant melanoma, Clark's level superficial IV, 1.4 mm in greatest (Breslow) thickness, arising in a dysplastic nevus, all narrowly excised in profiles examined. Skin, right lateral occipital scalp, shave biopsy: Basal cell carcinoma, invasive, biopsy. Skin, left lateral back, shave biopsy: Malignant melanoma, superficial spreading type, Clark's level I (in situ), arising in a dysplastic melanocytic nevus, with focal extension to the shave biopsy rim.

██████████ – Mark Logan, M.D. – Progress Report. The patient's 8 mm biopsy proven melanoma in situ, left lateral back, was cleansed and excised. Wound was closed. The 8 mm biopsy proven BCC, right lateral occipital scalp was C&D'd x 3. He will undergo abdomen melanoma surgery tomorrow morning.

██████████ – ██████████ – Hugh Byers, M.D. – Pathology Report. Specimen: Skin, left lateral back, excision. Diagnoses: Central scar consistent with previous surgical procedure, completely excised. No residual lesion represented. Incidental separate small intradermal melanocytic nevus, completely excised.

██████████ – ██████████ – Rosa Choi, M.D. – Operative Report. Procedure: A 2 cm wide excision of left flank malignant melanoma with primary closure and sentinel lymph node mapping and biopsy to the left groin. Postoperative Diagnosis: Left flank melanoma.

██████████ – Santa Barbara Cottage Hospital – David Martin-Reay, M.D. – Pathology Report. Specimens and Diagnoses: Sentinel lymph node, left groin: Metastatic melanoma to a single lymph node. Wide excision, melanoma, left flank: Tiny residual focus of an atypical intraepidermal melanocytic proliferation adjacent to fibrosing granulation tissue of a prior biopsy site. Margins negative for in situ or invasive melanoma. Left groin lymph node (metastasis): BRAF mutation not detected, genotype result: Wild-type.

## Noam Z. Drazin, MD

---

Board Certified, Internal Medicine

Board Certified, Medical Oncology

██████████ – Mukul Gupta, M.D. – Office Visit. The patient presented for advice only regarding stage II malignant melanoma. Active problems include melanoma in situ, right upper back, 2010 and malignant melanoma of groin. Current medications included Flonase, Naprosyn and Zantac. There is no known family history of melanoma. He was sunburned as a child. Review of systems was significant for mild pain at the surgical sites, however, they are, in general, healing. He has chronic swelling of the left lower extremity which is not increased. All wounds are clean, dry and intact sutured and dressed. He has multiple skin lesions in the left lower extremity. PET scan results are pending. It does not look like there is any obvious metastatic disease. There is some uptake in the legs, which could be due to his history of deep vein thrombosis and varicosities. Assessment: Malignant melanoma of groin. Plan: Referral to UCLA for consideration of any adjuvant clinical trial.

██████████ – Sean Snodgrass, M.D. – PET/CT Whole Body. Impression: Tracer activity in the left groin

correlates with the recent excisional biopsy site. There are areas of low level tracer activity involving the subcutaneous soft tissues along the medial aspect of the mid and lower left calf and in the posterior aspect of the upper left calf. On correlation with the CT images, there are serpiginous tubular structures in these areas, and these could represent venous varicosities. However, correlation with physical exam is necessary to exclude melanoma involvement at these sites. Several other areas of tracer activity within both lower extremities are compatible with vascular uptake and activity related to osteoarthritis in the knees, ankles and feet.

██████████ – Rosa Choi, M.D. – Office Visit. The patient presents for first postoperative visit. Unfortunately left groin sentinel lymph node was positive for metastatic melanoma measuring 5 mm. Left flank wide excision healed well and nylons were removed. Left groin sentinel lymph node biopsy site yield well. Recommendation is left groin superficial lymphadenectomy with bacillus muscle flap to cover the femoral vessels. Impression: ████-year-old male with malignant melanoma stage III from left flank the left groin. He will need to see physical therapy in regards to getting fitted for Jobst garment of the left lower extremity lymphedema education. He will receive dose of 5000 units of heparin preoperatively.

██████████ – Mark Logan, M.D. – Progress Report. The patient's left back melanoma is healing well, SR/SS today. Left lateral abdomen melanoma with positive LN groin. He will be sent to UCLA for opinion. PET was negative.

██████████ – Bartosz Chmielowski, M.D. – Oncology Consultation. The patient has a history of multiple dysplastic nevi, which was initially diagnosed with melanoma probably in ██████████. He had one primary lesion over the right scapula. Recently, two other lesions were removed on ██████████. On ██████████ he underwent a wide excision and sentinel lymph node biopsy. Unfortunately, the pathology results are not available for the examiner. He states that his sentinel lymph nodes were positive for metastatic melanoma. The examiner does not know if it was a focal positivity or he had macroscopic disease. He is scheduled for effective lymph node dissection of the left groin on ██████████. The patient

## Noam Z. Drazin, MD

---

Board Certified, Internal Medicine

Board Certified, Medical Oncology

drinks alcohol occasionally. There is a family history of melanoma in his [REDACTED] and she survived it. His [REDACTED] has prostate cancer. Assessments: Melanoma is strongly dependent on sun exposure. He should avoid sun exposure. When he is outside, he should wear protective clothing and apply creams with SPF of at least 30. He must be under regular dermatologic surveillance at least every three months, and all suspicious lesions should be removed. He has about 45% risk of recurrence of the disease. It was explained that he should undergo elective lymph node dissection and microscopic analysis. It is recommended that he be treated with Intron A after surgery. Importance of vitamin D in patients with melanoma was talked about. He should be scanned with CT of the chest, abdomen and pelvis every six months.

[REDACTED] – [REDACTED] – Rosa Choi, M.D. – Operative Report. Procedure: Left groin superficial lymphadenectomy. Postoperative Diagnosis: Malignant melanoma.

[REDACTED] – [REDACTED] – Tony Pozzessere, M.D. – Discharge Summary. The patient tolerated the procedure well without complications. He received some heparin perioperatively. His pain was eventually controlled with p.o. medications and he received some teaching while an inpatient on how to

care for his J-P drain, which he was discharged with. He was told to use his compression stockings. Discharge Diagnosis: Malignant melanoma status post left groin superficial lymphadenectomy with Sartorius muscle flap. Discharge medications included Merco, aspirin, Flonase, and Zantac. Naproxen was discontinued.

[REDACTED] – [REDACTED] – Timothy Cloherty, M.D. – Pathology Report. Specimen: Left groin superficial lymphadenoma. Diagnosis: Six lymph nodes negative for metastatic melanoma.

[REDACTED] – Mukul Gupta, M.D. – Progress Report. The patient underwent a wide deep excision for malignant melanoma. However, after that he developed a necrotizing cholecystitis and chronic cholecystitis and had to undergo surgery on [REDACTED]. The pathology from the gallbladder shows acute necrotizing cholecystitis and chronic cholecystitis without malignancy. The patient is now recovering from gallbladder surgery. Interferon versus subcutaneous long-acting Interferon was discussed. Plan: Start Interferon.

[REDACTED] – Rosa Choi, M.D. – Progress Report. The surgical site in the left groin is healed well and patient continues to wear his Jobst stocking. The JP has high output close to 100 cc of serous fluid and cannot be removed. It was noted that the patient was walking too much. He will begin Interferon therapy however decision needs to be made regarding removal of the IVC filter and its stooping the Coumadin. He will return in two weeks to see if the drain can be removed. Assessment: Stage III malignant melanoma of the left flank.

[REDACTED] – Rosa Choi, M.D. – Progress Report. The patient's groin feels better and the erythema has resolved. He continues to wear his Jobst garment and minimize excessive walking.

## Noam Z. Drazin, MD

---

Board Certified, Internal Medicine

Board Certified, Medical Oncology

██████████ – Mukul Gupta, M.D. – Progress Report. The patient will start Sylatron therapy tomorrow. Module of metastatic melanoma measures 0.5 cm in greatest dimension. He is currently receiving Peginterferon treatment. Diagnosis: Malignant melanoma of groin. Plan: Lab studies. Adjuvant interferon.

██████████ – Rosa Choi, M.D. – Progress Report. The patient is status post IVC filter removal two weeks ago and on aspirin. He has stage III malignant melanoma from the left flank to the left groin status post wide excision of malignant melanoma and superficial lymphadenectomy which revealed no additional six lymph nodes positive for metastatic disease. Therefore, the patient had one sentinel lymph node positive for 5 mm foci of carcinoma and additional six lymph nodes negative for metastatic disease. He has recovered well from his melanoma surgery as well as the laparoscopic cystectomy for acute cholecystitis postoperatively. Incisions of all healed well. Plan: Begin interferon therapy.

██████████ – Mukul Gupta, M.D. – Progress Report. The patient is seen for follow-up of melanoma on adjuvant Sylatron chemotherapy. After interferon injections, the patient has two to three days of fatigue and joint pains. There are no new concerning melanoma spots. Diagnoses: Malignant melanoma of groin. Melanoma, left lateral torso, 1.4 mm depth, 2012. Plan: Week 3 of Sylatron. Order PET next visit.

██████████ – Rosa Choi, M.D. – Progress Report. The patient underwent ultrasound-guided aspiration of 10 cc of clear fluid for symptomatic relief of pressure in the left groin from the seroma.

██████████ – Rosa Choi, M.D. – Progress Report. The patient had mild break down of incision less than 1 cm at groin. Skin is red but not cellulitis. Plan: Triple antibiotic ointment and keep covered with gauze.

██████████ – Mark Logan, M.D. – Progress Report. The patient started interferon three weeks ago for melanoma. He presents for skin screening. Skin exam shows 1.5 cm light/dark brown irregular macule, left upper medial back, irregular nevus. Shave biopsy was performed.

██████████ – Western Dermatopathology – Hugh Byers, M.D. – Pathology Report. Specimen: Skin, left upper medial back, shave biopsy. Diagnoses: Malignant melanoma, superficial spreading type, invasive to Clark's level II with greatest measured thickness (Breslow) of 0.25 mm, present at peripheral biopsy margin. Arising in association with a compound dysplastic nevus.

██████████ – Mark Logan, M.D. – Progress Report. The patient complained of an itchy rash for two weeks. He started interferon six weeks ago for melanoma. Assessment: Rule out drug eruption. 2, 4 mm punch biopsies from left chest, shoulder.

██████████ – Kurt Lundquist, M.D. – Pathology Report. Specimen: Skin, left upper chest/shoulder punch biopsy. Diagnosis: Acantholytic dyskeratosis consistent with Grover's disease. Well-controlled pas stain negative for fungi.

## Noam Z. Drazin, MD

---

Board Certified, Internal Medicine

Board Certified, Medical Oncology

09/04/12 – Mukul Gupta, M.D. – Progress Report. The patient had a new biopsy left upper back two weeks ago which shows a new melanoma – WDE is pending. He is worried but stoic about the new biopsy. Plan: PET/CT skull to mid-thigh. Lab studies. Week 7 of Sylatron.

██████████ – Rosa Choi, M.D. – Progress Report. The patient presents with two biopsy proven malignant melanoma from the left upper medial back. Shave biopsy shows malignant melanoma superficial spreading type Clark level II with a measured thickness of Breslow as well as 0.25 mm. The examiner drew out a 1 cm radial margin around the shaved biopsy site and given its location recommendation is office wide excisional biopsy with 1 cm margin which patient is agreeable to.

██████████ – Mark Logan, M.D. – Progress Report. Pathology revealed acantholytic dyskeratosis. Clinically consistent with Grover's disease. Plan: Lidex cream bid.

██████████ – Rosa Choi, M.D. – Progress Report. The patient is with a thin melanoma 0.25 mm Breslow thickness Clark level II after shave biopsy of the pigmented lesion in the mid upper back nape of neck region. The patient underwent excision.

██████████ – David Martin-Reay, M.D. – Pathology Report. Specimen: Wide excision, melanoma, mid upper back. Diagnosis: Residual melanoma in-situ of a melanoma extending to a peripheral margin. Negative for invasive melanoma.

██████████ – Bernard Chow, M.D. – Tumor Imaging, PET/CT Whole Body. Impression: At least 3 foci of hypermetabolic activity within the liver without corresponding liver lesion identified on the nondiagnostic attenuation correction CT without contrast. Liver metastases are not excluded and recommend further evaluation with dedicated multiphase CT scan of the liver or MRI of the liver. Mild hypermetabolic activity likely corresponding to probable post-surgical changes in the left groin and left adductor musculature of in this patient with history of melanoma resection of the left groin. However, residual or recurrent neoplasm in this region is not excluded. Mild hypermetabolic activity in other areas of soft tissue uptake including the left anterior calf and soft tissues of the neck posteriorly may be related to postsurgical changes versus localize infectious or inflammatory process. Recommend direct visual inspection of these regions.

██████████ – Mukul Gupta, M.D. – Progress Report. The patient was seen for follow-up on adjuvant Sylatron chemotherapy prior to week 11. Diagnoses: Malignant melanoma of skin of trunk, except Ferritin scrotus. Melanoma of skin, site unspecified, Ferritin. Melanoma, left lateral torso, 1.4 mm in depth, ██████████ Malignant melanoma of groin. Melanoma, left upper medial back, 0.25 mm, 2012. Plan: CT of the chest, abdomen and pelvis. Lab studies. Proceed with week 11 of Sylatron.

██████████ – Bernard Chow, M.D. – CT of the Abdomen, Chest and Pelvis. Impression: Multiple mildly enlarged lymph nodes within the mediastinum of uncertain etiology and significance. The paraesophageal lymph node is seen adjacent to a thickened distal esophagus and may be due to esophagitis. Multiple small lymph nodes within the retroperitoneum and pelvis. No definite evidence for

## Noam Z. Drazin, MD

---

Board Certified, Internal Medicine

Board Certified, Medical Oncology

hepatic metastases. 2.6 cm skin and subcutaneous soft tissue lesion in the right posterior back superficial to the medial scapular border. 3.6 cm ovoid lesion in the left medial thigh may be due to postsurgical changes with evolving hematoma/seroma, however a necrotic lymph node is not excluded. Stable appearing soft tissue thickening in the left groin probably due to post surgical changes.

██████████ – John Yoon, M.D. – PET/CT Whole Body Scan with CT of the Chest, Abdomen and Pelvis. Impression: Focal area of FDG uptake in the lateral segment of left hepatic lobe is slightly more prominent but has no CT correlate and is favored to be artifactual. No new FDG avid lesion seen to suggest metastatic disease. Stable non-FDG avid small thoracic lymph nodes are likely reactive. Postoperative changes again noted in the left groin, with mild decrease in size of the non-FDG avid fluid collection in the medial left thigh which is compatible with a postoperative seroma. Left external iliac chain lymph node has decreased in size and is likely reactive.

██████████ – John Yoon, M.D. – MRI of the Brain. Impression: Minimal chronic small vessel ischemic disease without evidence for acute infarct or mass. No abnormal enhancement to suggest metastatic disease.

██████████ – ██████████ – Faith Ough, M.D. – Pathology Report. Specimen: Upper back skin, re-excision. Diagnosis: Skin showing scar and suture granuloma. No residual melanoma identified.

██████████ – ██████████ – Hugh Byers, M.D. – Pathology Report. Specimen: Skin, left upper

arm, shave biopsy. Diagnosis: Malignant melanoma in situ, superficial spreading type, likely narrowly excised. Arising in association with a compound dysplastic nevus, likely narrowly excised.

██████████ – Mukul Gupta, M.D. – Progress Report. The patient was seen for follow-up of melanoma on adjuvant Sylatron chemotherapy. Current therapy is Peg-Interferon, standard dose, long acting, once a week. He has recovered well from his melanoma surgery as well as the laparoscopic cystectomy for acute cholecystitis postoperatively. Incisions of all healed well and there is still a small seroma pocket at the most inferior aspect of his left inner thigh has been visualized with ultrasound and even seems to have gotten a little infected but it is currently doing better. He is worried but stoic about the new melanoma 0.25 mm Breslow thickness, Clark level II mid upper back, nape of neck region. Pathology showed residual melanoma in situ encroaching up to the margin and therefore he will need further wide deep excision. This has not been done as of yet. The patient experiences two to three days of fatigue and joint pains after the interferon injections. The patient is scheduled for another cyst removal by Dr. Choi.

██████████ – Mark Logan, M.D. – Progress Report. Left upper arm 6 mm proven melanoma in situ. The area was marked, cleansed, and lesion was excised in sterile fashion. The wound was closed and sutured.

## Noam Z. Drazin, MD

Board Certified, Internal Medicine

Board Certified, Medical Oncology

██████████ – Kenneth Daughters, M.D. – PET/CT Whole Body with CT of the Chest, Abdomen and Pelvis. Impression: Stable postoperative changes of the left groin and upper medial thigh with a 3 cm seroma or lymphocele and soft tissue thickening in the anterior left groin, unchanged, without significant hypermetabolic activity currently. Relatively stable mediastinal and retroperitoneal/pelvic lymph nodes without FDG uptake. No ascites or new focal liver lesion or pulmonary abnormality. Small focus of FDG uptake with maximum SUV of 5.04 in the region of the right lobe of the thyroid gland which may be associated with a nodule but no discrete lesion or mass is seen on the diagnostic CT.

██████████ – Julie Taguchi, M.D. – Progress Report. The patient was seen for follow-up of melanoma on adjuvant Sylatron chemotherapy. Current medications include aspirin, Plonase, Naprosyn, Zantac and Lidex cream. He received Peginterferon alfa-2b 315 mcg subcutaneously. The patient underwent a cyst removal from the right upper back and a melanoma removal from the left arm. Diagnoses: Screening. Enlarged thyroid. Malignant melanoma of groin. Melanoma, left lateral torso, 1.4 mm depth, ██████████ Melanoma, left upper medial back, 0.25 mm, ██████████ Melanoma in situ, right upper back, ██████████ Melanoma in situ, left lower back, ██████████ Melanoma in situ, left upper arm, ██████████ Maintenance antineoplastic Chemotherapy-Interferon. Nontoxic multinodular Goiter-Thyroid activity seen on PET scan. Plan: Lab studies. Sylatron weekly.

██████████ – Mark Wilson, M.D. – Office Visit. The patient reported poor sleep. He has muscle pain associated with his chemotherapy regimen. His memory is worse after he started chemotherapy. Assessment: Fatigue and low libido. Plan: Testosterone assessment. Consider replacement based on results.

██████████ – Mukul Gupta, M.D. – Progress Report. The patient is seen prior to next dose of Sylatron chemotherapy. He was treated with Peginterferon alfa Active and testosterone enanthate injection.

Diagnoses: Malignant melanoma of groin. Melanoma, left lateral torso, 1.4 mm depth, ██████████ Melanoma, left upper medial back, 0.25 mm, ██████████ Plan: PET/CT whole body.

██████████ – David Carlson, M.D. – PET/CT Whole Body Scan with CT of the Chest, Abdomen and Pelvis. Impression: No convincing evidence of hypermetabolic malignancy. Resolving postoperative changes in the left groin. This includes minimal FDG uptake in a left external iliac lymph node, which is more likely to be inflammatory than metastatic given its low level of FDG uptake, but should be followed. The 2.9 cm exophytic liver lesion arising from the caudate lobe shows no FDG uptake. While this suggests a benign lesion, the interval increase in size is somewhat concerning.

██████████ – Mukul Gupta, M.D. – Progress Report. The patient was seen for Sylatron chemotherapy. He is now in the second year of PEG interferon. Diagnoses: Maintenance antineoplastic chemotherapy – Interferon. Malignant melanoma of groin. Melanoma in situ, right upper back, ██████████ It was discussed with the patient that there is data to continue Interferon for up to five years, if tolerated.



## Noam Z. Drazin, MD

Board Certified, Internal Medicine

Board Certified, Medical Oncology

██████████ – Mukul Gupta, M.D. – Progress Report. The patient was seen for Sylatron chemotherapy. He complains of being tired and exhausted. Diagnoses: Melanoma in situ, right upper back, ██████████. Lymphedema of left leg. Maintenance antineoplastic Chemotherapy-Interferon. Plan: Lab studies.

██████████ – Mark Logan, M.D. – Progress Report. The patient was seen for skin screening. He has been on Interferon for ██████████ months. Skin exam of the trunk, extremities and head shows left antihelix scaly patch, actinic keratosis, LN2 and no cervical, axillary, inguinal adenopathy. The examiner sees no lesion suspicious of skin cancer or melanoma.

██████████ – Julie Taguchi, M.D. – Progress Report. The patient was seen for Sylatron chemotherapy. He has a diffuse rash which is supposedly from the Sylatron. He complains of fatigue. Diagnoses: Melanoma, left upper arm, left upper medial back, left lower back, left lateral torso, and right upper back. Malignant melanoma of groin. Maintenance antineoplastic chemotherapy – Interferon. Drug-induced leukopenia, stable. Drug-induced anemia, stable. Hypogonadism male. Right wrist pain. Plan: Lab studies.

██████████ – Mukul Gupta, M.D. – Progress Report. The patient was seen for evaluation prior to his next dose of weekly low dose peg-interferon. He still works for the County. He exercised for 45 minutes today. There is no evidence of disease. Plan: Restage with PET in March.

██████████ – Mukul Gupta, M.D. – Progress Report. The patient is currently off PEG Interferon. PET on ██████████ revealed no evidence of disease. Plan: PET in March.

██████████ – David Carlson, M.D. – PET/CT Scan. Impression: Continued interval enlargement of the mass that seems to be arising from the caudate lobe the liver, now with increased FDG uptake, suspicious for malignancy. No other suspicious FDG uptake.

██████████ – Hangama Abassi, M.P. – Progress Report. The patient was seen for evaluation prior to next dose of weekly low dose peg-interferon. He reports that after receiving iron infusion a few weeks ago he felt really good and had a boost in his energy. Patient was stable to receive treatment today. Lab indicate that he is still iron deficient and since he reported feeling much better after iron infusion, it was discussed and agreed that he would receive five more doses biweekly.

██████████ – Mark Logan, M.D. – Progress Report. The patient presented for skin screening. He finished ██████████ months of Interferon. Skin exam shows: Right superior helix 5 mm pink tender nodule, shave biopsy, C&D if possible; right temple 1 cm nodule, questionable cyst, excision time; and right superior shoulder 5 mm verruca, LN2.

██████████ – Hugh Byers, M.D. – Pathology Report. Specimen: Skin, right superior helix, shave biopsy. Diagnosis: Chondrodermatitis nodularis helicis.

## Noam Z. Drazin, MD

---

Board Certified, Internal Medicine

Board Certified, Medical Oncology

██████████ – Mukul Gupta, M.D. – Progress Report. The patient was seen for evaluation prior to next dose of weekly low dose peg-interferon. He was stable to receive treatment today. PET scan was negative for distant hypermetabolic disease but the examiner wants to get a 3-phase liver CT.

██████████ – Mark Logan, M.D. – Progress Report. Right temple 1 cm nodule was marked, cleansed and excised. Wound was closed with nylon sutures.

██ – Hugh Byers, M.D. – Pathology Report. Specimen: Skin, right temple, excision. Diagnosis: Epidermal inclusion cyst, represented margins are free of the lesion. Note: There is an intradermal squamous epithelial-lined cyst with a distinct granular cell layer and central abundant concentric keratinous debris.

██████████ – Mark Logan, M.D. – Progress Report. Pathology shows cyst. Right temple wound is healing nicely. There is no evidence of infection. Suture removal today.

██████████ – Monica Micon, M.D. – CT Abdomen Triple Phase. Impression: Compared to ██████████ There has been interval development of an approximately 9.3 cm in maximal diameter, ovoid, soft tissue mass in the periportal area of the liver suspicious for metastasis/adenopathy in this patient with known malignant melanoma. However, no other evidence for metastatic disease is identified within the visualized abdomen. Enlargement of benign appearing cyst left kidney.

██████████ – Mukul Gupta, M.D. – Progress Report. The patient is seen for evaluation prior to next dose of peg-interferon. He feels well and has no new side effects from the interferon. He was stable to receive treatment today. His performance status and his MCV have improved with iron injections. It was discussed with the patient that he has been on adjuvant interferon all this time for stage III melanoma, however he now has a lesion at the porta hepatis that is hypermetabolic on PET scan and gradually enlarging by CT scan. There is no other site of metastatic disease. Although it is rare, it is possible for this to be a melanoma involved lymph node, also possibility is another primary or even a nonmalignant process. He was referred to surgery for evaluation as to whether it can be removed.

██████████ – Mark Kovacs, M.D. – CT Guided Percutaneous Biopsy of the Abdomen. Impression: Successful CT-guided core needle biopsy of 4.7 cm mass in the porta hepatis.

██████████ – Lauren Jacobson, M.D. – Pathology Report. Specimen: Porta hepatis mass, needle core biopsy. Diagnosis: Metastatic melanoma. BRAF mutations were detected.

██████████ – Mukul Gupta, M.D. – Progress Report. The examiner called the patient to discuss the biopsy results which show that there is a metastatic deposit under the liver. This seems to be in portal lymph nodes, and the examiner has talked with Dr. Choi to see if it is possible to completely remove them as this is the only site of disease on the recent PET scan and has probably been present since the beginning as the patient had gallbladder surgery, right around the time of his melanoma surgery. Recommendations: Stop Interferon. Surgery. After surgery and healing, restaging with a PET scan is

## Noam Z. Drazin, MD

---

Board Certified, Internal Medicine

Board Certified, Medical Oncology

recommended followed by either resumption of Sylatron (less preferable) or proceeding with Ipilimumab and compassionate use anti-PDL 1 antibody.

██████████ – Rosa Choi, M.D. – Progress Report. The patient returns with metastatic melanoma to porta hepatis mass/node. Examiner discussed with patient and his wife the need to review the CT scan with regards to the lesion in the porta hepatis and whether this can be surgically excised from the adjacent structures such as inferior vena cava and portal vein and common bile duct.

██████████ Rosa Choi, M.D. – Medical Note. Discussed with Dr. Gupta importance of tumor debulking. CT scan reviewed with radiology. Mass is sitting at confluence of portal vein and splenic vein anterior to IVC.

██████████ – Monica Micon, M.D. – MRI of the Brain. Impression: Compared to ██████████, no significant interval change. Again seen are a few scattered foci of T2 prolongation within the deep white matter of the frontal lobes, likely representing sequelae of mild chronic microvascular ischemic disease, without evidence for acute infarct seen.

██████████ – Rosa Choi, M.D. - Operative Report. Procedure: Resection of intra-abdominal mass consistent with metastatic melanoma from the porta hepatis. Postoperative Diagnosis: Metastatic melanoma.

██████████ – Rosa Choi, M.D. – Progress Report. Hospital Day #1, patient doing well and pain is controlled. Assessment: Status post open porta hepatis exploration with excision of metastatic melanoma. Plan: Start sips, advance tomorrow. Pain control opn. Monitor UOP with Foley overnight. Encourage ambulation, IS, SCDs.

██████████ ██████████ – Lauren Jacobson, M.D. – Pathology Report. Specimen: Designated "intra-abdominal portal mass," excision. Diagnosis: Metastatic melanoma involving matted lymph nodes.

██████████ – Rosa Choi, M.D. – Progress Report. The patient feels great this morning. He took p.o. pain medications a couple times. He is doing well postoperatively. Plan: Advance diet, pain control and ambulation.

██████████ – Rosa Choi, M.D. – Discharge Summary. The patient was scheduled for an elective resection of isolated metastasis. He underwent surgery and an isolated metastasis was located within the porta hepatis located medially to the common hepatic artery. Metastasis was cored out without complication. There was minimal blood loss during the case. Discharge Diagnosis: Metastatic melanoma status post resection of isolated metastasis.

██████████ – Rosa Choi, M.D. – Progress Report. The patient's first amylase was 200 prior to discharge and repeat amylase today is 71 from JP fluid. The JP was removed without difficulty. Surgical site is healed well and the patient is recovered. He is placed on disability for four weeks.

## Noam Z. Drazin, MD

---

Board Certified, Internal Medicine

Board Certified, Medical Oncology

██████████ – Mukul Gupta, M.D. – Progress Report. The patient is seen for follow up of pathology proven metastatic melanoma cancer. Patient underwent surgery to remove a porta hepatis matted lymph node mass, which was a 5 cm metastatic melanoma deposits. This was tested for BRAF mutation and has come back BRAF mutated. He is not currently receiving any therapy. The patient cannot go back to work because of anxiety, fatigue and abdominal pain after surgical resection. It was discussed that the patient should be referred for evaluation for potential clinical trials. Diagnosis: Metastatic melanoma to liver. Plan: Lab studies. External referral to Non-Sansum Department. PET and CT.

██████████ – Omid Hamid, M.D. – Consultation. The patient was seen for B-RAF mutated metastatic melanoma of the liver tissue. There is a family history of prostate cancer and melanoma. Assessment: The patient has not been rescanned since his full body PET scan in March, and at that time, he had no other evidence of disease. At today's clinic visit, the examiner and patient discussed the possibility of participation in a clinical trial investigating an anti-PD-1 antibody in combination with a MEK inhibitor, as well as B-RAF inhibitor for patients who are B-RAF mutated; however, the patient would need to have measurable disease in order to participate in this clinical trial. He noted that he is scheduled to have scans with his outside oncologist on ██████████ therefore, the plan will be to bring him back to the clinic after that scan to review the scans, and if there is evidence of measurable disease, he will possibly go forward with the clinical trial.

██████████ – David Carlson, M.D. – PET/CT Whole Body Scan with CT of the Chest, Abdomen and Pelvis. Impression: Interval resection of the periportal nodal metastasis. Again seen is mild FDG uptake in the left inguinal portion of the abdominal wall. Early recurrence cannot be excluded. Recommend continued attention on follow-up to the nonspecific 1 cm left external iliac lymph node. Focal intense FDG uptake in the right 1<sup>st</sup> and 2<sup>nd</sup> toes. While this FDG uptake is likely inflammatory, recommend visual inspection to exclude any skin lesions on these toes. Nonspecific low attenuating splenic lesion, which can be followed.

██████████ – Mukul Gupta, M.D. – Progress Report. The patient was seen for follow-up of surgically resected BRAF mutated metastatic melanoma. He has discussed participating in clinical trials. However, he has no measurable disease. It was discussed that the reasonable option would be to attempt Zelboraf, or Ipilimumab systemic therapy. Diagnoses: Metastatic melanoma to liver. Melanoma of skin, site unspecified. Plan: Lab studies. Ativan, Zofran and Imodium. Oncology medical authorization.

██████████ – Mark Logan, M.D. – Progress Report. Interferon was discontinued due to MET near liver. He is now on chemo and presents for skin screening. Skin exam showed scattered SK's. The examiner saw no lesion suspicious of skin cancer or melanoma.

██████████ – Mukul Gupta, M.D. – Progress Report. The patient is seen for cycle two of chemotherapy. He had a headache after the first cycle. There are no focal danger signs or other signs. Diagnosis: Metastatic melanoma to liver. Plan: Cortisol AM and ACTH.

## Noam Z. Drazin, MD

---

Board Certified, Internal Medicine

Board Certified, Medical Oncology

██████████ – Xxx Trambert, M.D. – MRI of the Brain. Impression: Stable age compatible changes reidentified. No evidence of metastatic disease identified throughout.

██████████ – Mukul Gupta, M.D. – Progress Report. The patient has had fatigue and aches and pains from being on Yervoy but no lab abnormal values or immune breakthrough events. He is on disability due to metastatic melanoma and treatment. The fourth and final cycle of Yervoy was completed. The examiner discussed with the patient that there is preliminary data from ASCO presentation of ECOG trial showing OS benefit of adding Leukine to/after Yervoy. Patient was on Sylatron and therefore the examiner thinks he would tolerate the Leukine. The patient is motivated to do so. Diagnosis: Metastatic melanoma to liver. Plan: Leukine, PET scan in mid-November.

██████████ – Mukul Gupta, M.D. – Progress Report. The patient has completed four cycles of Yervoy. He has gradually recovered from the side effects related to Yervoy such as muscle aches and pains, bone pains and fatigue. The patient wishes to start Leukine now. It was discussed that if his PET scan shows worsening disease rather than Leukine, they will proceed with Keytruda. Diagnoses: Malignant melanoma of groin. Metastatic melanoma to liver. Plan: PET Scan and lab studies.

██████████ – Kenneth Daughters, M.D. – Tumor Imaging, PET Whole Body. Impression: Increased focal FDG uptake in the right neck, posterior to the cricoid cartilage, but not within the spine itself, is suspicious for a metastatic lesion. A discrete measurable mass is not apparent on the limited attenuation correction CT for this exam. New FDG activity in the medial aspect of the spleen likely associated with the hypoattenuating lesion seen on the most recent study from August and suspicious for a metastatic focus. The lesion itself again is not well evaluated on this limited noncontrast attenuation correction CT. Persistent/relatively stable low-level FDG uptake with SUV max=3.0 in the superficial soft tissues of the left inguinal canal. No new discrete measurable mass in this region, although active disease at this location is still considered. Stable left paratracheal superior mediastinal lymph node with low level FDG uptake warrants continued surveillance. Stable FDG uptake in the feet. New right knee joint effusion with low level FDG activity likely reactive. Slight interval decrease in size of a small subcutaneous fluid collection in the left medial thigh.

██████████ – Mukul Gupta, M.D. – Progress Report. The patient is starting Leukine today, 14 on and 14 off. The examiner discussed the situation with the patient – the PET scan shows some lesions that are not clearly metastatic disease – one lesion is in the neck another lesion is in the spring, patient has no symptoms in both areas. Diagnosis: Metastatic melanoma to liver. Plan: Leukine injections.

██████████ – Rosa Choi, M.D. – Progress Report. The patient is currently on Leukine 570 mg SC per Dr. Gupta. Impression: Stage IV malignant melanoma to a half years from initial diagnosis and treatment. Plan: Follow-up in six months. Repeat PET scan and continuation of Leukine treatment.

██████████ – Mukul Gupta, M.D. – Progress Report. The patient presents for cycle two of Leukine and states that he felt fatigue after cycle one but no other serious side effects. He is able to walk three and a half miles per day but he does get tired at the end of the cycle. Diagnosis: Malignant melanoma of groin.

## Noam Z. Drazin, MD

---

Board Certified, Internal Medicine

Board Certified, Medical Oncology

Plan: Cycle two of Leukine. Patient has BRAF mutation therefore eligible for dual inhibition of that pathway as well as any clinical trials.

██████████ – Mark Logan, M.D. – Progress Report. Skin exam of the trunk, extremities and head shows: Left forearm 7 mm pink keratotic nodule SCC, shave biopsy, C&D'd x 3 and two scaly patches of forearm, left shoulder, actinic keratoses, LN2.

██████████ – Kurt Lundquist, M.D. – Pathology Report. Specimen: Skin, left forearm, shave biopsy and electrodesiccation and curettage. Diagnosis: Invasive well-differentiated squamous cell carcinoma, 1.1 mm thick. Visualized margins free of malignancy.

██████████ – Christopher Kuzminski, M.D. – CT of the Neck, Chest, Abdomen and Pelvis. Impression: Two enlarging lesions within the spleen are concerning for metastatic disease. Previous PET exam noted a region of metabolic activity posterior to the right cricoid cartilage. No discrete lesion is identified in this region. However, evaluation is limited, and the possibility of a small underlying lesion cannot be entirely excluded. A 4 mm pulmonary nodule medial right lower lobe is stable compared to recent examinations but new compared to earlier prior studies. In this setting, the finding is concerning for metastasis. Stable nonspecific paratracheal lymph node at the thoracic inlet.

██████████ – Mukul Gupta, M.D. – Progress Report. The patient presented for evaluation after cycle 2 of Leukine and restaging CT. Restaging shows enlarging splenic tumors so the examiner will refer for radiation to the tumors and then start Keytruda. If worsening then switch to pembrolizumab. He is eligible for dual inhibition of the pathway. Diagnoses: Metastatic melanoma to liver. Melanoma of skin, site unspecified. Plan: Lab studies. Referral to Radiation Oncology. Ativan, Zofran and Imodium. Oncology medical authorization.

██████████ – George Cheng, M.D. – Radiation Oncology Consultation. The patient was seen to discuss the role of radiation therapy. He currently denies left flank or abdominal pain. Energy level is good. He is switching to Keytruda, starting ██████████. Indications of radiation therapy were discussed. The spleen is a relatively radiosensitive structure which can be treated at low doses for splenomegaly, due to hematopoietic malignancies. Melanoma tends to be less radiosensitive than other malignancies and requires larger fraction doses. Unfortunately, the dose required for controlling this burden of melanoma in the spleen would be prohibitive. In the literature there has been a role for laparoscopic splenectomy for oligo metastatic melanoma to the spleen. This might be an appropriate approach if systemic control elsewhere appears to be a reasonably achievable goal.

██████████ – Mukul Gupta, M.D. – Progress Report. The patient is starting Keytruda today. It was discussed that he has metastatic melanoma and is likely to need treatment and/or palliative care for the rest of his life. Therefore, the examiner would suggest long-term disability. Patient agrees and paperwork was filled out. Radiation oncology feels that a laparoscopic splenectomy would be more useful. Diagnoses: Malignant melanoma of groin. Malignant neoplasm of spleen, not elsewhere

## Noam Z. Drazin, MD

---

Board Certified, Internal Medicine

Board Certified, Medical Oncology

classified. Metastatic melanoma to liver. Plan: Obtain consultation with Dr. Choi. Start Keytruda. Lab studies.

██████████ – James Dunn, M.D. – History and Physical. The patient presented to discuss laparoscopic splenectomy. Impression: Metastatic melanoma with isolated lesions within the spleen only by PET scanning. Discuss laparoscopic splenectomy. Possible open procedure. Immunizations will be ordered preoperatively. Plan: Laparoscopic splenectomy.

██████████ – James Dunn, M.D. – Operative Report. Procedure: Laparoscopic splenectomy. Postoperative Diagnosis: Metastatic melanoma to spleen.

██████████ – Lauren Jacobson, M.D. – Pathology Report. Specimen: Spleen, splenectomy. Diagnosis: Metastatic melanoma. Background spleen unremarkable.

██████████ – James Dunn, M.D. – Progress Report. The patient was seen for a postoperative check with no major events. Pain controlled. Plan: Prn pain control. Await bowel function. Mobilize. Pulmonary hygiene.

██████████ – James Dunn, M.D. – Progress Report. The patient's pain was controlled and he had no complaints. Assessment: Status post splenectomy for metastatic melanoma POD1. Plan: Discontinue Foley. Start diet. Pain control. Discharge home later today.

██████████ – ██████████ Discharge Summary. Discharge Diagnosis: Metastatic melanoma. Plan: Regular diet. Activity as tolerated. No lifting greater than 20 pounds for two weeks. Pain medications as needed. Bowel regimen medication.

██████████ – Hangama Abassi, N.P. – Progress Report. The patient was seen prior to Keytruda #2. He tolerated cycle one well. He reports that he tolerated the splenectomy two weeks ago well. The situation is complicated as the patient had a subhepatic lymph node metastasis that has been resected and proven to be BRAF wild type metastatic melanoma. The patient has undergone four cycles of Yervoy. Assessments: Malignant melanoma of groin. Metastatic melanoma to liver. Melanoma of skin, site unspecified. Melanoma, left lateral torso, 1.4 mm depth, ██████████ Melanoma, left upper medial back, 0.25 mm, ██████████ Plan: Lab studies. Indocin 50 mg. Cycle 2 of Keytruda.

██████████ – James Dunn, M.D. – Progress Report. The patient has minimal complaints following surgery. Excision site is healing well.

██████████ – Mukul Gupta, M.D. – Progress Report. The patient presented for cycle #3 of Keytruda. Current medications included Flonase, Indocin, aspirin, Imodium, Ativan, Zofran and Leukine 570 mcg

subcutaneously daily for 14 days every 28 days. Diagnoses: Malignant neoplasm of spleen, not elsewhere classified. Metastatic melanoma to liver. Malignant melanoma of groin.

## Noam Z. Drazin, MD

---

Board Certified, Internal Medicine  
Board Certified, Medical Oncology

██████████ – Hangama Abassi, N.P. – Progress Report. The patient presented for cycle #4 of Keytruda. The examiner discussed with patient his lab results with Dr. Gupta and noted the trending down of thyroid function which is a side effect of Keytruda. Plan: Levothyroxine 25 mcg. Melatonin 5 mg. Lab studies. Oncology P&P implemented. Patient tolerated procedure with no adverse reactions noted or reported by patient.

██████████ – Mukul Gupta, M.D. – Progress Report. The patient was seen for cycle #5 of Keytruda. The patient is currently tolerating the treatment but is having mildly increased fatigue, which might be due to hormone deficiency. Diagnosis: Metastatic melanoma to liver. Plan: ACH and Cortisol AM. Consider starting supplementation with oral hydrocortisone soon. Restaging PET after six cycles. The patient underwent a total dose of 200 mg Keytruda due to weight gain and drug availability.

██████████ – Mark Logan, M.D. – Progress Report. The patient is on new chemo and had spleen removed. Skin exam revealed two pink scaly patches of left arm, actinic keratoses and scattered SKs. The examiner saw no lesion suspicious of skin cancer or melanoma.

██████████ – Mukul Gupta, M.D. – Progress Report. The patient presented for cycle #6 of Keytruda. He is currently tolerating the treatment but is having mildly increased fatigue. Plan: Check and monitor hormone levels.

██████████ – Christopher Kuzminski, M.D. – PET/CT Whole Body with CT of the Chest, Abdomen and Pelvis. Impression: No new hypermetabolic lesions are identified. Previously noted activity posterior to the right cricoid cartilage is much less prominent with only minimal asymmetric activity at this location currently. Stable appearance of low level activity in a left paratracheal lymph node at the thoracic inlet. Status post splenectomy. Nodules in this region are likely small splenules. Stable postsurgical changes in the left inguinal region. Low level activity in this region is favored to be postsurgical but should be followed on subsequent exams. Questionable slight increase in size of a 5 mm pulmonary nodule in the medial right lower lobe. Decreased size of fluid in the medial left thigh. There is questionable increasing nodularity just superior to this fluid collection without significant hypermetabolic activity.

██████████ – Hangama Abassi, N.P. – Progress Report. The patient was seen for cycle #7 of Keytruda. He reports that he has good energy and is exercising daily. The only side effect that he is having currently is hot flashes. Diagnoses: Malignant melanoma of groin. Metastatic melanoma to liver. Hot flashes.

██████████ – Deposition of 20x Xxxxx, Volume I, 70 pages. He states that he is currently on Keytruda, a chemotherapy, prescribed by Dr. Gupta. Dr. Gupta is located at ██████████ and he is an oncologist. He is also taking a medication for gout as needed. He was asked if any of the medications would affect his ability to think and answer questions today to the best of his ability and replied, "chemotherapy plays with the brain, yes." He states that he has not taken chemotherapy today so he is

able to think clearly today. He is not currently working. The last place he worked was for ██████████. Prior to working for the ██████████ he worked at ██████████, starting in ██████████. He agrees that the work he did was all outside and he was a full-time employee. He does not



## Noam Z. Drazin, MD

Board Certified, Internal Medicine

Board Certified, Medical Oncology

remember if he suffered any severe sunburns while working at [REDACTED]. [REDACTED] did not provide a uniform but he states that he would wear boots, blue jeans, T-shirt and a hard hat. He did not suffer any work injuries at [REDACTED]. He worked there from [REDACTED] to [REDACTED]. Before [REDACTED] he worked for [REDACTED] as a laborer. He worked on roads all outside. He states that he would wear shorts, T-shirt and a hat. He was a full-time employee at [REDACTED] and was hired in about [REDACTED] and last worked for them in [REDACTED]. He did not suffer any work injuries while working for them. His last day working for the [REDACTED] was on [REDACTED]. [REDACTED] He stopped working due to surgery. He doesn't know what his current employment status is with the County. He states that his status is disability right now. He states that Dr. Gupta wrote him a note to take him off work and has not released him back to work. His initial title when he was hired by the [REDACTED] was [REDACTED]. He had that position for maybe three months and the type of duties he had were [REDACTED] including plumbing, electrical, carpentry and irrigation. He worked 50/50 inside and outside for those three months. He states that he would wear blue jeans, T-shirt and a hat. He states that he was then promoted to [REDACTED] and he worked in that position until [REDACTED]. He states that his job duties were the same as [REDACTED]. Additional duties included air-conditioning and HVAC. He states that 75 percent of the time he was at [REDACTED] and of that time, he would be 50/50 inside and outside on a normal day. He continued to wear blue jeans, T-shirt and hat. The other 25 percent of his time was spent at the [REDACTED]. He states that the air conditioned units he would work on were on the roof and there was not any shade. He states that he never wore sunscreen to work until [REDACTED]. After [REDACTED] he was promoted to a [REDACTED], which is the position he is still in today. The duties included making work orders, running a crew of six, estimating jobs and keeping everything functioning. He states that he had an office at the courthouse. He states that he spent 50% of the time in his office doing administrative work and the other 50% was out in the field. Of the 50% out in the field, he would be outside four hours a day. He states that he is alleging stage four melanoma for the current [REDACTED]. He was diagnosed with stage four melanoma in [REDACTED]. It was discovered at the dermatologist's office; "they found a mark on my left flank". He states that he had surgery to remove it, performed by Dr. Choi. He states that the dermatologist that he saw was Dr. Logan. After he had surgery to remove it, it had metastasized and got into the left groin, which was discovered by doing a biopsy. He then had to have surgery to remove the lymph nodes in the left groin. He then healed and saw Dr. Gupta. He went back to work and started getting chemotherapy shots for a year and a half weekly. He agrees that he was preventatively doing the chemo shots. He states that the first surgery to remove it on the left flank was in [REDACTED]. He states that the groin surgery could have been in [REDACTED] of [REDACTED]. He states that it was then discovered that it had metastasized to the liver in [REDACTED]. He had to have surgery to remove the tumor around the liver. He was asked if that surgery was successful and he replied, "they, supposedly, got it all, yes." He then took more chemo called interferon and in [REDACTED] of [REDACTED] it had spread to his spleen. He had to have his spleen removed in [REDACTED]. He states that he has recovered from the surgery to his spleen and is not "just getting the

chemotherapy". No other tumors have been discovered at the moment. He has not been declared in remission. He was asked if the doctors have seen any other spots that they're concerned about and he

## Noam Z. Drazin, MD

---

Board Certified, Internal Medicine

Board Certified, Medical Oncology

replied, "possibly, on the lung. It's too early to tell." He agrees that right now he is just in the maintenance. He states that he receives the chemo through an IV once every three weeks; it's called Keytruda. He is experiencing side effects which include hot flashes, muscle aches and memory. Dr. Gupta has not explained the next steps for future treatment with him. He states that he saw a doctor at the Cancer Center in [REDACTED] for possible radiation. He states that it was Dr. Gupta's thinking they could shrink the tumor on the spleen. He states that he never had radiation. He states that he has been to UCLA for second opinions twice. He agrees that he has had cancer before, probably 10 other times. It was melanoma ten other times. He agrees that when he is saying melanoma, that was the spots that the dermatologist had found. He underwent in-office removal for all 10. He states that Dr. Logan found the 10 other melanomas. His first melanoma was discovered prior to working for the [REDACTED]. It was first discovered when he was working at [REDACTED]. He was asked if all 10 spots were removed before his employment with [REDACTED] and he replied, "no". He states that possibly three spots were removed prior to his employment with [REDACTED]. He was asked to state where the 10 spots were on his body and he responded, one on the nose and then the rest would be back, shoulders, arm and forearm. He also reported that there were three spots prior to his work with the county which were on the nose, and the other two he doesn't remember. He has had one spot removed from his upper arm bicep. He was asked if he had any spots where it would be exposed with wearing a T-shirt and he replied, "small one on my arm right here (left upper forearm)". He was asked if any doctor indicated that they think the melanoma is related to his employment with the [REDACTED] and he replied, "no". He was asked what makes him think this is related to his employment with the county and he replied, "being in the sun for 30 years with [REDACTED]". He states that of those ten spots, Dr. Logan has removed about seven of them. He states that the major hobbies that he has since the [REDACTED] are horseshoes, softball and fishing. He states that he still goes fishing and he owns a boat. He has primarily gone fishing in Cachuma Lake and the Sierras in the last 30 years. When he is fishing, he goes out fishing about three times per month. He states that he would normally wear shorts and T-shirt, but now that he has been diagnosed, he wears long-sleeved T-shirts. He also wears a hat that covers the ears and face ever since his diagnosis. Before the diagnosis he was just wearing a baseball cap and it didn't cover the ears. He agrees that when he is fishing he spends half a day outside. He was asked approximately how much time he spends outside when he was not at work and he replied, "six hours a day." After work, he would maybe be outside for an hour after work. He would be outside five to seven hours on the weekend. He does have a family history of cancer. His dad has prostate cancer, his grandparents on his mom's side had stomach cancer, and he believes there is also stomach cancer on his dad's side. He states that his mom had melanoma, but no surgeries, just office. He agrees that his other would continually have spots removed for melanoma but hers never metastasized. He agrees that the spot of melanoma that metastasized has caused his subsequent surgeries on the left side. He was asked if that area was ever exposed to the sun at work and he answered, "yes", when he first started with the county, he would work overtime on the weekends and they would have their shirts off and working in parking lots, roofs, air-conditioning. He agrees that he was allowed to work with his shirt off. He would work quite a bit during those times without his shirt on. He worked a lot of overtime on the weekends. He states that he would only not wear his short on weekends. He worked about four to eight

## Noam Z. Drazin, MD

Board Certified, Internal Medicine

Board Certified, Medical Oncology

hours on the weekends, just Saturday. He states that he started working weekends soon after he was hired. The last time he worked a weekend was probably two weeks before he went off on the surgery. The last time he worked without his shirt on was maybe [REDACTED]. He agrees that he would go the beach at times living in [REDACTED] and would not wear a shirt. He fished at times without his shirt on. He worked weekends maybe twice a month from [REDACTED] to [REDACTED]. He was asked if anyone authorized him to take his shirt off while working and he replied, "no rules". There was no supervisor present. He states that he would not work without a shirt every weekend, rather, it would be in the summer months. He agrees that he noticed being sunburned at work while working for [REDACTED]. He states that he worked without a shirt at [REDACTED] maybe once a week. He agrees that he has worn a shirt at work since [REDACTED]. He reported the melanoma to [REDACTED] County when he was diagnosed with the surgery. He agrees that he told them at that point that he thought it was work-related. He first reported it in May of [REDACTED]. He reported that he was diagnosed with melanoma. He agrees that the spot on his left side that metastasized was the first time he had skin cancer in that area. He agrees that most of his other sports were either on his arms or upper back. He states that Dr. Gupta has him permanently off work. He was asked if he would want to go back to work if the chemo were to end with a good prognosis and he replied, "no". He wants to be retired. He is trying to retire with [REDACTED]. He states that he filed for medical retirement [REDACTED]. He states that he goes to the dermatologist every six months. End of Deposition.

[REDACTED] – Hangama Abassi, N.P. – Progress Report. The patient was seen for cycle #8 of Keytruda. He started to get body aches after the last dose. He states that he was not active as usual due to the aches and pains. He still has hot flashes occasionally. Assessment: Status post splenectomy. BRAF mutated metastatic melanoma. Plan: Lab studies, Urinalysis.

[REDACTED] – Mukul Gupta, M.D. – Progress Report. The patient was seen for cycle #9 of Keytruda. He receives Kytril injections 1 mg IV prn. He is likely to need treatment and/or palliative care for the rest of his life. He is applying for benefits. Plan: Proceed with Keytruda.

[REDACTED] – Hangama Abassi, N.P. – Progress Report. The patient was seen for cycle #10 of Keytruda. He complained of body aches after the last dose. Review of systems was positive for fatigue, sleep disturbance and weight gain. Diagnoses: Malignant melanoma of groin. Metastatic melanoma to liver. Plan: Proceed with Keytruda.

[REDACTED] – Mukul Gupta, M.D. – Progress Report. The patient is currently being treated with Keytruda. Patient has no symptoms. Diagnosis: Malignant melanoma of groin. Plan: Cortisol AM and Keytruda.

### Past medical History:

Skin cancers – melanoma, basal cell, squamous

Gout

Allergic rhinitis

## Noam Z. Drazin, MD

---

Board Certified, Internal Medicine  
Board Certified, Medical Oncology

History of DVT [REDACTED]

### Past surgical History

Splenectomy (staging)

Skin cancer surgeries (multiple)

### Family History:

[REDACTED] – melanoma (superficial), died of heart attack

[REDACTED] – prostate cancer (alive)

### Social History

Married, no children, no smoking

### Medications:

Melatonin, naproxyn, indomethacin (prn), fentanyl, aspirin

Keytruda (infusion every 3 weeks)

### Current complaints:

Dry mouth, muscle aches, fatigue, hot flashes, insomnia, confusion, difficulty with attention (chemo brain), dental decay accelerated, finger nail destruction, inability to lift >20 pounds.

### Physical Examination:

The patient is a [REDACTED]-year-old, alert, cooperative and oriented English speaking male, in no acute distress. The following vital signs and measurements are taken today on examination: Weight: [REDACTED] pounds. Height: [REDACTED] m. Blood Pressure: [REDACTED] Heart Rate: [REDACTED]

### Skin:

Vitiligo (absence of pigment) noted on arms, and chest

### Head:

The patient's head is normocephalic and atraumatic. The patient's facial muscles show good contour and symmetry. There is no scleral icterus and no tenderness of the skull noted on examination.

### EENT:

Pupils are equally reactive to light and accommodation. Extraocular movements are intact. The throat

## Noam Z. Drazin, MD

---

Board Certified, Internal Medicine  
Board Certified, Medical Oncology

is clear. Hearing appears to be uninvolved. The patient's neck is overall supple with no evidence of lymphadenopathy, thyromegaly or bruits. Dentition is very poor, with obvious dental carries and missing teeth

### Thorax:

The patient exhibits good bilateral rib excursion during respiration. Lungs are clear during percussion and auscultation. The heart reveals a regular rate and rhythm and no murmurs are noted.

### Abdomen:

The abdomen is normal, non-tender without organomegaly. Normoactive bowel sounds are present.

### Genitalia and Rectal:

Examination is deferred.

### Musculoskeletal Examination:

There is no tenderness or myospasm of the cervical, thoracic or lumbar sections of the spine.

### Upper Extremities:

There is no asymmetry, deformity, or tenderness. Range of motion, consisting of flexion, abduction, external rotation, and internal rotation, is within normal limits.

### Lower Extremities:

The patient's lower extremities appear to be normal and the dermatomes were apparently uninvolved. The reflexes are a normal +2.

### Neurological Examination:

Cranial nerves 2-12 are intact. Deep tendon reflexes are 2+ bilaterally. Superficial reflexes are found to be within normal limits. There are no abnormal reflexes detected and there is no abnormality of sensation or coordination.

### Impression:

The applicant (Mr. Xxxx) has developed metastatic melanoma after originally been diagnosed with lymph node positive (stage III) disease back in [REDACTED]. He currently has stage IV disease which is terminal and is currently receiving anti-cancer therapy with keytruda which is currently stabilizing his disease which is limited to lymph nodes in the chest and abdomen as well as pulmonary (lung) nodules. His symptoms described and corroborated in my evaluation and history are due to the required continued treatment of his underlying cancer condition. Due to those symptoms and complaints, Mr. Xxxx is in

## Noam Z. Drazin, MD

Board Certified, Internal Medicine  
Board Certified, Medical Oncology

my opinion permanently incapacitated and unable to perform his current job duties as described or unfortunately any and all accommodations and alternative job assignments. He is limited physically by severe fatigue but also equally limited by confusion and memory disturbances attributed to his prior and current anti-cancer therapy.

This cancer diagnosis is directly attributable to his sun exposures over the last 30 years while employed by the [REDACTED]. In my opinion his employment has contributed substantially to his permanent incapacity as described above.

### Medical-Legal Questions:

1. Is there any objective evidence of cancer? If so, please state:
  - a. What tests and measurements were performed, with what results
  - b. Whether any test or measurement that produced an abnormal result is subject to the volition of the applicant and, if so, whether you feel the applicant fairly performed the test, and
  - c. Whether the presence, absence, or degree of any objective finding is remarkable in light of the subjective complaints or the given history

Mr. Xxxx's most recent PET/CT imaging performed in [REDACTED] shows evidence of residual/recurrent cancer (melanoma) in multiple areas. Specifically, there is enlarged lymphadenopathy in the chest and abdomen/pelvis with additional pulmonary (lung) nodules. All these abnormalities suggest the presence of active disease which defines his need for continued anti-cancer therapy.

2. Does the member have any subjective complaints attributable to the cancer disorder that are claimed to be incapacitating? If so, please state:
  - a. The frequency, intensity, and duration of those complaints, both claimed by the member and as evaluated by you;
  - b. Any factors that precipitate or ameliorate the complaints; and
  - c. Whether the presence, absence, degree, or other aspect of any subjective complaint is remarkable in light of the findings of the given history.

As mentioned in the report above, Mr. Xxxx's reported complaints are mostly related to adverse reactions due to his current ongoing therapy for metastatic melanoma. His complaints of dry mouth, muscle aching, severe fatigue, hot flashes, poor dentition, and confusion are all secondary to active and ongoing treatment. My history and physical examination confirm and support his stated complaints. The objective imaging findings of lymphadenopathy and the lung nodule themselves do not contribute to any specific symptoms.

## Noam Z. Drazin, MD

---

Board Certified, Internal Medicine  
Board Certified, Medical Oncology

The confusion or "chemo brain" component of his complaints are likely to be exacerbated by stress (home or work).

3. Is the cancer condition claimed to be incapacitating:
  - a. Worsening;
  - b. Improving; or
  - c. Remaining the same? (if remaining the same, how long has it been so?)

The complaints and limitations secondary to treatment of this recurrent cancer have remained the same for the past 6-8 months. He remains on the same medication (Keytruda) for over 12 months. The disease itself has remained somewhat stable with the findings mentioned in a previous answer.

4. Is there presently, or is there likely to be in the future, the need for further diagnostic procedures, evaluation or treatment with respect to the condition in question? If so, please describe the nature and extent of the same

I don't have any records to use to determine the next time that Mr. Xxxx will be restaged with a PET/CT. It would be consistent with the national standard of care to obtain radiologic imaging every 6 months during the course of the treatment.

5. According to the criteria set forth above and your review of the attached Job Factors Form, does the member's cancer condition presently "incapacitate" the member from any activity, or other function described in the enclosed Job Factors Form? Please take into account any reasonable accommodations that may be possible as described in the Job Factors Form. If so, for each function please state:
  - a. The precise nature of the function in question
  - b. Whether or not it is impossible for the member to perform that function;
  - c. If it is possible for the member to perform that function, is it probably that performance of that function will cause further significant cancer injury?

Upon review of the Job Factors form, it is clear to me that Mr. Xxxx is currently incapacitated from performing the usual tasks that are relegated to his job description. The ability to supervise staff, maintain work schedules, maintain records, and help coordinate repairs would be impossible with his current treatment and cancer related symptoms. Specifically, the confusion and memory disturbances related to therapy would have a direct impact on his ability to perform these specific tasks. Additionally, the applicant receives infusional therapy every 3 weeks as an outpatient and requires frequent MD visits in between these therapies which would impact his ability to maintain his work hours.

## Noam Z. Drazin, MD

---

Board Certified, Internal Medicine  
Board Certified, Medical Oncology

Unfortunately, the alternative assignments and accommodations listed on the Job Factors Form do not allow Mr. Xxxx any opportunities to continue working in any capacity. The same limitations will affect even with any listed accommodation.

6. If you find that the member is presently incapacitated by a cancer condition from performance of any job junction, is such current incapacity:
- Permanent; or
  - Likely to materially improve with additional treatment, or passage of time to the point where the member can return to his usual duties with or without reasonable accommodation; or
  - Not presently ascertainable as either temporary or permanent

Mr. Xxxx's cancer condition is terminal. Thankfully his current treatment course has maintained stability of his disease course over the past 12 months. However, there is no indication that this disease is curable. As such, the treatment and further additional therapies that will be necessary will be continued until a time when treatment is no longer working. His incapacities as listed and described now will only likely worsen over time during the course of his current and projected treatment.

7. IF you conclude that applicant's present incapacity is likely to materially improve with additional treatment, please describe the treatment medically likely to bring about such a material improvement in the applicant's functional capacity.

Mr. Xxxx is permanently incapacitated as previously described and unlikely to materially improve.

8. Based on your response to questions 5, 6, and 7 above, and your review of the Job Factors Form and any other materials in the binder regarding job duties, do you feel that the member:
- Can return to his described usual assignment, or any described Alternative Assignment with no work restrictions, or
  - Can return to his described usual assignment, with accommodations as described in the Job Factors Form, or
  - Can return to any of the described Alternative Assignments within his job class the demands of which are more congenial to his work restrictions (if so, please list the names of the appropriate alternative assignments)
  - Cannot return to his usual assignment regardless of the described reasonable accommodations, or



## Noam Z. Drazin, MD

Board Certified, Internal Medicine  
Board Certified, Medical Oncology

- e. Cannot return to any of the described alternative assignment

(D, E) The applicant cannot return to his usual assignment with accommodations or alternative assignments listed on the Job Factors Form. His limitations both physically and mentally deem him permanently incapacitated from performing any of those described duties.

9. The Applicant's record contains many references to his [REDACTED] having prostate cancer and his [REDACTED] having melanoma. If we accept that as factual, what is the medical probability that his condition is hereditary, as opposed to arising out of environment exposure, i.e. sunlight?

The applicant's family history of prostate cancer has no relevance to his current condition and limitations. Most cases of melanoma are environmental and understanding his 30+ years of sun exposure related to his job description indicate that his condition is more likely that not related to exposure alone.

10. In your opinion, which best describes the role of applicant's [REDACTED] employment in the causation of applicant's alleged cancerous incapacity:
- There is substantial evidence of a "real and measurable link" between applicant's [REDACTED] employment and his alleged incapacity, or
  - The role of applicant's employment is so inconsequential and speculative that it cannot be measured, or;
  - The employment setting contributed not at all to the alleged incapacity and was merely a passive stage or backdrop upon which the natural progression of applicant's underlying cancer condition manifested.

(A). It is clear from the job description and exposures over time, that his current incapacity is directly related to his prior employment with [REDACTED] County.

11. If you have found that the member is permanently incapacitated from all the assignments described in the Job Factor Form, are there other types of job assignments generally found in county service which the member could currently perform? If so, please generally describe the type of job that the member could perform.

Unfortunately, the patient in my evaluation is permanently incapacitated from all assignments.

Should you have any questions or concerns regarding the evaluation or to this report, please feel free to contact me.

Sincerely,

Noam Z. Drazin, MD

---

Board Certified, Internal Medicine  
Board Certified, Medical Oncology



Noam Z. Drazin, MD

Clinical Instructor, UCLA School of Medicine  
Diplomat, American Board of Internal Medicine and Medical Oncology

**SAMPLE**

Sample Report #2

Noam Z. Drazin, MD

Board Certified, Internal Medicine  
Board Certified, Medical Oncology

[REDACTED]

ATTENTION: [REDACTED]

Patient: Xxx Xxxxx (SS# xxx-xx-xxxx)

Examination Date: [REDACTED]

Comprehensive Consultation Report

The patient presents for evaluation on behalf of the [REDACTED] association regarding her current disability.

Job Description:

Ms. Xxxxx was a [REDACTED] from [REDACTED] required by working with the [REDACTED] to fill out applications and paperwork related to people who couldn't take care of themselves. Worked for the [REDACTED] office of [REDACTED], which included home visits and car travel in addition to the office requirements as well. The included job description (Attachment A) was for [REDACTED] only, but as mentioned she was employed through the [REDACTED] which came with additional duties prior to her premature retirement.

History of Illness:

Ms. Xxxxx is a very pleasant [REDACTED]-year-old woman with history of breast cancer and prior surgical and medical treatment who suffers from significant physical impairment due to expected adverse effects from treatment. Her ability to move, sit, and stand are limited by pain that is musculoskeletal in origin from prior chemotherapy and current treatment of her breast cancer. Arm swelling due to lymph channel disruption as part of her surgical treatment also has led to pain and impaired mobility even affecting her ability to use a telephone. She was in obvious discomfort during my evaluation after having spent over an hour in traffic en route to the appointment. Her prior degenerative joint disease contributes to the limited movement but was exacerbated by treatment for her breast cancer.

[REDACTED]

REVIEW OF MEDICAL RECORDS

[REDACTED] COUNTY ([REDACTED]) ADMINISTRATIVE RECORDS

Undated – [REDACTED] – Job Description: [REDACTED]. I have read and reviewed the job description including physical requirements as given to me by [REDACTED].

Undated – Disability Retirement Department Statement of Facts and Circumstances. I have read and reviewed the Disability Retirement Department Statement of Facts and Circumstances as provided to me by [REDACTED].

[REDACTED] – Tony Kwon, M.D. – Physician’s Report. The patient was substantially and permanently incapacitated. Diagnoses: 1) Chronic back pain. 2) Breast cancer. The patient would not be to return to perform the essential job duties of a [REDACTED] due to her medical diagnoses. Dr. Kwon felt the patient had poor prognosis to return to her job without medical intervention, surgery or treatment. Her last day of work was on [REDACTED].

[REDACTED] – Applicant Statement of Facts and Circumstances. I have read and reviewed the Applicant Statement of Facts and Circumstances as provided to me by [REDACTED].

[REDACTED] – Physical Requirements Questionnaire. I have read and reviewed the Physical Requirements Questionnaire as provided to me by [REDACTED].

WELLNESS CENTER

These records were reviewed and there was nothing of significance related to the patient’s breast cancer.

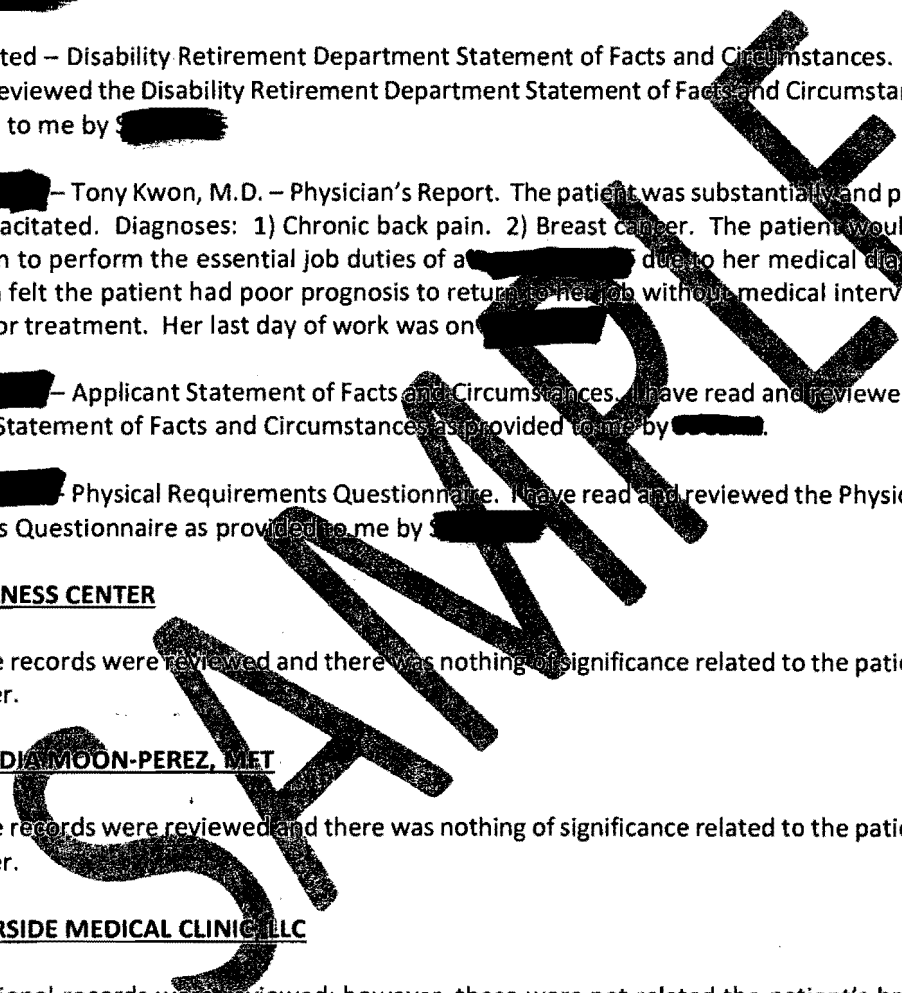
CLAUDIA MOON-PEREZ, MET

These records were reviewed and there was nothing of significance related to the patient’s breast cancer.

RIVERSIDE MEDICAL CLINIC LLC

Additional records were reviewed; however, these were not related the patient’s breast cancer and these were not summarized.

[REDACTED] – Laboratory Report. CBC with differential showed high RDW at 15.3 (range is 11.7-15.0). Basic metabolic panel showed high serum creatinine at 1.05 (range is 0.57-1.00), low eGFR at 53 (range is >59), and high sedimentation rate at 36 (range is 0-30).



██████████ Laboratory Report. CBC with differential showed high RDW at 15.7 (range is 11.7-15.0). Basic metabolic panel showed high serum creatinine at 1.14 (range is 0.57-1.00) and low eGFR at 48 (range is >59).

██████████ – Laboratory Report. Comprehensive metabolic panel showed high serum creatinine at 1.16 (range is 0.57-1.00), low eGFR at 51 (range is >59), and high sedimentation rate at 36 (range is 0-30).

██████████ – Donald Masee, M.D. – Bilateral Diagnostic Mammography. Impression: A 20 mm highly suspicious mass, deep upper outer quadrant of the right breast. BI-RADS 5; highly suggestive of malignancy.

██████████ Nicholas V. Zekos, M.D. – Progress Note. The patient noticed a lump in her right breast one month ago, which was tender to palpation. She reported that she had a sister with cancer of the breast. Examination revealed a palpable 2 cm mass in the right breast axillary tail. Assessment: Probable carcinoma of the right breast. She was referred to have an excisional biopsy and advised to return in about 7 days.

██████████ – Nicholas V. Zekos, M.D. – Progress Note. The patient returned to discuss possible right breast surgery. All her questions were answered. She opted to proceed with right partial mastectomy (lumpectomy) and sentinel lymph node biopsy with possible axillary lymphadenectomy to be followed by radiation. Her medications included Xanax, Tenormin, Celexa, Plavix, Dilacor XR, Isordil, Robaxin, Aciphex, Zocor, and Ambien. Assessment: Right breast cancer. Right breast surgery was scheduled on ██████████.

██████████ – Nicholas V. Zekos, M.D. – Operative Note. The patient underwent excisional biopsy of mass in the right breast, right partial mastectomy with axillary lymph node dissection. Postoperative Diagnosis: Carcinoma of the right breast.

██████████ Nicholas V. Zekos, M.D. – Progress Note. The patient followed up status post right breast surgery on ██████████. She was doing well. The drain was removed. She was told to follow-up in 2 days. Assessment: Unchanged.

██████████ – Nicholas V. Zekos, M.D. – Progress Note. The patient was seen again status post right lumpectomy and axillary lymph node dissection. She was doing okay. Her medications included Xanax, Tenormin, Celexa, Plavix, Dilacor XR, Norco, Isordil, Robaxin, Aciphex, Zocor, and Ambien. Examination showed well healed incision. It was noted that 3 of 11 lymph nodes were positive for cancer. Assessment: Unchanged. Skin staples were removed. She was referred to oncology.

██████████ – Ghaleb A. Saab, M.D. – Progress Note. The patient presented with a six-month history of a lump in the right breast. She eventually underwent a right breast lumpectomy and right axillary dissection which demonstrated 1.8 cm carcinoma metastatic to ██████████ lymph nodes on

Family history was positive for breast cancer in her sister. Examination was unremarkable. Assessment: 1) Status post right breast lumpectomy for 1.8 cm carcinoma metastatic to 3/8 nodes on 2) Hormone receptors were positive but HER2 was negative. Nuclear bone scan and tumor markers were requested as well as CT scan of the chest, abdomen, and pelvis. She was advised to return in 2 weeks for further recommendations.

Jaspert Brar, M.D. – CT of the Chest, Abdomen and Pelvis. Impression: Postoperative changes of the right breast including right breast moderate skin thickening. There was no definite evidence of distant metastatic disease to the chest, abdomen, or pelvis.

Ghaleb A. Saab, M.D. – Progress Note. The patient reported severe pain in her right axilla area and was requesting stronger narcotics. Examination of the right breast and axilla area showed no unusual swelling or discharge. Surgical strips were still in place. Wound was well healed. Assessment: Unchanged. The patient was reassured. She was advised to return in 1 week for further recommendations regarding chemotherapy followed by radiation and hormonal treatments.

Ghaleb A. Saab, M.D. – Progress Note. The patient was recovering from her right mastectomy. She had no unusual symptoms or complaints. She was ready for chemotherapy. Examination showed the right mastectomy site and axilla to be well healed. Assessment: Unchanged. Combination of Taxotere and Cytoxan for 6 cycles was considered. She was to return in 1 week for her first cycle of chemotherapy. She was referred for port placement.

Subbu Nagappan, M.D. – Progress Note. The patient was referred for placement of port a cath for adjuvant chemotherapy. Her medications included Xanax, Tenormin, Celexa, Decadron, Plavix, Dilacor XR, Norco, Isordil, Robaxin, Zofran, Neulasta, Aciphex, Zocor, and Ambien. Examination was unremarkable. Assessment: Breast carcinoma. Port was placed. Chest x-ray was ordered post port placement.

Ghaleb A. Saab, M.D. – Attending Physician Statement of Continued Disability. Dr. Saab indicated that the patient had locally advanced breast cancer and was undergoing IV chemotherapy every three weeks for six months.

Subbu Nagappan, M.D. – Operative Note. The patient underwent placement of left subclavian Port-A-Cath. Postoperative Diagnosis: Breast carcinoma.

Ghaleb A. Saab, M.D. – Progress Note. The patient came in for her first cycle of combination chemotherapy. She had no new complaints. Her blood pressure was 117/79 and was pounds. Assessment: Unchanged. First cycle of chemotherapy consisting of Taxotere and Cytoxan was administered. Decadron injection was also administered. She was advised to return in 3 weeks for labs.

██████████ – Ghaleb A. Saab, M.D. – Progress Note. The patient tolerated her chemotherapy relatively well except for mouth sores and constipation. Her medications included Xanax, Aprepitant, Tenormin, Celexa, Dilacor XR, Plavix, Norco, Isordil, Xylocaine, Robaxin, Zofran, Aciphex, Zantac, Zocor, and Ambien. Vital signs showed blood pressure of 116/72 and weight of ██████ pounds. Assessment: Unchanged. Second cycle of chemotherapy with Taxotere and Cytosan was administered. She was given ice chips to suck on during chemotherapy due to oral mucositis. She was advised to follow-up in 3 weeks.

██████████ – Ghaleb A. Saab, M.D. – Progress Note. The patient developed significant diffuse bone pain following her chemotherapy three weeks ago. This started 3 days post chemotherapy, consistent with Neulasta side effect. She reported that Advil and Tylenol did not help the pain, but hydrocodone did. Her CBC was within normal limits along with metabolic panel. Examination was unremarkable. Assessment: Unchanged. Third cycle of Cytosan and Taxotere chemotherapy was given. She was to suck on ice chips during chemo because of oral mucositis. She was prescribed with Norco 5/325 mg for Neulasta-induced bone pain. She was advised to return to clinic in 3 weeks for labs.

██████████ – Laboratory Report. CBC with differential showed high WBC at 27.8 (range is 4.8-10.8), low RBC at 3.16 (range is 4.20-5.40), low hemoglobin at 9.6 (range is 12.0-16.0), low hematocrit at 28.7 (range is 35.0-48.0), high RDW at 18.9 (range is 11.0-14.5), high neutrophils at 88.1 (range is 42.2-75.2), and low lymphocytes at 7.0 (range is 21.0-51.0).

██████████ – Tony S. Kwon, M.D. – Progress Note. The patient was complaining of rash on both hands for one week, which she felt related to chemotherapy treatments. She reported that she was applying Benadryl for relief. She was experiencing some altered bowel habits with chemotherapy. Overall, she had been doing okay, however. Her medications included Xanax, ciprofloxacin, Celexa, Plavix, Dilacor, Norco, Isordil, Xylocaine, Robaxin, Zofran, Aciphex, Zantac, Zocor, Ambien, and Rocephin. Vital signs showed blood pressure was 133/78 and weight was ██████ pounds. She was prescribed with Xerax and was advised to return in about 3 months.

██████████ Ghaleb A. Saab, M.D. – Progress Note. The patient developed urinary tract infection following her 3rd cycle of chemotherapy 3 weeks ago which was treated with antibiotics. She had minimal mucositis following her last chemotherapy. Her weight was stable and her labs were within normal limits. Diagnosis: Breast cancer, status post right breast lumpectomy. Her 4th cycle of chemotherapy was administered. Norco was provided as well as ice chips. Lab studies were requested. She was advised to follow up in about 3 weeks.

██████████ – Laboratory Report. CBC with differential showed high WBC at 18.8 (range is 4.8-10.8), low RBC at 3.23 (range is 4.20-5.40), low hemoglobin at 9.7 (range is 12.0-16.0), low hematocrit at 29.6 (range is 35.0-48.0), high RDW at 17.7 (range is 11.0-14.5), high neutrophils at 84 (range is 42.2-75.2), low lymphocytes at 6 (range is 14-46), high absolute neutrophils at 15.7 (range is 1.8-7.8), high absolute monocytes at 1.4 (range is 0.1-1.0), and high immature granulocytes at 3 (range is 0-2).

██████████ – Ghaleb A. Saab, M.D. – Progress Note. The patient tolerated her last cycle of chemotherapy better. She was on Norco for bone pain. She had no symptoms of oral mucositis, febrile symptoms, or symptoms of peripheral neuropathy. Vital signs showed blood pressure was ██████████. Assessment: Unchanged. Fifth cycle of chemotherapy was given. She was instructed to return in 3 weeks for last cycle of chemotherapy. Lab studies were ordered.

██████████ Ghaleb A. Saab, M.D. – Progress Note. The patient tolerated her last treatment better. She was still on Norco for bone pain secondary to Neulasta. She had no interval febrile symptoms or complaints. Blood pressure of 134/77. Assessment: Unchanged. Sixth cycle of chemotherapy consisted of Cytoxan and Taxotere was given. She was referred for adjuvant radiation therapy to right breast as planned. Arimidex 1 mg per day potential side effects were discussed. She was advised to return in 2 months.

██████████ – Anupam Gupta, M.D. – Progress Note. The patient complained of recurrent palpitations, with current episode started in the past 7 days and occurred 2-4 times per day associated with shortness of breath. She reported that she got shortness of breath easily while on the chemotherapy.

██████████ – Ghaleb A. Saab, M.D. – Progress Note. The patient had completed her 6 cycles of chemotherapy 3 weeks ago. She was afebrile. She reported recent onset of hot flashes associated with Arimidex. She complained of fatigue. Bilateral breast and axilla examination was unremarkable. Assessment: 1) Status post right breast lumpectomy for 1.8 cm carcinoma metastatic to 3/8 nodes on ██████████ 2) Hormone receptors where positive but HER2 was negative. 3) Benign leukocytosis. Arimidex 1 mg daily was prescribed. She was advised to return in 2 months.

██████████ – Ronald D. Lau, M.D. – Radiation Oncology Consultation. The patient presented for completion of radiotherapy to the right breast and peripheral lymphatics. She reportedly had a palpable mass in the upper outer breast back in ██████████ and had an abnormal mammogram. Her biopsy followed by lumpectomy with axillary lymph node dissection showed a 1.8 cm primary cancer and three metastatic lymph nodes, 11 removed. She was ER/PR positive, HER2/neu negative. Post lumpectomy, she received multiagent multi-course chemotherapy per Dr. Saab. Her medical history was significant for coronary artery disease with three heart stents placed in ██████████, hypertension, GERD, and partial hysterectomy in ██████████. She was taking atenolol, diltiazem, Aciphex, Celexa, simvastatin, Plavix, and Ambien. Physical examination showed alopecia and cross-wise upper outer quadrant scar at about 45-degree angle into the axilla. Left breast was benign. There was mild enlargement of the abdomen. Impression: Stage 2 lymph node positive right upper outer quadrant breast cancer. Dr. Lau recommended completion of radiotherapy to the right breast and to have axillary apex, infra and supraclavicular area nodal treatment.

██████████ – Ghaleb A. Saab, M.D. – Progress Note. The patient was status post 6 cycles of chemotherapy consisting of Cytoxan and Taxotere on ██████████. She was also status post radiation therapy. Assessment: 1) Status post right breast lumpectomy for 1.8 cm carcinoma metastatic to 3/8 nodes on ██████████ 2) Hormone receptors where positive but HER2 was negative. 3) Recent lower



thoracic and lumbar pain. PET/CT scan to rule out metastasis to liver/spine because of new symptoms. Continue Arimidex 1 mg daily. Reevaluation in 4 weeks.

██████████ – Ronald D. Lau, M.D. – Radiation Oncology Treatment Summary. It was documented that the patient started chemotherapy on ██████████ due to adenocarcinoma in the right breast stage 2. The rest of the report is illegible.

██████████ Ghaleb A. Saab, M.D. – Progress Note. The patient was tolerating Arimidex well. She reported increase in right chronic paralumbar pain. Her follow-up PET/CT scan was essentially negative except for heterogeneous uptake in the spine. Her labs and tumor markers were negative. Blood pressure was 130/75. Assessment: Unchanged. The patient was to continue Arimidex 1 mg daily. Bone scan was requested. She was advised to return in about 6 weeks.

██████████ – Ronald D. Lau, M.D. – Post Radiation Follow-up Evaluation. The patient stated she had good recovery over the interval month. She stated no residual problems or complaints regarding her treatment. Impression: The patient continued clinically with no evidence of disease (NED).

██████████ – Tony S. Kwon, M.D. – Progress Note. The patient returned for refill of her medication. She complained of mouth soreness and right-sided discomfort of her back. Otherwise, she was doing okay. Blood pressure of 146/72 and weight of ██████████ pounds. Right anterior rib area was slightly tender. Assessment: 1) Chronic angina. 2) Paroxysmal supraventricular tachycardia. 3) Anxiety. 4) Breast cancer. The patient was advised to follow up in one month.

██████████ – Ghaleb A. Saab, M.D. – Progress Note. The patient followed up for her right parathoracic pain and breast cancer as well as for her routine maintenance port flush. She continued to experience right parathoracic pain and discomfort. Her bone scan was negative. Her medications included Xanax, Arimidex, Tenormin, Zithromax, Celexa, diltiazem, Norco, Isordil, Xylocaine, Robaxin, Zofran, Plavix, AcipHex, Zantac, Zocor, Ambien, and Rocephin. Blood pressure was 149/78. Assessment: Unchanged. The patient was to continue Arimidex 1 mg daily. She was advised to stay off work until ██████████

██████████ Ghaleb A. Saab, M.D. – Progress Note. The patient was feeling better with less discomfort involving her right chest wall and flank. She was still on Arimidex daily. She underwent studies for SPE, IEP, and QIGs along with serum B12 which came back all normal. Blood pressure of 120/72 and weight of ██████████ pounds. Assessment: Unchanged. Port flush was done. She was to continue Arimidex daily. Lab studies including tumor markers were requested. She was advised to return in 4 months.

██████████ – Tony S. Kwon, M.D. – Progress Note. The patient had been doing well with her breast cancer recovery. Her strength had improved. She was back to 5 hours a day work.

██████████ – Joseph Quan, M.D. – Progress Note. The patient was recovering from chemotherapy for her breast cancer. She was still experiencing fatigue.

██████████ – Ghaleb A. Saab, M.D. – Progress Note. The patient followed up for treatment of breast cancer. She continued to suffer from right chest wall pain laterally. She was still on Arimidex daily. Right breast examination showed right partial mastectomy. Diffuse bone tenderness secondary to radiation therapy to right breast was noted. Assessment: Unchanged. Plan: Tumor markers were requested. She was advised to return in 7 weeks.

██████████ – Ghaleb A. Saab, M.D. – Progress Note. The patient was still on Arimidex and was tolerating it well. Her right chest wall discomfort was a lot better. Examination was unremarkable. Assessment: Unchanged. She was to continue Arimidex daily. Port flush was done. She was advised to return in 4 months.

██████████ – Erik N. Hill, M.D. – Bilateral Screening Mammogram. Impression: ACB BI-RADS 0. Incomplete. Needs additional imaging evaluation.

██████████ – Erik N. Hill, M.D. – Bilateral Digital Screening Mammogram. Impression: ACR BI-RADS category 2. Benign findings.

██████████ – Ghaleb A. Saab, M.D. – Progress Note. The patient returned for reevaluation of her breast cancer and port flush. She reported that she had been experiencing excessive fatigue, GERD, and epigastric pain for several months. Her medications included Xanax, Tenormin, Celexa, Plavix, Dilacor XR, Lasix, Norco, Xylocaine, Relafen, Protonix, Zocor, Arimidex, and Ambien. Assessment: Unchanged. She was to continue Arimidex. She was referred for EGD because of severe GERD, heartburn during the day, fatigue and lethargy despite Protonix. She was to follow up in 4 months.

██████████ – Ghaleb A. Saab, M.D. – Progress Note. The patient returned for her routine maintenance port a cath flush. Blood pressure was 139/83. Assessment: Unchanged. She was to continue Arimidex. She was advised to return in 6-8 weeks.

██████████ – Ghaleb A. Saab, M.D. – Progress Note. The patient came in for her routine maintenance port a cath flush. No new complaints in regards to her right breast cancer. Blood pressure was 102/65. Assessment: Unchanged. She was advised to return in 6-8 weeks.

██████████ – Ghaleb A. Saab, M.D. – Progress Note. The patient followed up for her routine maintenance port a cath flush with no new complaints. Examination was unremarkable. Assessment: Unchanged. The patient was advised to return in 6-8 weeks.

██████████ – Ghaleb A. Saab, M.D. – Progress Note. The patient returned for her routine maintenance port a cath flush with no complaint of pain. Her medications included Lasix, multivitamin,

Nitrostat, Zantac, Xanax, Tenormin, Celexa, Plavix, Dilacor XR, Nexium, Isordil, Protonix, and Ambien. Examination was unremarkable. Assessment: Unchanged. The patient was to return in 6-8 weeks.

█ – Ghaleb A. Saab, M.D. – Progress Note. The patient followed up for her right breast cancer. She had ongoing treatment with hormonal therapy. She complained of persistent right rib cage pain along with new mid back discomfort. Blood pressure was 145/73 and weight was █ pounds. Assessment: Unchanged. She was to continue Arimidex daily. Lab studies were requested as well as bone scan. Port flush was done.

█ – Ghaleb A. Saab, M.D. – Progress Note. The patient followed up for her routine maintenance port a cath flush. Blood pressure was 144/82 and weight was █ pounds. Assessment: Unchanged. She was to return in 6-8 weeks for port flushing.

█ – Ghaleb A. Saab, M.D. – Progress Note. The patient returned for her routine maintenance port a cath flush. Blood pressure of 144/82 and weight of █ pounds. Assessment: 1) Status post right breast lumpectomy for 1.8 cm carcinoma metastatic to 3/8 nodes on █ 2) Hormone receptors were positive but HER2 was negative. The patient was advised to return in 6-8 weeks for another port flushing.

█ – Ghaleb A. Saab, M.D. – Progress Note. The patient came in for her routine maintenance port a cath flush with no complaints of pain. Her medications included Xanax, multivitamin, Nitrostat, Zantac, Arimidex, Tenormin, Celexa, Temovate, Plavix, Dilat-XR, Tussi-Organidin, Isordil, Xylocaine, Protonix, and Ambien. Examination was unremarkable. The patient was advised to return in 6-8 weeks for port flushing.

█ – Ghaleb A. Saab, M.D. – Progress Note. The patient returned for follow-up treatment of breast cancer. She was status post breast lumpectomy and radiation therapy. She reported persistent right parathoracic and flank discomfort secondary to surgery and radiation therapy to the right chest wall. She remained on Arimidex. Examination was unremarkable. Assessment: 1) Status post right breast lumpectomy for 1.8 cm carcinoma metastatic to 3/8 nodes, █ 2) Hormone receptors were positive but HER2 was negative. 3) Recent lower thoracic and lumbar pain x few months, questionable. The patient was advised to continue Arimidex 1 mg daily.

█ – Samantha H. Kaura, M.D. – Bilateral Screening Mammogram. Impression: Left breast: Incomplete. Need additional imaging. ACR BI-RADS category 0, incomplete. Right breast: Benign findings of stable postsurgical changes. No evidence of malignancy. ACR BI-RADS category 2. Benign findings.

█ – Erik N. Hill, M.D. – Left Breast Ultrasound. Impression: No ultrasound abnormality appreciated in the retroareolar and central left breast.

██████ – Erik N. Hill, M.D. – Left Diagnostic Mammogram. Impression: ACR BI-RADS category 2. Benign findings.

██████ – Ghaleb A. Saab, M.D. – Progress Note. The patient reported severe incapacitating low back pain down to the right buttock for a few weeks. She continued to manage her breast cancer with Arimidex daily. Examination was unremarkable. Assessment: Unchanged. Plan was to continue Arimidex 1 mg daily and Aromasin 25 mg daily, and repeat nuclear bone scan.

██████ – Gergette Sacay, RNP – Progress Note. The patient returned for discussion of result of mammogram and ultrasound. The left breast ultrasound showed no ultrasound abnormality appreciated in the retroareolar and central left breast. The left diagnostic mammogram showed ACR BI-RADS category 2; benign findings. The patient was advised to return for annual screening mammography in ██████

██████ – Ghaleb A. Saab, M.D. – Progress Note. The patient was seen for follow-up of her breast cancer. Her CEA and CA were within normal limits. She continued to have lower lumbar pain radiating to the right buttock and lateral thigh. Assessment: Unchanged. Treatment plan was unchanged.

**Past medical History:**

Breast Cancer - ██████ Right breast with lymph node involvement

- Chemotherapy (Taxotere/cyclooxan x 6 cycles)
- radiation therapy (35 fractions) to chest wall and axilla
- aromatase inhibitor (anastrozole/exemestane due to muscle aches)

Coronary artery disease – stents

Osteoporosis (post breast cancer)

GERD

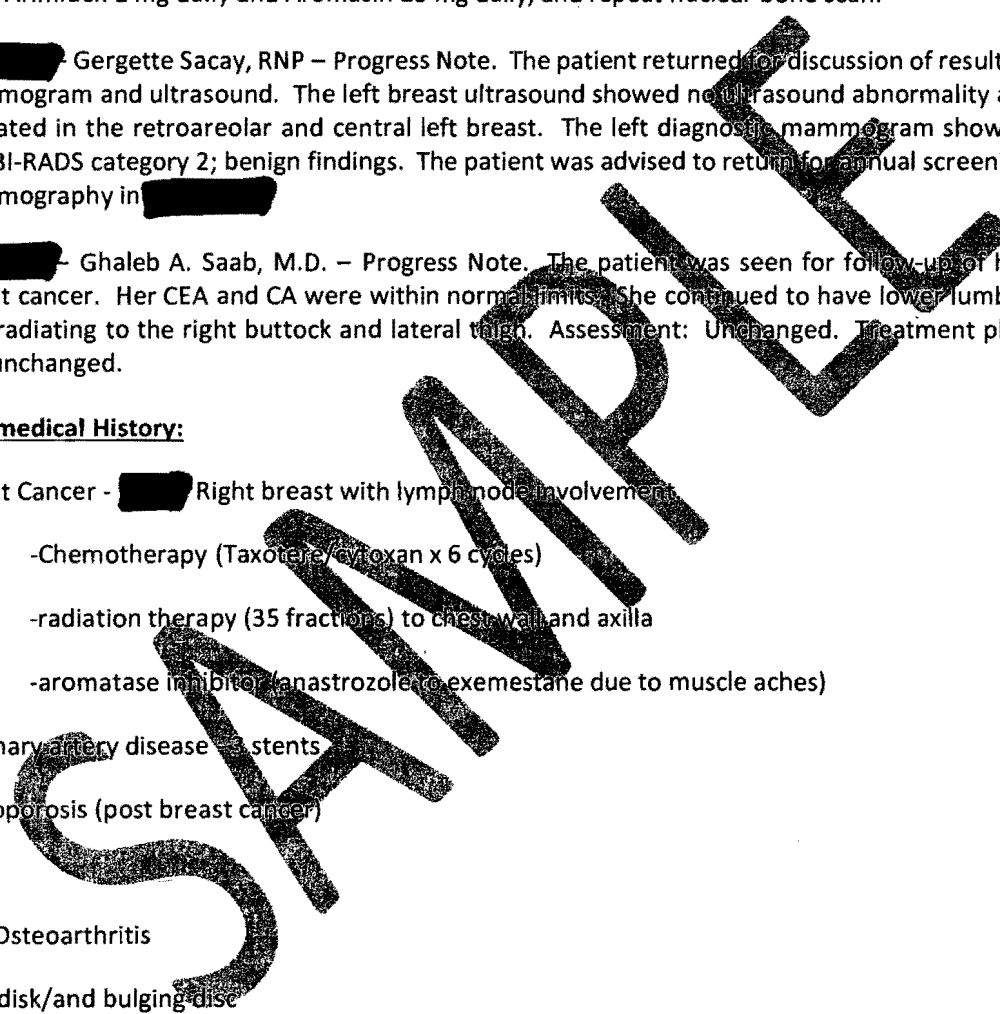
DJD/Osteoarthritis

back disk/and bulging disc

Hypertension

Depression/Anxiety

lymphedema (due to lymph node dissection)



**Past surgical History**

Right lumpectomy and lymph node dissection [REDACTED]

Coronary stent placement x 3

hysterectomy [REDACTED] years old)

port (chest) placement for chemo

**Family History:**

[REDACTED] - head and neck cancer

[REDACTED] - Breast Cancer [REDACTED]

[REDACTED] - CAD/MI

[REDACTED] - Heart Failure

[REDACTED] (Maternal) - breast cancer

**Social History**

**Medications:**

Ambien, Celexa, Fosamax, Morphine sulfate-10mg, Nexium, Exemestane, Isosorbide, Xanax, Plavix, and Tenormin

**Current complaints:**

Severe back pain, muscle aches, right arm/hand swelling, inability to sit or stand for extended periods of time. She describes limitations to ADL's including bathing (unable to herself), bed making, mopping, cleaning.

**Physical Examination:**

The patient is a [REDACTED] year-old alert, cooperative and oriented English speaking female, in no acute distress. The following vital signs and measurements are taken today on examination: Weight: [REDACTED] pounds. Height: [REDACTED]. Blood Pressure: 165/100. Heart Rate: 80.

SAMPLE

Skin:

normal, without lesions

Head:

The patient's head is normocephalic and atraumatic. The patient's facial muscles show good contour and symmetry. There is no scleral icterus and no tenderness of the skull noted on examination.

EENT:

Pupils are equally reactive to light and accommodation. Extraocular movements are intact. The throat is clear. Hearing appears to be uninvolved. The patient's neck is overall supple with no evidence of lymphadenopathy, thyromegaly or bruits. Dentition is good.

Thorax:

The patient exhibits good bilateral rib excursion during respiration. Lungs are clear during percussion and auscultation. The heart reveals a regular rate and rhythm and no murmurs are noted.

Abdomen:

The abdomen is normal, non-tender without organomegaly. Normoactive bowel sounds are present.

Genitalia and Rectal:

Examination is deferred.

Musculoskeletal Examination:

There is no tenderness or rigidity of the cervical, thoracic or lumbar sections of the spine. However, there is some point tenderness at the lower lumbar and sacral spine.

Upper Extremities:

There is no asymmetry, deformity, or tenderness. Range of motion, consisting of flexion, abduction, external rotation, and internal rotation, is within normal limits. Right arm has clear increased girth and dimension consistent with lymphedema.

Lower Extremities:

The patient's lower extremities appear to be normal and the dermatomes were apparently uninvolved. The reflexes are a normal +2.

Neurological Examination:

Cranial nerves 2-12 are intact. Deep tendon reflexes are 2+ bilaterally. Superficial reflexes are found to be within normal limits. There are no abnormal reflexes detected and there is no abnormality of sensation or coordination.

Motor strength is normal 4-/5 but objectively less strong on the right due to pain

Gait testing/observation:

limited walking/mobility with obvious pain during ambulation. Walks without assistive device.

Impression:

The applicant (Ms. Xxxxx) has objective severe back/muscle pain and lymphedema which will limit her ability to function in any capacity as a [REDACTED] from her previous capacity working in the [REDACTED]. Her previously noted degenerative joint disease and arthritis (osteo) were complicated and exacerbated by intensive chemotherapy for breast cancer. Her current treatment with an aromatase inhibitor has expected toxicity of worsening and exacerbating muscle aches and tenderness. This combination of treatment has impaired Ms. Xxxxx's ability to perform any of her current job duties.

**Specific Questions:**

**1. Incapacities**

Mr. Xxxxx's current incapacities include prolonged standing, prolonged sitting, reaching, kneeling, crouching, prolonged driving. She is also impaired secondary to her right arm swelling and immobility. This makes activities such as using the telephone difficult. I believe these to be permanent incapacities as they are exacerbated and caused by her treatment which is currently ongoing.

**2. Job Duties Unable to Perform**

The applicant is unable to sit for prolonged periods of time which would limit her ability to complete paperwork and file/process said paperwork as required per her job description. Her limited mobility of her right arm and hand will make it impossible to complete/file paperwork as well as answer telephone calls on a regular basis. Her exacerbated muscle pain and limited mobility will make it impossible for the applicant to drive for home visits, etc.

**3. Job Duties Able to Perform**

In my opinion there are no job duties as described in Attachment A that the applicant will be able to perform on a regular basis with her current disability.

#### 4. Permanent/Temporary Incapacities

I believe Ms. Xxxxx's incapacity to be permanent as treatment of her current malignancy will be continued for the next 5-10 years. The documented right sided lymphedema is likely to be permanent which has and will continue to impact her ability to work. As mentioned above, it appears to be affecting her home activities of daily living (ADL's) as well.

#### 5. Contributing Factors

I do not believe that any of her employment has been a contributing factor towards her current disability. Her current disability is directly attributable to her diagnosis of breast cancer and her treatment both past and present.

#### 6. Excluding Employment Contributing Factors

Excluding employment contributing factors, Ms. Xxxxx would still have the same incapacities she has now.

#### 7. Capable of Gainful Employment

I have to believe that unfortunately due to her current condition the applicant is unable to be gainfully employed. Her disability extends to personal ADL difficulties including daily menial tasks. Pure desk duties would not be possible due to her limitations to extended seating, writing, or using a telephone.

Should you have any questions or concerns regarding the evaluation or this report, please feel free to contact me.

Sincerely,

[REDACTED]

Noam Brazin, MD  
Clinical Instructor, UCLA School of Medicine  
Diplomat, American Board of Internal Medicine and Medical Oncology





June 10, 2016

TO: Each Member  
Board of Retirement

FROM: Disability Procedures & Services Committee  
Vivian H. Gray, Chair  
William de la Garza, Vice Chair  
Yves Chery  
Les Robbins  
David Muir, Alternate

FOR: July 6, 2016 Board of Retirement Meeting

SUBJECT: **CONSIDER APPLICATION(S) FOR LACERA PANEL OF EXAMINING PHYSICIAN(S)**

On June 1, 2016, the Disability Procedures & Services Committee reviewed the attached application for the LACERA Panel of Examining Physicians.

The application package has been reviewed by the Committee. After discussion, the Committee voted to accept the application of the following physician and submit to the Board of Retirement for approval to the LACERA panel.

**IT IS THEREFORE RECOMMENDED THAT** the Board approve the following physician to the LACERA Panel of Physicians for the purpose of examining disability retirement applicants.

**JONATHAN T. NASSOS, M.D. - Board Certified Orthopaedist**


Attachments

VG:RC/mb



May 17, 2016

TO: Disability Procedures & Services Committee  
Vivian H. Gray, Chair  
William de la Garza, Vice Chair  
Yves Chery  
Les Robbins  
David Muir, Alternate

FROM: Ricki Contreras, Manager   
Disability Retirement Services

FOR: June 1, 2016, Disability Procedures and Services Committee Meeting

SUBJECT: **CONSIDER APPLICATION OF JONATHAN T. NASSOS, M.D., AS A LACERA PANEL PHYSICIAN**

On May 4, 2016, Debbie Semnanian interviewed Jonathan T. Nassos, M.D., a physician seeking appointment to the LACERA Panel of Examining Physicians.

Attached for your review and consideration are:

- Staff's Interview Summary and Recommendation
- Panel Physician Application
- Curriculum Vitae
- Sample Report(s).

**IT IS THEREFORE RECOMMENDED THAT THE COMMITTEE** accept the staff recommendation to submit the application of Jonathan T. Nassos, M.D., to the Board of Retirement for approval to the LACERA Panel of Examining Physicians.

Attachments

JJ:RC/mb

NOTED AND REVIEWED:

  
JJ Popowich, Assistant Executive Officer

Date: 5/23/16



May 17, 2016

**TO: Ricki Contreras, Manager**  
Disability Retirement Services

**FROM: Debbie Semnanian**  
Disability Retirement Specialist Supervisor

**Debbie Semnanian, WCCP** *DS*  
Supervising Disability Retirement Specialist

**SUBJECT: INTERVIEW OF ORTHOPAEDIST APPLYING FOR  
LACERA'S PHYSICIAN'S PANEL**

On May 4, 2016, I interviewed **Jonathan T. Nassos, M.D.** at his office at 5651 Sepulveda Blvd., Suite #201, Sherman Oaks, CA 91411. The office space is located in a well-maintained, 3-story building with a patient paid parking lot (maximum fee \$6.00) surrounding the building.

Dr. Nassos is Board Certified in orthopaedics and has been in private practice for approximately ten years. His office has three examination rooms. He estimates that 90 percent of his practice is devoted to patient treatment, while the other 10 percent of his time is devoted to IME evaluations in workers' compensation. He shares office space with two other physicians, a pain management specialist, and Dr. Edwin Haronian, who is also a LACERA panel orthopaedist.

As referenced in his Curriculum Vitae, Dr. Nassos graduated from Loyola University Chicago - Stritch School of Medicine, with his medical degree in 2003. He completed a surgery Internship at Loyola University Chicago Department of Surgery, and his Residency at the Loyola University Chicago Orthopaedic Surgery Residency Program. Dr. Nassos completed an Orthopaedic Sports Medicine Fellowship at Kerlan-Jobe Orthopaedic Clinic in Los Angeles.

The office occupies the entire second floor of the building. It was clean with ample lobby seating. A handicap accessible restroom is located within the office.

Staff reviewed the LACERA Disability Retirement procedures and expectations in its evaluation of County Employees applying for both service connected and non-service connected disability retirements. The importance of preparing impartial and non-discriminatory reports that are clear and concise and address issues of causation and incapacity was discussed with the doctor. He understood that he would adhere strictly to the HIPAA laws that would also apply for LACERA reports. Staff reviewed with Dr. Nassos the Panel Physician Guidelines for evaluating LACERA applicants and defined the relationship between workers'

Interview of Potential Panel Physician  
Page 2 of 2

compensation and disability retirement. Staff discussed the need to rely on his own objective and subjective findings rather than the opinions of previous physician reports and/or comments.

Dr. Nassos agreed to adhere to LACERA's standard of having his evaluation reports sent to us within 30 days of examination. Staff confirmed that Dr. Nassos is agreeable with accepting payment pursuant to LACERA's contract and billing procedures. Dr. Nassos was informed that if he is approved by the Board to be on our panel of physicians, he is required to contact the specialist assigned to the case for approval of any special tests or extraordinary charges. He has also been advised of the requirement to immediately notify LACERA if any license, Board certification, or insurance coverage is lapsed, suspended or revoked. He was also informed that a Quality Control Questionnaire is sent to each applicant regarding their visit.

**RECOMMENDATION**

Based on our interview and the need for his specialty in his geographic area, staff recommends Dr. Nassos' application be presented to the Board for approval as a LACERA Panel Physician.



300 N. Lake Ave., Pasadena, CA 91101 ■ Mail to : PO Box 7060, Pasadena, CA 91109-706 626/564-2419 • 800/786-6464


GENERAL INFORMATION		Date
Group Name:		3/20/16
Physician Name: Jonathan Nassos		
I. Primary Address: 5651 Sepulveda Blvd. Ste 201 Sherman Oaks, CA 91411		
Contact Person: Flori	Title: Office Manager	
Telephone:	Fax:	
II. Secondary Address		
Contact Person	Title	
Telephone	Fax	
PHYSICIAN BACKGROUND		
Field of Specialty: Orthopaedic Surgery	Subspecialty: Sports Medicine	
Board Certification: <input checked="" type="checkbox"/> Yes <input type="checkbox"/> No	License #: A108187	Expiration Date
EXPERIENCE		
Indicate the number of years experience that you have in each category.		
Evaluation Type		
I. Workers' Compensation Evaluations		
<input checked="" type="checkbox"/> Defense	How Long? 7 yrs	<input checked="" type="checkbox"/> TIME
<input checked="" type="checkbox"/> Applicant	How Long? 7 yrs	<input checked="" type="checkbox"/> QME
<input type="checkbox"/> AME	How Long?	How Long? 7 hrs
<input type="checkbox"/> AME	How Long?	How Long? 1 yr
II. <input type="checkbox"/> Disability Evaluations How Long? _____		
For What Public or Private Organizations?		
Currently Treating? <input checked="" type="checkbox"/> Yes <input type="checkbox"/> No		
Time Devoted to:	Treatment: 90 %	Evaluations: 10 %
Estimated Time from Appointment to Examination		Able to Submit a Final Report in 30 days?
<input checked="" type="checkbox"/> 2 weeks		<input checked="" type="checkbox"/> Yes
<input type="checkbox"/> 3-4 Weeks		<input type="checkbox"/> No
<input type="checkbox"/> Over a month		
LACERA's Fee Schedule		
Examination and Initial Report by Physician	\$1,500.00 flat fee	
Review of Records by Physician	\$350.00/hour	
Review of Records by Registered Nurse	\$75.00/hour	
Supplemental Report	\$350.00/hour	

Other Fees	
Physician's testimony at Administrative Hearing (includes travel & wait time)	\$350.00/hour
Deposition Fee at Physician's office	\$350.00/hour
Preparation for Expert Testimony at administrative Hearing	\$350.00/hour
Expert Witness Fees in Superior or Appellate Court	\$3,500.00 half day \$7,000 full day
Physician agrees with LACERA's fee schedule?      Yes      No	
Comments	

Name of person completing this form:

Jonathan T. Nessus  
(Please Print Name)

Title: Orthopaedic Surgeon

Physician Signature: 

Date: 3/20/16

FOR OFFICE USE ONLY	
Physician Interview and Sight Inspection Schedule	
Interview Date: <u>5/4/16</u>	Interview Time: <u>4:00 pm</u>
Interviewer: <u>Debbie Jannace</u>	

# Jonathan T. Nassos, M.D.

---

## OFFICE ADDRESSES

9033 Wilshire Boulevard, Suite 401  
Beverly Hills, CA 90211  
Phone: (310) 273-2731  
Fax: (310) 273-2704  
Email: jtnassos@gmail.com

5651 Sepulveda Blvd. Ste.201  
Sherman Oaks, CA 91411  
Phone: (818) 788-2400  
Fax: (818) 788-2453

724 Corporate Center Drive, Second Floor  
Pomona, CA 91768  
Phone: (909) 622-6222  
Fax: (909) 622-6220

## EDUCATION

- 2009-10            Orthopaedic Sports Medicine Fellowship**  
Kerlan-Jobe Orthopaedic Clinic  
Los Angeles, CA
- 2004-08            Orthopaedic Surgery Resident**  
Loyola University Chicago Orthopaedic Surgery Residency Program  
Training Sites: Loyola University Medical Center, Maywood, IL  
Edward Hines, Jr. VA Hospital, Hines, IL  
Shriner's Hospital for Children, Chicago, IL  
Surgical Mission Trip, Buga, Colombia, S.A. 2006,  
2007
- 2003-04            Surgery Internship**  
Loyola University Chicago Department of Surgery  
Training Sites: Loyola University Medical Center, Maywood, IL  
Edward Hines, Jr. VA Hospital, Hines, IL  
Resurrection Medical Center, Chicago, IL
- 1999-03            Doctor of Medicine**  
Loyola University Chicago – Stritch School of Medicine  
Training Sites: Loyola University Medical Center, Maywood, IL  
Hines / VA Hospital, Maywood, IL  
Resurrection Medical Center, Chicago, IL  
MacNeal Hospital, Berwyn, IL
- 1995-99            Bachelor of Arts, Economics, Distinction in Economics**  
University of Illinois, Urbana-Champaign, IL

# Jonathan T. Nassos, M.D.

---

## PROFESSIONAL APPOINTMENTS

- 2013-Present**      **Attending Staff Physician**  
Cedars-Sinai Medical Center, Los Angeles, CA  
Glendale Adventist Medical Center, Los Angeles, CA  
Southern California Hospital, Culver City, CA
- 2012-Present**      Olympia Medical Center, Los Angeles, CA  
Mission Community Hospital, Panorama City, CA
- 2008-2012**      Elmhurst Memorial Hospital, Elmhurst, IL  
Alexian Brothers Medical Center, Elk Grove Village, IL
- 2008-2010**      Swedish Covenant Hospital, Chicago, IL
- 2009-10**          **Faculty Fellow**  
USC University Hospital, Los Angeles, CA
- 2008-09**          **Consultant**  
Edward Hines, Jr. VA Hospital, Hines, IL

## EMPLOYMENT

- 2012-Present**      **Nassos Orthopaedic Surgery and Sports Medicine**  
CEO/Attending Physician  
Beverly Hills, CA
- 2008-2012**      **G & T Orthopaedics and Sports Medicine**  
Attending Physician  
Chicago, IL
- 2009-10**          **Orthopaedic Sports Medicine Fellow**  
Kerlan-Jobe Orthopaedic Clinic  
Los Angeles, CA
- 2004-08**          **Orthopaedic Surgery Resident**  
Loyola University Chicago Orthopaedic Surgery Residency Program  
Maywood, IL
- 2003-04**          **Surgery Intern**  
Loyola University Chicago Department of Surgery  
Maywood, IL
- 2002-03**          **Loyola University Chicago Stritch School of Medicine**  
Medical Student Tutor
- 1997**              **Hospital Administrative Intern**  
Resurrection Medical Center, Chicago, IL



# Jonathan T. Nassos, M.D.

---

## HONORS/AWARDS/GRANTS

2008	JBJS/OREF Journal Club Grant
2008	Schwartz Traveling Fellowship
2008	Excellence in Research Award – Loyola University Chicago, Department of Orthopaedic Surgery
2008	OTA Resident Scholarship
2007	AANA Resident Scholarship
2006	Magis Award – Loyola University Medical Center
2005	Unrestricted Resident Research Grant - Medtronic
2003	Miller Scholarship –Loyola University Chicago Stritch School of Medicine
1999	Omicron Delta Epsilon – International Honor Society for Economics
1999	Dean’s List – University of Illinois at Urbana-Champaign

## PUBLICATIONS

Nassos JT, Sullivan, J, ElAttrache NS, Mejia MR, Yocum LA. Return to play in overhead athletes following dominant arm glenohumeral dislocation. (Submitted for publication to *Orthop J of Sports Med*).

Nassos JT, ElAttrache NS, Angel MJ, Tibone JE, , Limpisvasti O, Lee TQ. Optimizing a water-tight construct in arthroscopic rotator cuff repair. *J Shoulder Elbow Surg*. 2012 May;21(5):589-96.

Nassos JT, Ghanayem AJ, Sasso RC, Tzermiadianos MN, Voronov LI, Havey RM, Rinella AS, Carandang G, Patwardhan AG. A biomechanical evaluation of segmental occipito-atlanto-axial fixation techniques. *Spine*. 2009 Dec 1;34(25):2740-4.

Nassos JT, Chudik S. Arthroscopic rotator cuff repair with biceps tendon augmentation. *Am J Orthop*. 2009 Jun 38(6):279-81.

Nassos JT, Ghanayem AJ. Segmental stabilization of the occipitocervical junction with respect to the vertebral artery. *Cont Spine Surg*. 2007; 8: 1-6.

Nassos J, Rabin S. The medical liability crisis. *Loyola Orthop J*. 2005;14:64-7.

Nassos JT, Hopkinson WJ, Pinzur MS, Stanley SK. Lower extremity amputee functional outcomes after lower extremity fractures. *Loyola Orthop J*. 2004; 13:74-7.

Bush-Joseph C, Berger R, Virkus W, Nassos J. Selective Exposures in Orthopaedic Surgery: The Knee. (Digital media), American Academy of Orthopaedic Surgeons, Rosemont, IL. 2002.

# Jonathan T. Nassos, M.D.

---

## PRESENTATIONS/ABSTRACTS

Knee Arthritis. Community Seminar, Beverly Hills, CA, December 6, 2012.

The Knee. WCLA Medical Seminar, The Chicago Cultural Center, Chicago, IL, September 16, 2011.

Optimizing a Water-Tight Construct in Arthroscopic Rotator Cuff Repair. Nassos JT, ElAttrache N, Angel M, Tibone JE, Limpisvasti O, Lee TQ. American Shoulder and Elbow Surgeons Closed Meeting. Scottsdale, AZ, October 20-23, 2010.

Return to play in overhead athletes following dominant arm glenohumeral dislocation. Nassos JT, ElAttrache NS, Mejia MR, Yocum LA. Kerlan-Jobe Alumni Research Conference, Providence, RI, July 16, 2010.

Optimizing a water-tight construct in arthroscopic rotator cuff repair. Nassos JT, ElAttrache NS, Angel MJ, Tibone JE, Limpisvasti O, Lee TQ. Kerlan-Jobe Alumni Research Conference, Providence, RI, July 16, 2010.

Primary Osteoarthritis of the Elbow. Kerlan-Jobe Orthopaedic Clinic, Los Angeles, CA. April 28, 2010.

Valgus Instability in the Overhead Athlete. Kerlan-Jobe Orthopaedic Clinic, Los Angeles, CA. December 10, 2009.

The Middle Age Workout. Elmhurst Center for Health, Elmhurst, IL. October 7, 2008.

Massive Rotator Cuff Tears. Loyola University Medical Center, Maywood, IL. Department of Orthopaedic Surgery and Rehabilitation, Grand Rounds, June 5, 2008.

Valgus Instability of the Elbow in the Throwing Athlete. Loyola University Medical Center, Maywood, IL. Department of Orthopaedic Surgery and Rehabilitation, Grand Rounds, March 15, 2007.

Evaluation of Segmental Occipito-Atlanto-Axial Fixation Techniques with Respect to Risk to the Vertebral Artery. Ghanayem A, Nassos J, Tzermiadianos M, Voronov L, Patwardhan A. Biomechanical Cervical Spine Research Society-European Section, Berlin, Germany, May 17 – 19, 2006.

A Biomechanical Evaluation of Segmental Occipito-Atlanto-Axial Fixation Techniques with Respect to Risk to the Vertebral Artery. Nassos J, Tzermiadianos M, Voronov L, Ghanayem A, Patwardhan A. American Spinal Injury Association Annual Meeting, Boston, June 25-28, 2006.

A Biomechanical Evaluation of Segmental Occipito-Atlanto-Axial Fixation Techniques with Respect to Risk to the Vertebral Artery. Nassos J, Tzermiadianos M, Voronov L, Ghanayem A, Patwardhan A. Spine Across the Sea Annual Meeting, Maui, Hawaii, July 23-27, 2006.

A Biomechanical Evaluation of Segmental Occipito-Atlanto-Axial Fixation Techniques with Respect to Risk to the Vertebral Artery. Nassos J, Sasso R, Ghanayem A, Tzermiadianos M, Voronov L, Patwardhan A. *NASS Annual Meeting*, Seattle, Washington, September 26-30, 2006.

# Jonathan T. Nassos, M.D.

---

## PROFESSIONAL MEMBERSHIPS/COMMITTEES

2011 – 12	Orthopaedic Consultant – Chicago Rush Arena Football Team
2009 - 10	Assistant Team Physician – Los Angeles Lakers
2009 – 10	Assistant Team Physician – Los Angeles Dodgers
2009 - 10	Assistant Team Physician – Los Angeles Kings
2009 – 10	Assistant Team Physician – Los Angeles Sparks
2009 – 10	Assistant Team Physician – Anaheim Ducks
2009 – 10	Assistant Team Physician – Loyola Maramount University
2013 – Present	Los Angeles County Medical Association - Member
2013 – Present	California Medical Association – Member
2015 - Present	California Orthopaedic Association, Member
2004 - Present	American Academy of Orthopaedic Surgeons – Active Fellow
2007 - Present	Arthroscopy Association of North America- Active Member
2009 - Present	Associate Master Instructor of Arthroscopy, AANA
2009 - Present	American Orthopaedic Society for Sports Medicine – Active Member
2007 - 08	Loyola University Chicago Stritch School of Medicine – Committee on Admissions
2007 - 08	Assistant Team Physician - Loyola University Chicago
2007 - 08	Assistant Team Physician – Lewis University

## LICENSURE/CERTIFICATIONS

2015	Qualified Medical Evaluator – State of California
2012	Board Certified – American Board of Orthopaedic Surgery
2011	Board Certified – American Board of Independent Medical Examiners
2009-Present	California License A108187
2005-Present	Illinois License 36114903



JONATHAN T. NASSOS, M.D.

—ORTHOPAEDIC SURGERY & SPORTS MEDICINE—

Sample #1

Diplomate, American Board of Orthopaedic Surgery

[REDACTED]

Fellow, American Academy of Orthopaedic Surgeons

[REDACTED]

Member, American Orthopaedic Society for Sports Medicine

Patient Name : [REDACTED]

Date of Service : [REDACTED]

Employer : [REDACTED]

Member, Arthroscopy Assoc. of North America

Date of Birth : [REDACTED]

Date of Injury : [REDACTED]

File # : [REDACTED]

PERMANENT AND STATIONARY REPORT OF A PRIMARY TREATING PHYSICIAN

HISTORY OF INJURY:

[REDACTED] is a [REDACTED] year-old right-hand-dominant male who sustained industrial injuries on [REDACTED], while working as a [REDACTED] and [REDACTED] for [REDACTED]. On the date of injury, the patient was working in the inside a truck container when a co-worker who was trying to operate an electric pallet jack, lost control of the jack which then ran over his feet and pushed him up against the wall of the container. The patient attempted to pull his feet out for underneath the pallet jack but was trapped between the wall of the container and the pallet jack. He experienced immediate pain in the right ankle and foot. His co-workers helped him get loose from underneath the jack but he could not walk and had to crawl out of the container. He was in excruciating pain in both ankle worse on the right. Paramedics were called to the scene where he was transported to [REDACTED] Medical Center where he was examined by the doctor on duty. X-rays of the feet were performed which demonstrated two fractures of the right ankle. Surgery was recommended and he was going to be referred to a specialist. He was administered an injection of pain medication to help alleviate the pain. He was prescribed medication, dispensed crutches and released.

His employer referred him to an industrial clinic where he was briefly seen but no other treatment was provided.

The patient contacted his employer and was referred to an orthopedist in Los Angles. He has been seen on two occasions but no other treatment was

5651 SEPULVEDA BLVD., STE 201  
SHERMAN OAKS, CA 91411  
PH: (818) 788-2400  
FX: (818) 788-2453

9033 WILSHIRE BLVD., STE 401  
BEVERLY HILLS, CA 90211  
PH: (310) 273-2731  
FX: (310) 273-2704

724 CORPORATE CENTER DRIVE  
SECOND FLOOR  
POMONA, CA 91768  
PH: (909) 622-6222  
FX: (909) 622-6220

[REDACTED]  
[REDACTED]  
Page 2 of 10

rendered.

He has not undergone any additional x-rays or diagnostic studies. He was referred for surgical consult.

He scheduled to undergo surgery of the right ankle on [REDACTED] He does not know the name of the physician but will take place at [REDACTED]

He presents to my office today for a comprehensive orthopedic evaluation.

**JOB DESCRIPTION:**

The patient began employment with [REDACTED] on [REDACTED] as a [REDACTED] He worked eight hours a day, five days a week with regular overtime up to 16 hours a day.

His job duties at the time of injury included: unloading boxes of merchandise from truck containers which contained 2000-4000 boxes; the boxes weighed between 15 to 60 pounds; he unloaded 3-4 containers a day; the boxes were loaded onto a pallet in the container and then the pallets were removed with pallet jack. He worked with two or three other employees.

The physical activities included prolonged standing and walking, as well as continuous fine maneuvering of his hands and fingers, and repetitive bending, stooping, squatting, kneeling, twisting, turning, forceful pulling and pushing, forceful gripping and grasping, lifting and carrying 60 pounds, torquing, reaching below, at and above shoulder levels.

**MEDICAL TREATMENT TO DATE:**

The patient has undergone physical therapy, medication use, as well as surgical intervention to the right ankle since the time of his injury [REDACTED]

**CURRENT WORK STATUS:**

The patient is currently not working. He last worked on [REDACTED]

He is currently receiving disability benefits.

**EMPLOYMENT HISTORY:**

The patient states that prior to working for [REDACTED] the patient lived out of the country and did not work.

**PRESENT COMPLAINTS:**

**Cervical Spine:**

The patient complains of continuous aching pain in the neck, which increases to sharp and shooting pain. There is cracking and grinding of the neck with range of motion and twisting and turning the head and neck. The pain is aggravated with flexing or extending the head and neck, turning his head from side to side, prolonged positioning of the head and neck, forward bending, pushing, pulling, lifting and carrying greater than 5-10 pounds, and working or reaching at or above shoulder level. There is radiating pain from the neck into his shoulders and his head and

████████████████████  
████████████████████  
Page 3 of 10

he has been experiencing frequent headaches. He is experiencing numbness and tingling and burning sensations. The patient has difficulty falling asleep and is often awakened during the night by the neck pain. There is stiffness and restricted range of motion in the head and neck.

Lower Back:

The patient complains of continuous dull aching pain in the lower back, which increases becoming sharp and stabbing. The pain radiates down his buttocks and back of his thighs to the feet. He experiences numbness and tingling in his feet. He states coughing and sneezing aggravate the back pain. The pain increases with activities of standing or walking as well as sitting over 15 minutes as well as activities of kneeling, stooping, squatting, forward bending, ascending and descending stairs, forceful pushing and pulling, lifting and carrying greater than 10-15 pounds, going from a seated position to a standing position and twisting and turning at the torso. He complains of muscle spasms. He complains of pain and difficulty when engaged in intimate relations/sexual activity due to increased pain to his lower back. The patient denies experiencing bladder or bowel problems. He is awakened from sleep as a result of the low back pain. The patient self-restricts by limiting his activities.

Right Ankle:

He experiences continuous pain the ankle and foot. The pain is aggravated with cold weather, walking on uneven ground, standing or walking over 20-30 minutes, squatting, flexing or extending the foot, kneeling, stooping, and standing on the tip toes. There is radiating pain from the ankle into the toes. There is numbness and tingling in the foot and toes. The patient walks with a slight limp when the pain increases. There is swelling and weakness of the ankle. He uses crutches to get around.

MEDICAL HISTORY:

The patient has no known history of heart disease, high blood pressure, kidney disease, diabetes, tuberculosis, cancer, ulcers, pneumonia, lung disease, eye problems, skin problems, asthma, hepatitis, liver disease, thyroid disease, gout, rheumatoid arthritis, Lupus, or arthritis.

SURGERIES:

The patient denies any surgeries or hospitalizations.

INJURIES:

The patient denies any previous accidents or injuries.

MEDICATIONS:

The patient is currently taking (pt to bring in to appt)

ALLERGIES:

The patient does not have any known allergies.

SOCIAL HISTORY:

The patient is ██████████ and has ██████████ children. He does not drink and does not smoke.

FAMILY HISTORY:

Noncontributory.

**HOBBIES:**

The patient does not have any hobbies.

**ACTIVITIES OF DAILY LIVING:**

The patient states prior to the above noted injury he had no disabling conditions and could perform all activities of daily living without any difficulties.

The patient has pain when performing activities of daily living such as getting dressed, arising from a chair or bed, going from a seated position to a standing and position, driving, walking on uneven surfaces or slanted surfaces, stooping or squatting to pick up objects, she cannot jump, hop, kneel or run, he experiences pain with bathing and washing his feet, dressing and putting on pants, socks or shoes, tying shoes, loading and unloading laundry, folding laundry, cooking and preparing meals, grocery shopping, getting in and out of the car, reaching up to a high shelves, taking out the trash, doing house or yard work and driving for long periods of time.

**PHYSICAL EXAMINATION:**

**Cervical Spine Examination:**

On visual inspection, there is no erythema, edema, swelling or deformity about the cervical spine or upper back area. The patient's head is held in a normal position. No torticollis was noted.

There is no spasm and tenderness over the paravertebral musculature, upper trapezium, interscapular area, cervical spinous processes, or occiput.

Cervical Range of Motion	Patient ROM	Normal
Forward Flex	---	50°
Extension	---	60°
Lateral Flex (rt.)	---	45°
Lateral Flex (lt.)	---	45°
Rotation (rt.)	---	80°
Rotation (lt.)	---	80°

**Electronic inclinometers were used for the formal ranges of motion studies. Please see attached which was used for this evaluation.**

Range of motion was accomplished with no discomfort and spasm.

Reflexes and special tests are as follows:

Reflexes and test	Right	Left	Normal
Tricep reflex	2+	2+	2+
Biceps reflex	2+	2+	2+

Brachioradialis reflex	2+	2+	2+
Tinel Signs (wrists)	Negative	Negative	Negative
Tinel signs (elbow)	Negative	Negative	Negative
Adson Test	Negative	Negative	Negative

Motor power testing for the cervical spine:

Muscle Group	Right	Left	Normal
Deltoid (C5)	5	5	5
Biceps (C6)	5	5	5
Triceps (C7)	5	5	5
Wrists Extensors (C6)	5	5	5
Wrist Flexors (C7)	5	5	5
Finger Flexors (C8)	5	5	5
Finger Abduction (T1)	5	5	5

Sensory Testing:

Dermatome	Right	Left	Normal
C5 (Deltoid)	Intact	Intact	Intact
C6 (Lat Forearm, Thumb, Index)	Intact	Intact	Intact
C7 (Middle Finger)	Intact	Intact	Intact
C8 (Little finger, Med. Forearm)	Intact	Intact	Intact
T1 (Medial Arm)	Intact	Intact	Intact
T2 (Medial Arm)	Intact	Intact	Intact

JAMAR Grip Testing

Right  
32-30-30

Left  
22-22-24

Lumbar Examination:

Patient has a normal gait and is ambulating with no assistive device. On visual inspection, there is no deformity, defect, or swelling about the dorsolumbar spine. No scar or incision was noted. There is no evidence of deformity such as scoliosis or kyphosis.

There is no tenderness and spasm in the paravertebral muscle, the spinous processes and the flank. The sciatic notch area was not tender. **The patient toe and heel walks with right ankle pain. The patient squats with right ankle pain.**

Lumbar Range of Motion	ROM	Normal	Spasm	Pain
Forward Flex	---	60° finger to ankle	Not present	Not present
Extension	---	25°	Not present	Not present
Lateral Flex (rt.)	---	25°	Not present	Not present
Lateral Flex (lt.)	---	25°	Not present	Not present



Rotation (rt.)	---	25°	Not present	Not present
Rotation (lt.)	---	25°	Not present	Not present

Electronic inclinometers were used for the formal ranges of motion studies. Please see attached which was used for this evaluation.

Supine straight leg raising: Right 90, Left 90 with no back pain. Sitting straight leg rising was similar. Lasegue test was negative bilaterally.

Motor Function	Right	Left	Normal
Ankle Dorsiflex L4	4	5	5
Great Toe Ext L5	5	5	5
Ankle Planar Flex S1	4	5	5
Knee Ext L4, L5	5	5	5
Knee Flexion	5	5	5
Hip Abductors	5	5	5
Hip Adductors	5	5	5

Deep tendon reflexes are equal at the knee and ankle joints.

Sensory Function	Right	Left	Normal
L3 Anterior Thigh	Intact	Intact	Intact
L4 Medial Leg, Inner Foot	Intact	Intact	Intact
L5 Lateral Leg, Mid Foot	Intact	Intact	Intact
S1 Post. Leg, Outer Foot	Intact	Intact	Intact

**Ankle Examination:**

Ankle Range of Motion	Right	Left	Normal
Dorsiflexion	---	---	30°
Plantarflexion	---	---	60°
Inversion	---	---	35°
Eversion	---	---	15°

Electronic inclinometers were used for the formal ranges of motion studies. Please see attached which was used for this evaluation.

No tenderness was palpable over medial or lateral malleolus. No tenderness was palpable over the Anterior Talofibular ligament (ATFL), or the peroneal tendons. On visual inspection, there is an incision about the right ankle, but no erythema, ecchymosis, deformity or defect about the ankle. There was no medial or lateral instability and the anterior drawer test was normal. Inversion and Eversion strength were both 4/5 on the right side.

**Foot Examination:**

On visual inspection, there is no erythema, ecchymosis, incision, deformity or defect about the Foot. Ranges of motion of the toes are within normal limits. No tenderness was noted over the plantar fascia. Tinel sign was negative over the tarsal tunnel. Sensation was intact over the foot. Metatarsal head compression was negative for Morton's neuroma.

**REVIEW OF DIAGNOSTIC STUDIES:**

The patient has had x-rays of the right ankle that demonstrates hardware in satisfactory position. Most recent x-rays that were performed on [REDACTED], demonstrated healed fractures.

**IMPRESSION:**

A [REDACTED]-year-old gentleman with right bimalleolar ankle fracture status post ORIF as well as cervical and lumbar sprain/strains.

**DISCUSSION:**

[REDACTED] is a [REDACTED]-year-old gentleman who presented to my office following a work-related injury that occurred on [REDACTED]. The patient was working as a [REDACTED] and [REDACTED] for [REDACTED] on that day. The patient states that he was working inside a truck container when a co-worker was trying to operate the electric pallet jack lost control of the jack which then ran over his feet and pushed him against the wall with a container. The patient had an immediate onset of right ankle pain at that time. He also experienced neck pain and back pain. He eventually underwent ankle surgery by Dr. [REDACTED] on [REDACTED]. The patient underwent postoperative physical therapy. He also underwent physical therapy for the cervical spine and lumbar spine. He is now improved. He is at maximum medical improvement and is considered permanent and stationary.

**CAUSATION:**

Within reasonable medical probability, the patient sustained a right ankle fracture as well as the cervical and lumbar sprain/strains while working for [REDACTED] on [REDACTED]. These injuries arose out of employment and occurred during the course of his employment with the [REDACTED].

**WORK RESTRICTIONS:**

At this point, I am not going to place any work restrictions. The patient may continue to perform his usual and customary duties without restriction. Job modification is not necessary at this time.

**APPORTIONMENT:**

I do not believe that there is any reason for apportionment in this case. I believe a 100% of the patient's pathology in the cervical spine, lumbar spine, and right ankle were secondary to the injury that occurred on [REDACTED] while he was working for [REDACTED].

**AMA IMPAIRMENT RATING:**

For the right ankle, the patient sustained a fracture for which he underwent open reduction internal fixation. He describes residual pain with weakness. I do not believe that using the loss of range of motion to calculate the patient's impairment rating provides an accurate and adequate assessment for the patient's impairment rating. I am using the Almaraz Guzman II case and I am remaining within the four corners of the AMA Guides 5th Edition. I am using the loss of motor function to calculate the patient's impairment rating, according to Chapter 17 of the AMA Guides 5th Edition, which is the lower extremity chapter. In using Table 17-7 and 17-8 of the AMA Guides 5th Edition, the patient is placed in grade four muscle function which is active movement against gravity with some resistance. In using Table 17-8, right ankle flexion with grade four muscle function results in 3% impairment, extension results in 2% impairment, eversion results in 2% impairment and inversion results in 2% impairment. In total the patient is provided with 9% whole person impairment for the right ankle.

**FUTURE MEDICAL:**

I do not believe that the patient requires future medical for the cervical spine and lumbar spine.

For the right ankle, the patient may very well require nonsteroidal antiinflammatories and other pain medication. The patient should have access to follow up visits with an orthopedic surgeon. Short courses of physical therapy may be required for exacerbations. I would not rule out the possibility of having an additional surgery for removal of hardware if these orthopedic implants become painful.

I hope the above information has been helpful to you and thank you for referring this patient to my office for orthopedic examination.

*To complete this examination I have been assisted, as needed, for taking histories, taking x-rays, assisting with the patient, transcription of reports by some or all of the following personnel: [REDACTED]. If required an interpreter was provided. All of the above individuals are qualified to perform the described activities by reason of individual training or under my direct supervision. I certify that this examiner reviewed the history and the past medical records directly with the patient. The examination of the patient, and interpretation of tests and x-rays, was all performed by this examiner. The dictation and the review of the final report were performed entirely by me. The opinions and conclusions contained in this report are entirely my own. I declare, under penalty of perjury, that the information contained in this report, and any attachments, is true and correct, and that there has not been a violation in this report of Section 139.3 L.C. to the best of my knowledge and belief, except as to information that I have indicated was received from others. As to that information I declare under penalty of perjury, that I have accurately detailed the information provided me and, unless otherwise noted, I believe it to be true.*

[REDACTED]  
[REDACTED]  
Page 9 of 10

In order to prepare this report and complete the evaluation, time was spent without face to face with the patient. The billings reflect such time spent by the physician with the code 99358. Jonathan Nassos, M.D. Inc. does not accept the Official Medical fee schedule as prime facie evidence to support the reasonableness of charges. Jonathan Nassos, M.D. is a fellow of the American Academy of Orthopedic Surgeons and is board certified, specializing in sports related orthopedic disorders. Under penalty of perjury under the laws of the State of California, services are billed in accordance with our usual and customary fees. Additionally, this medical practice providing treatment to injured worker's experiences extraordinary expenses in the form of mandated paperwork and collection expenses, including the necessity to retain highly-trained personnel to appear before the Workers' compensation appeals board. Based on the level of services provided and overhead expenses for services contained within our geographical area, we bill in accordance with the provisions set-forth in Labor Code Section 5307.1.

[REDACTED]  
Date

[REDACTED]  
Jonathan Nassos M.D.

County where executed: Los Angeles County

JN

**PROOF OF SERVICE  
STATE OF CALIFORNIA**

I am employed in the County of Los Angeles. I am over the age of 18 and not a party to the within action; my business address is:

5651 SEPULVEDA BLVD., SUITE 201, SHERMAN OAKS, CA 91411

On 3/30/2016 served the foregoing document described as:

JONATHAN NASSOS, M.D.  
EVALUATION REPORT

Patient Name: [REDACTED]  
File Number: [REDACTED]  
Claim #:  
DOS: [REDACTED]

On all interested parties in this action by electronic transmission a true copy of this narrative report from 5651 SEPULVEDA BLVD., SUITE 201, SHERMAN OAKS, CA 91411

Addressed as follows:

[REDACTED]

[REDACTED]

Page 10 of 10

[REDACTED]

[REDACTED]

[REDACTED]

[REDACTED]

I declare that I am over the age of 18 years and not a party to this action. I also declare under penalty of perjury that the foregoing is true and correct and that this declaration was executed [REDACTED] at

[REDACTED]



JONATHAN T. NASSOS, M.D.
—ORTHOPAEDIC SURGERY & SPORTS MEDICINE—

Sample #2

Diplomate, American Board of Orthopaedic Surgery

[Redacted]

Fellow, American Academy of Orthopaedic Surgeons

[Redacted]

Member, American Orthopaedic Society for Sports Medicine

Patient Name : [Redacted]
Date of Service : [Redacted]

Member, Arthroscopy Assoc. of North America

Claim # : [Redacted]
Employer : [Redacted]
Date of Birth : [Redacted]
Date of Injury : [Redacted]

File # : [Redacted]

PERMANENT AND STATIONARY REPORT

HISTORY OF INJURY:

[Redacted] is a [Redacted]-year-old, right-handed female who sustained an industrial injury while performing her usual and customary duties while working for [Redacted] as a [Redacted].

The patient states on [Redacted] during the course of her employment, she sustained an injury to her right leg after she slipped on some chemicals that were on the floor. She felt a burning pain when her leg came in contact with the chemicals as she fell, landing in a seated position. She also noted pain in her low back. She was assisted up by co-workers. She notified her manager who advised her to purchase some cream for her burn. She went home and rested. She returned to work the following day, self-modifying her work duties. She was never offered or provided with any medical care.

In [Redacted] the patient began to experience a gradual onset of pain in her right shoulder, right elbow and right wrist due to the repetitive nature of her work duties. She was continuously pushing, pulling, gripping, grasping, performing above-shoulder reaching and lifting. She notified her employer, however, no medical treatment was provided. She was provided with assistance by another co-worker. She continued working up until [Redacted], at which time she was terminated.

5651 SEPULVEDA BLVD., STE 201
SHERMAN OAKS, CA 91411
PH: (818) 788-2400
FX: (818) 788-2453

9033 WILSHIRE BLVD., STE 401
BEVERLY HILLS, CA 90211
PH: (310) 273-2731
FX: (310) 273-2704

724 CORPORATE CENTER DRIVE
SECOND FLOOR
POMONA, CA 91768
PH: (909) 622-6222
FX: (909) 622-6220

[REDACTED]  
[REDACTED]  
Page 2 of 12

On [REDACTED] the patient was examined by Dr. Johnson. She was placed on temporary totally disabled. She was examined and x-rays were obtained. She was provided with medication. She underwent physical therapy modalities and acupuncture to all the injured body parts intermittently through early summer [REDACTED]. She had only temporary relief. She underwent MRI scans of the right shoulder, right elbow, right wrist/hand and the lumbar spine and EMG studies of the upper and lower extremities. She was referred for a psychological evaluation. She was last examined in [REDACTED].

In [REDACTED] underwent surgery to her right shoulder, by [REDACTED], followed by several months of physical therapy. She states the pain is better but did not subside and has ongoing stiffness and locking of her right shoulder.

In [REDACTED], she was examined by Dr. Kohan for a pain management physician, Dr. Kohan. She was administered a series of lumbar epidurals, providing her temporary pain relief. She is no longer under his medical care.

In early [REDACTED] she was examined by an orthopedic surgeon for an AME evaluation. She does not know the outcome of this evaluation.

She remains off work.

She presents to my office today for a comprehensive orthopedic evaluation.

**CURRENT WORK STATUS:**

The patient is currently not working and is on temporary total disability status. She has not worked since [REDACTED].

She is not receiving any disability.

**JOB DESCRIPTION:**

The patient began employment with [REDACTED], in [REDACTED] as a [REDACTED].

She worked eight hours per day, five to six days per week. Her job duties at the time of injury included: assembling metal and wooden frames for pictures.

The precise activities required entailed prolonged standing in a fixed position, as well as constant fine maneuvering of her hands and fingers, and some bending, stooping, twisting, turning, forceful pushing and pulling, forceful gripping and grasping, reaching, torquing, and lifting 50 pounds.

**PRESENT COMPLAINTS:**

**Right Shoulder:**

The patient has complaints of constant aching in the right shoulder, at times becoming sharp and throbbing pain. Her pain travels to her arm. She has a clicking and grinding sensation in the

right shoulder. She has episodes of numbness and tingling in her right shoulder/arm. She complains of stiffness to her right shoulder. Her pain increases with reaching, pushing, pulling, and with any lifting. Her pain level varies throughout the day depending on activities. She has difficulty sleeping and awakens with pain and discomfort. Pain medication provides her temporary pain relief.

Right Elbow:

The patient has complaints of continuous aching in the right elbow, associated with swelling. Her pain becomes sharp and shooting with activity. Her pain travels to her forearm. She has episodes of numbness and tingling in her right elbow and arm. She complains of stiffness to her right elbow. Her pain increases with reaching, pushing, pulling, and with any lifting. Her pain level varies throughout the day depending on activities. She has difficulty sleeping and awakens with pain and discomfort. Pain medication provides her temporary pain relief.

Right Hand/Wrist:

The patient has complaints of constant aching in the right wrist/hand pain, often becoming sharp, shooting, and burning pain. Her pain travels to her forearm. She has numbness and tingling in her right hand. She complains of cramping and weakness in her right hand. Her pain increases with gripping, grasping, and repetitive hand and finger movements. She has difficulty sleeping and awakens with pain and discomfort. Her pain level varies throughout the day depending on activities. Pain medication provides her temporary pain relief.

Lower Back:

The patient has complaints of constant nagging pain in the lower back, at times becoming sharp, shooting, throbbing, and burning pain. Her pain travels to her legs and feet. She has episodes of swelling, numbness, and tingling in her legs and feet. Her pain increases with prolonged standing, walking, and sitting. She also has difficulty sleeping and awakens with pain and discomfort. Her pain level varies throughout the day depending on activities. She does not have bowel or bladder dysfunction. Pain medication provides her temporary pain relief.

PAST MEDICAL HISTORY

The patient denies medical illnesses including cardiovascular disease, hypertension, renal or hepatic disease, diabetes mellitus, tuberculosis, cancer, ulcers, pneumonia, pulmonary or thyroid disease, skin problems, asthma, gout, rheumatoid arthritis, lupus or any type of bone, muscle or joint disease.

SURGERIES/HOSPITALIZATIONS:

The patient underwent right shoulder surgery in [REDACTED]

PREVIOUS ACCIDENTS/INJURIES:

The patient was involved in a motor vehicle accident in [REDACTED]. She sustained an injury to her cervical spine. She treated conservatively. She fully recovered and had no residual complaints.



**CURRENT MEDICATIONS:**

The patient is currently taking prescribed pain medication and anti-inflammatory agents, but cannot recall the names of these.

**ALLERGIES:**

The patient denies any known medication allergies.

**SOCIAL HISTORY:**

The patient is [redacted] with [redacted]

The patient denies tobacco use and the consumption of alcoholic beverages.

**FAMILY HISTORY:**

The patient's family history is noncontributory.

**PHYSICAL EXAMINATION:**

**Cervical Spine Examination:**

On visual inspection, there is no erythema, edema, swelling or deformity about the cervical spine or upper back area. The patient's head is held in a normal position. No torticollis was noted.

**There is tenderness over the paravertebral musculature, upper trapezium, but not over the interscapular area, cervical spinous processes, or occiput.**

Cervical Range of Motion	Patient ROM	Normal
Forward Flex	---	50°
Extension	---	60°
Lateral Flex (rt.)	---	45°
Lateral Flex (lt.)	---	45°
Rotation (rt.)	---	80°
Rotation (lt.)	---	80°

**Electronic inclinometers were used for the formal ranges of motion studies. Please see attached which was used for this evaluation.**

Range of motion was accomplished with no discomfort and spasm.

Reflexes and special tests are as follows:

Reflexes and test	Right	Left	Normal
Tricep reflex	2+	2+	2+
Biceps reflex	2+	2+	2+
Brachioradialis reflex	2+	2+	2+
Tinel Signs (wrists)	Negative	Negative	Negative

Tinel signs (elbow)	Negative	Negative	Negative
Adson Test	Negative	Negative	Negative

Motor power testing for the cervical spine:

Muscle Group	Right	Left	Normal
Deltoid (C5)	5	5	5
Biceps (C6)	5	5	5
Triceps (C7)	5	5	5
Wrists Extensors (C6)	5	5	5
Wrist Flexors (C7)	5	5	5
Finger Flexors (C8)	5	5	5
Finger Abduction (T1)	5	5	5

Sensory Testing:

Dermatome	Right	Left	Normal
C5 (Deltoid)	Intact	Intact	Intact
C6 (Lat Forearm, Thumb, Index)	Intact	Intact	Intact
C7 (Middle Finger)	Intact	Intact	Intact
C8 (Little finger, Med. Forearm)	Intact	Intact	Intact
T1 (Medial Arm)	Intact	Intact	Intact
T2 (Medial Arm)	Intact	Intact	Intact

JAMAR Grip Testing

Right  
12-10-10

Left  
18-14-18

Shoulder Examination:

Shoulder Range of Motion	Right	Left	Normal
Flexion	---	---	180°
Abduction	---	---	180°
Extension	---	---	50°
Ext Rotation	---	---	90°
Ext Internal Rotation	---	---	90°
Adduction	---	---	50°

Electronic inclinometers were used for the formal ranges of motion studies. Please see attached which was used for this evaluation.

No tenderness was noted at the anterior deltoid, supraspinatus insertion, biceps tendon, or the acromioclavicular joint.

Impingement and Hawkins signs were negative on the right and left. Jobe's sign was negative on the right and left.

Apprehension test and re-location test were negative. No sulcus was present. Yergason test was negative bilaterally. No deformity was noted around the shoulder area. Incision was noted on the right.

**Elbow Examination:**

Elbow Range of Motion	Right	Left	Normal
Flexion	---	---	140°
Extension	---	---	0°
Pronation	---	---	80°
Supination	---	---	80°

No tenderness was noted over the lateral (tennis) or medial (Golfers) epicondyles. Resisted wrist extension did not elicit tenderness over the lateral epicondyle. The lateral pivot shift test did not reproduce instability. No olecranon bursitis was noted.

**Wrist & Hands Examination:**

Wrist Range of Motion	Right	Left	Normal
Flexion	---	---	60°
Extension	---	---	60°
Ulnar Deviation	---	---	30°
Radial Deviation	---	---	20°

No mechanical block was noted to range of motion. There was no tenderness over the distal radius or the carpus. No tenderness was noted at the anatomic snuffbox or the TFCC. Finkelstein test was normal. Tinel testing was negative. Phalen testing was negative.

No atrophy or tenderness was noted in the thenar, hypothenar, and intrinsic hand musculatures. The radial pulses are present and equal bilaterally.

**Lumbar Examination:**

Patient has a normal gait and is ambulating with no assistive device. On visual inspection, there is no deformity, defect, or swelling about the dorsolumbar spine. No scar or incision was noted. There is no evidence of deformity such as scoliosis or kyphosis.

There is tenderness and spasm in the paravertebral muscle, but not the spinous processes and the flank. The sciatic notch area was not tender. The patient toe and heel walks with pain. The patient squats with pain.

Lumbar Range of Motion	ROM	Normal	Spasm	Pain
Forward Flex	---	60° finger to ankle	Present	Present
Extension	---	25°	Present	Present
Lateral Flex (rt.)	---	25°	Present	Present
Lateral Flex (lt.)	---	25°	Present	Present
Rotation (rt.)	---	25°	Present	Present
Rotation (lt.)	---	25°	Present	Present

Electronic inclinometers were used for the formal ranges of motion studies. Please see attached which was used for this evaluation.

Supine straight leg raising: Right 90, Left 90 with lumbar spine pain. Sitting straight leg rising was similar. Lasegue test was negative bilaterally.

Motor Function	Right	Left	Normal
Ankle Dorsiflex L4	5	5	5
Great Toe Ext L5	5	5	5
Ankle Planar Flex S1	5	5	5
Knee Ext L4, L5	5	5	5
Knee Flexion	5	5	5
Hip Abductors	5	5	5
Hip Adductors	5	5	5

Deep tendon reflexes are equal at the knee and ankle joints. Palpation over the sacroiliac joint did not elicit tenderness. The FABER (Patrick's) test was negative bilaterally.

Sensory Function	Right	Left	Normal
L3 Anterior Thigh	Intact	Intact	Intact
L4 Medial Leg, Inner Foot	Intact	Intact	Intact
L5 Lateral Leg, Mid Foot	Intact	Intact	Intact
S1 Post. Leg, Outer Foot	Intact	Intact	Intact

**DIAGNOSES:**

- Lumbar spine radiculopathy.
- Left shoulder subacromial impingement status post arthroscopy.
- Right elbow lateral epicondylitis.
- Right wrist tendonitis.

**DIAGNOSTIC STUDIES:**

I have been able to review an MRI of the lumbar spine from [REDACTED]. There is 2 mm disc bulge at L3-L4 with compression of bilateral L4 transiting nerve roots. There is a 3 mm disc bulge seen at L4-L5 with compression of bilateral L5 nerve roots and encroachment on the left L4 exiting nerve root. There is a 3 mm disc bulge seen at L5-S1 effacing the bilateral S1 transiting nerve roots. Disc desiccation is noted over multiple levels.

I have been able to review the Functional Capacity Evaluation from [REDACTED]. This reports states physical demand lift 20 pounds, carry 20 pounds. The patient has slight restrictions in sitting, standing, and walking with moderate restrictions with lifting, carrying, crouching, squatting, kneeling, crawling, stair climbing, slight restrictions in bending of the neck and twisting of the neck, she is able to perform.

**DISCUSSION:**

This is a [REDACTED]-year-old woman who sustained industrial injuries as a result of continuous trauma from [REDACTED] to [REDACTED] while working as a [REDACTED] with [REDACTED]. The patient also sustained a specific injury on [REDACTED]. The patient reports that on [REDACTED], she injured her right leg as she slipped on some chemical that were on the floor. She felt burning pain in her right leg when the right leg came in contact with chemical. She fell landing on a seated position. She also noted back pain at that time. In [REDACTED], the patient also began to experience a gradual onset of right shoulder pain, right elbow pain, right wrist pain due to the repetitive nature of her duties which includes continuously pushing, pulling, gripping, grasping, performing above shoulder reaching and lifting. She did notify her employer but no medical treatment was provided. She continued to work up until [REDACTED] at which time she was terminated. In [REDACTED] she underwent right shoulder surgery. The patient was also administered a series of lumbar epidural steroid injections. This provided temporary pain relief for the patient.

The patient has undergone conservative management with regards to the lumbar spine. Without any type of surgical intervention, the patient would be considered at maximum medical improvement at this time.

The following are permanent work restrictions.

**WORK RESTRICTIONS:**

Lumbar Spine: The patient is precluded from repetitive bending and twisting of the lumbar spine

Left Shoulder: The patient is precluded from activities at or above the shoulder level.

Right Elbow: The patient is precluded from repetitive torquing.

Right Wrist: The patient is precluded from repetitive power gripping, repetitive grasping and repetitive pinching.

**APPORTIONMENT:**

There is no indication to apportion to prior disability. Labor Code 4663 mandates to apportion to causation and the Escobedo vs. Marshall's case indicates to apportion to pathology. I do not believe that there is any evidence that the patient had preexisting disability, impairment, or pathology. As such, 100% of the patient's disability and impairment is related to the direct effect of the industrial injuries.

**FUTURE MEDICAL CARE:**

I do believe the patient should have access to orthopedic reevaluations, medications, physiotherapy, durable medical goods, and possible surgical intervention to the lumbar spine. Up to 24 sessions of physical therapy year around may be required.

For the right shoulder, I do not believe she would require anymore than short courses of physical therapy, nonsteroidal antiinflammatories, and possible injections.

For the right elbow, she may require injections, nonsteroidal antiinflammatories, physical therapy, and potentially surgical intervention.

Conservative care for the right wrist would be indicated including durable medical equipment, nonsteroidal antiinflammatories.

**VOCATIONAL REHABILITATION:**

The patient is a QIW and cannot return to her previous work activities.

**AMA IMPAIRMENT RATING:**

In regards to the lumbar spine, the MRI was reviewed. The patient describes pain with stiffness in her lower back. There is spasm, tenderness and guarding noted in the paravertebral muscles of the lumbar spine with decreased range of motion. Based on the above, I am using the DRE method to calculate the patient's impairment rating, according to pages 381-384 of the AMA Guides 5th Edition. In using Table 15-3 on page 384, the patient is placed in DRE lumbar category II and 5% whole person impairment is provided.

In regards to the left shoulder, right elbow and right wrist, I am using the loss of range of motion to calculate the patient's impairment rating. Formal range of motion studies were performed using double electronic inclinometers and the report is attached. Left shoulder flexion is degrees, extension is degrees, internal rotation is degrees, external rotation is degrees, abduction is degrees and adduction is degrees. This results in % of the left upper extremity and in order to convert to whole person impairment, you must multiply by a factor of 0.6, resulting in % whole person impairment.

For the right elbow flexion is 75 degrees, supination is 79 degrees, and pronation is 81 degrees. This results in 12% for the right elbow. For the right wrist, flexion is 63 degrees, extension is 60 degrees, radial deviation is 13 degrees and ulnar deviation is 20 degrees. This results in 3% impairment for the right wrist. The total right upper extremity impairment results in 15% and in order to convert to whole person impairment, you must multiply by a factor of 0.6, resulting in 9% whole person impairment.

In using the Combined Values Chart on page 604 of the AMA Guides 5th Edition, the patient is provided with a total of % whole person impairment.

**CAUSATION:**

Within reasonable medical probability, the patient did sustain industrial injury to the right shoulder, elbow, and wrist as well as the lumbar spine. These injuries arose out of employment and occurred during the course of her employment with [REDACTED]

I hope the above information has been helpful to you and thank you for referring this patient to my office for orthopedic examination.

*To complete this examination I have been assisted, as needed, for taking histories, taking x-rays, assisting with the patient, transcription of reports by some or all of the following personnel [REDACTED] If required an interpreter was provided. All of the above individuals are qualified to perform the described activities by reason of individual training or under my direct supervision. I certify that this examiner reviewed the history and the past medical records directly with the patient. The examination of the patient, and interpretation of tests and x-rays, was all performed by this examiner. The dictation and the review of the final report were performed entirely by me. The opinions and conclusions contained in this report are entirely my own. I declare, under penalty of perjury, that the information contained in this report, and any attachments, is true and correct, and that there has not been a violation in this report of Section 139.3 L.C. to the best of my knowledge and belief, except as to information that I have indicated was received from others. As to that information I declare under penalty of perjury, that I have accurately detailed the information provided me and, unless otherwise noted, I believe it to be true.*

*In order to prepare this report and complete the evaluation, time was spent without face to face with the patient. The billings reflect such time spent by the physician with the code 99358. Jonathan Nassos, M.D. Inc. does not accept the Official Medical fee schedule as prime facie evidence to support the reasonableness of charges. Jonathan Nassos, M.D. is a fellow of the American Academy of Orthopedic Surgeons and is board certified, specializing in sports related orthopedic disorders. Under penalty of perjury under the laws of the State of California, services are billed in accordance with our usual and customary fees. Additionally, this medical practice providing treatment to injured worker's experiences extraordinary expenses in the form of mandated paperwork and collection expenses, including the necessity to retain highly-trained personnel to appear before the Workers' compensation appeals board. Based on the level of*

[REDACTED]  
[REDACTED]  
Page 11 of 12

*services provided and overhead expenses for services contained within our geographical area, we bill in accordance with the provisions set-forth in Labor Code Section 5307.1.*

[REDACTED]  
Date

[REDACTED]  
Jonathan Nassos M.D.

County where executed: [REDACTED]

JN/11099/

cc: [REDACTED]  
[REDACTED]  
[REDACTED]  
[REDACTED]  
[REDACTED]  
[REDACTED]  
[REDACTED]  
[REDACTED]

**PROOF OF SERVICE**  
**STATE OF CALIFORNIA**

I am employed in the County of Los Angeles. I am over the age of 18 and not a party to the within action; my business address is:

5651 SEPULVEDA BLVD., SUITE 201, SHERMAN OAKS, CA 91411

On [REDACTED] served the foregoing document described as:

JONATHAN NASSOS, M.D.  
EVALUATION REPORT

Patient Name: [REDACTED]

File Number: [REDACTED]

Claim #: [REDACTED]  
[REDACTED]

On all interested parties in this action by electronic transmission a true copy of this narrative report from 5651 SEPULVEDA BLVD., SUITE 201, SHERMAN OAKS, CA 91411

Addressed as follows:



[REDACTED]  
[REDACTED]  
Page 12 of 12

[REDACTED]  
[REDACTED]  
[REDACTED]  
[REDACTED]

[REDACTED]  
[REDACTED]  
[REDACTED]  
[REDACTED]

[REDACTED]  
[REDACTED]  
[REDACTED]  
[REDACTED]

I declare that I am over the age of 18 years and not a party to this action. I also declare under penalty of perjury that the foregoing is true and correct and that this declaration was executed on [REDACTED]

[REDACTED]  
[REDACTED]  
[REDACTED]  
[REDACTED]

June 24, 2016

TO: Each Member  
Board of Retirement

FROM: Ricki Contreras, Division Manager  
Disability Retirement Services



FOR: July 6, 2016 Board of Retirement Meeting

**SUBJECT: Application Processing Time Snapshot Reports**

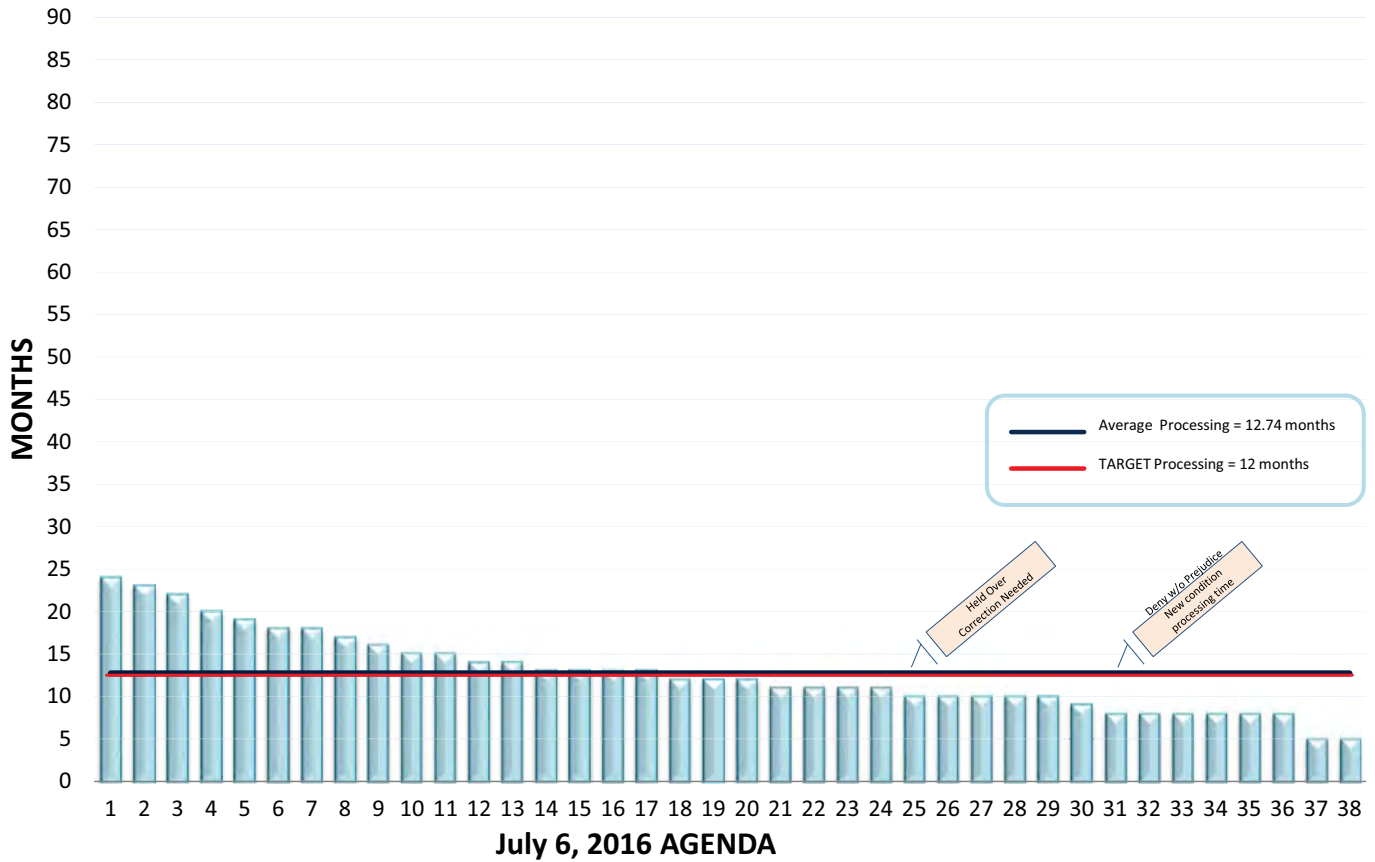
At the February 4, 2015 meeting, the Disability Procedures & Services Committee voted to add two additional snapshot reports addressing application processing times and pending applications by elapsed time since application date. These reports will now be provided on a monthly basis along with the current snapshot that provides a look at application processing time before and after procedural changes were made to the disability application process. The Board adopted proposed changes on July 12, 2012.

**Note:** All applications submitted prior to July 12, 2012 have been processed.

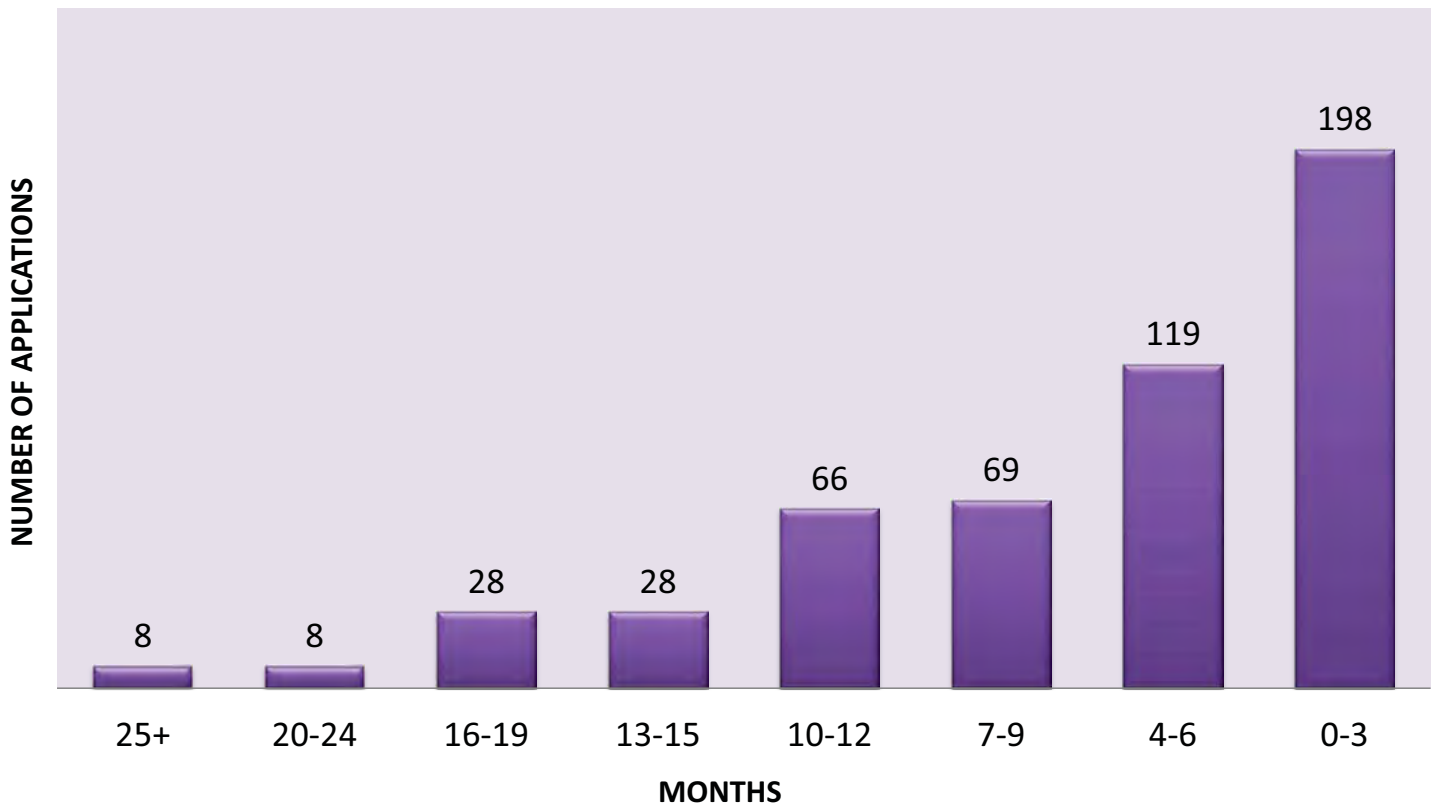
The following chart shows the total processing time from receipt of the application to the first Board action for all cases on the July 6, 2016 Disability Retirement Applications Agenda.

<b>Consent &amp; Non-Consent Calendar</b>		
<b>Number of Applications</b>	36	
<b>Average Processing Time (in Months)</b>	12.94	
<b>Revised/Held Over Calendar</b>		
<b>Number of Applications</b>	2	
<b>Average Processing Time (in Months)</b>	Case 1 10	Case 2 8
<b>Total Average Processing Time for Revised/Held Over Calendar</b>	9	

## ACTUAL vs. AVERAGE PROCESSING TIME



## TIME ELAPSED FOR PENDING APPLICATIONS





---

**Documents not attached are exempt from disclosure under the California Public Records Act and other legal authority.**

**For further information, contact:  
LACERA  
Attention: Public Records Act Requests  
300 N. Lake Ave., Suite 620  
Pasadena, CA 91101**



---

**Documents not attached are exempt from disclosure under the California Public Records Act and other legal authority.**

**For further information, contact:  
LACERA  
Attention: Public Records Act Requests  
300 N. Lake Ave., Suite 620  
Pasadena, CA 91101**



---

**Documents not attached are exempt from disclosure under the California Public Records Act and other legal authority.**

**For further information, contact:  
LACERA  
Attention: Public Records Act Requests  
300 N. Lake Ave., Suite 620  
Pasadena, CA 91101**



---

**Documents not attached are exempt from disclosure under the California Public Records Act and other legal authority.**

**For further information, contact:  
LACERA  
Attention: Public Records Act Requests  
300 N. Lake Ave., Suite 620  
Pasadena, CA 91101**