

AGENDA

A REGULAR MEETING OF THE BOARD OF RETIREMENT

LOS ANGELES COUNTY EMPLOYEES RETIREMENT ASSOCIATION

300 N. LAKE AVENUE, SUITE 810, PASADENA, CA

9:00 A.M., WEDNESDAY, OCTOBER 5, 2016

*The Board may take action on any item on the agenda,
and agenda items may be taken out of order.*

- I. CALL TO ORDER
- II. PLEDGE OF ALLEGIANCE
- III. APPROVAL OF MINUTES
 - A. Approval of the Minutes of the Regular Meeting of September 7, 2016
- IV. REPORT ON CLOSED SESSION ITEMS
- V. PUBLIC COMMENT
- VI. CONSENT AGENDA
 - A. Ratification of Service Retirement and Survivor Benefit Application Approvals.
 - B. Requests for an administrative hearing before a referee.
(Memo dated September 21, 2016)
 - C. Recommendation as submitted by Vivian H. Gray, Chair, Disability Procedures & Services Committee: That the Board approve Richard C. Rosenberg, M.D. – Board Certified Orthopedist to the LACERA Panel of Physicians for the purpose of examining disability retirement applicants. (Memo dated September 20, 2016)

VI. CONSENT AGENDA (Continued)

- D. Recommendation as submitted by Vivian H. Gray, Chair, Disability Procedures & Services Committee: That the Board approve Michael M. Bronshvag, M.D. – Board Certified Internist/Neurologist to the LACERA Panel of Physicians for the purpose of examining disability retirement applicants. (Memo dated September 20, 2016)
- E. For Information Only as submitted by Ricki Contreras, Division Manager, Disability Retirement Services, regarding the Application Processing Time Snapshot Reports. (Memo dated September 23, 2016)

VII. REPORT ON STAFF ACTION ITEMS

VIII. GOOD OF THE ORDER
(For information purposes only)

IX. DISABILITY RETIREMENT APPLICATIONS ON CONSENT CALENDAR

X. DISABILITY RETIREMENT CASES TO BE HELD IN CLOSED SESSION

- A. Applications for Disability
- B. Referee Reports
- C. Staff Recommendations

- 1. Recommendation as submitted by Ricki Contreras, Division Manager, Disability Retirement Services: That the Board adopt the Proposed Findings of Fact and Conclusions of Law granting **Sergio J. Hernandez** for a service-connected disability retirement pursuant to Government Code Section 31720. (Memo dated September 21, 2016)

X. DISABILITY RETIREMENT CASES TO BE HELD IN CLOSED SESSION

C. Staff Recommendations (Continued)

2. Recommendation as submitted by Jason E. Waller, Senior Staff Counsel, Disability Litigation: That the Board grant **Andrea M. Jackson** the option of choosing an earlier effective date for the commencement of her disability retirement in accordance with Government Code Section 31724. (Letter dated September 7, 2016)

XI. EXECUTIVE SESSION

A. Conference with Legal Counsel - Existing Litigation
(Pursuant to Paragraph (1) of Subdivision (d) of California Government Code Section 54956.9)

1. Vernalea Panga v. LACERA
Los Angeles Superior Court, Case No. BS 158634

XII. ADJOURNMENT

Documents subject to public disclosure that relate to an agenda item for an open session of the Board of Retirement that are distributed to members of the Board of Retirement less than 72 hours prior to the meeting will be available for public inspection at the time they are distributed to a majority of the Board of Retirement Members at LACERA's offices at 300 N. Lake Avenue, Suite 820, Pasadena, CA 91101, during normal business hours of 9:00 a.m. to 5:00 p.m. Monday through Friday.

Persons requiring an alternative format of this agenda pursuant to Section 202 of the Americans with Disabilities Act of 1990 may request one by calling Cynthia Guider at (626) 564-6000, from 8:30 a.m. to 5:00 p.m. Monday through Friday, but no later than 48 hours prior to the time the meeting is to commence. Assistive Listening Devices are available upon request. American Sign Language (ASL) Interpreters are available with at least three (3) business days notice before the meeting date.

MINUTES OF THE REGULAR MEETING OF THE BOARD OF RETIREMENT

LOS ANGELES COUNTY EMPLOYEES RETIREMENT ASSOCIATION

300 N. LAKE AVENUE, SUITE 810, PASADENA, CA

9:00 A.M., WEDNESDAY, SEPTEMBER 7, 2016

PRESENT: Shawn R. Kehoe, Chair (Arrived at 9:08 a.m.)

Vivian H. Gray, Vice Chair

William de la Garza, Secretary

Marvin Adams

Anthony Bravo

Yves Chery

Joseph Kelly

Ronald A. Okum

William Pryor (Alternate Member)

Les Robbins

ABSENT: David L. Muir (Alternate Retired)

STAFF ADVISORS AND PARTICIPANTS

Gregg Rademacher, Chief Executive Officer

John Popowich, Assistant Executive Officer

Steven P. Rice, Chief Counsel

STAFF ADVISORS AND PARTICIPANTS (Continued)

Dr. Vito Campese, Medical Advisor

Ricki Contreras, Division Manager
Disability Retirement Services

Tamara Caldwell, Specialist Supervisor
Disability Retirement Services

Francis J. Boyd, Senior Staff Counsel
Legal Division

I. CALL TO ORDER

The meeting was called to order by Vice Chair Gray at 9:08 a.m., in the Board Room of Gateway Plaza.

II. PLEDGE OF ALLEGIANCE

Mr. Robbins led the Board Members and staff in reciting the Pledge of Allegiance.

III. APPROVAL OF MINUTES

A. Approval of the Minutes of the Regular Meeting of August 3, 2016

Mr. Adams made a motion, Mr. Chery seconded, to approve the minutes of the regular meeting of August 3, 2016. The motion passed unanimously.

IV. REPORT ON CLOSED SESSION ITEMS

No items were reported.

V. PUBLIC COMMENT

There were no requests from the public to speak.

VI. CONSENT AGENDA

Mr. Chery made a motion, Mr. Robbins seconded, to approve the following agenda items. The motion passed unanimously.

- A. Ratification of Service Retirement and Survivor Benefit Application Approvals.
- B. Requests for an administrative hearing before a referee.
(Memo dated August 24, 2016)
- C. Recommendation as submitted by Ricki Contreras, Division Manager, Disability Retirement Services: That the Board dismiss with prejudice the appeal for an earlier effective date in the case of **Cynthia A. Bercian**.
(Memo dated August 16, 2016)
- D. Recommendation as submitted by Ricki Contreras, Division Manager, Disability Retirement Services: That the Board dismiss with prejudice the appeal for an earlier effective date in the case of **Pandora Cook**. (Memo dated August 16, 2016)
- E. Recommendation as submitted by Ricki Contreras, Division Manager, Disability Retirement Services: That the Board dismiss with prejudice the appeal for a service-connected disability retirement in the case of **Rhonda J. Castillo**. (Memo dated August 24, 2016)
- F. Recommendation as submitted by Ricki Contreras, Division Manager, Disability Retirement Services: That the Board dismiss with prejudice the appeal for a service-connected disability retirement in the case of **Debra C. Singleton-Ford**. (Memo dated August 18, 2016)
- G. For Information Only as submitted by Ricki Contreras, Division Manager, Disability Retirement Services, regarding the Application Processing Time Snapshot Reports. (Memo dated August 26, 2016)

VII. REPORT ON STAFF ACTION ITEMS

There was nothing to report on for staff action items.

VIII. GOOD OF THE ORDER
(For information purposes only)

Mr. Kelly shared that he has recruited Antoinette Chandler from the San Diego Treasurer and Tax Collector to join his team.

Mr. Rademacher shared that The American Cancer Society will be honoring Board member, Ronald Okum, at its 7th Annual Hope Scores Gala on September 17, 2016.

IX. DISABILITY RETIREMENT APPLICATIONS ON CONSENT CALENDAR

Safety Law Enforcement
Service-Connected Disability Applications

On a motion by Mr. Okum, seconded by Ms. Gray, the Board of Retirement approved a service-connected disability retirement for the following named employees who were found to be disabled for the performance of their duties and have met the burden of proof:

<u>APPLICATION NO.</u>	<u>NAME</u>
519C	JOSEPH C. HAERTSCH
520C	SHAWN W. BROWNELL
521C	MARK S. MONTOYA
522C	BAN V. NGUYEN

IX. DISABILITY RETIREMENT APPLICATIONS ON CONSENT CALENDAR

Safety Law Enforcement (Continued)
Service-Connected Disability Applications

<u>APPLICATION NO.</u>	<u>NAME</u>
523C*	RAYMOND LEYVA
524C	LARRY J. MOSSBERG
525C**	GERALD W. NEWBOLD
526C*	JAMES E. DERUYTER
527C	CARLOS A. GONZALEZ
528C***	MELISSA D. WIRSING
529C****	PAUL M. PUCHALSKI
530C	STEVEN S. DOWNEY
531C*	THOMAS B. LINES
532C*	GREGORY A. ZEMBAL
533C*	STEVE ESPERICUETA
534C	RAYMOND ENRIQUEZ
535C****	DANIEL H. OPPENHEIM

* Granted SCD – Employer Cannot Accommodate

** Granted SCD – Retroactive Since Employer Cannot Accommodate

*** Granted SCD – Salary Supplemental

**** Granted SCD – Retroactive

IX. DISABILITY RETIREMENT APPLICATIONS ON CONSENT CALENDAR

Safety-Fire, Lifeguard
Service-Connected Disability Applications

On a motion by Mr. Chery, seconded by Mr. Adams, the Board of Retirement approved a service-connected disability retirement for the following named employees who were found to be disabled for the performance of their duties and have met the burden of proof:

<u>APPLICATION NO.</u>	<u>NAME</u>
1789A	GABRIEL G. RAMIREZ
1790A	DAVID E. STONE
1791A	GREG L. PFEIFER
1792A	DANNY L. MCGLOTHEN
1793A*	MARK L. WHEELER
1794A	MICHAEL D. JACKSON
1795A	JAMES E. WHEELER

* Granted SCD – Employer Cannot Accommodate

IX. DISABILITY RETIREMENT APPLICATIONS ON CONSENT CALENDAR

General Members

Service-Connected Disability Applications

On a motion by Mr. Chery, seconded by Mr. Okum, the Board of Retirement approved a service-connected disability retirement for the following named employees who were found to be disabled for the performance of their duties and have met the burden of proof:

<u>APPLICATION NO.</u>	<u>NAME</u>
2642B*	CONSUELO HUESCA
2643B**	JEFFREY C. SCHWEITZER
2644B	ARIS MARDIROSIAN
2645B	KIESHA M. HUNTER
2646B**	TONY R. MARTINEZ
2647B*	YVONNE A. LAUREL
2648B	LUPE CALDERON
2649B**	GINGER WELKER

* Granted SCD – Retroactive

** Granted SCD – Employer Cannot Accommodate

IX. DISABILITY RETIREMENT APPLICATIONS ON CONSENT CALENDAR

General Members

Non-Service Connected Disability Applications

On a motion by Mr. de la Garza, seconded by Ms. Gray, the Board of Retirement approved a non-service connected disability retirement for the following named employees who were found to be disabled for the performance of their duties and have met the burden of proof:

APPLICATION NO.

NAME

4347

LAURE L. BROWN

X. DISABILITY RETIREMENT CASES TO BE HELD IN CLOSED SESSION

A. Applications for Disability

APPLICATION NO. & NAME

BOARD ACTION

6904A – GABRIELLE L. LANGFORD

(Mr. Kelly recused himself from discussing this case and returned after this case was heard before the Board.)

Mr. de la Garza made a motion, Mr. Pryor seconded, to grant a non-service connected disability retirement pursuant to Government Code Sections 31720 and 31724. The motion passed unanimously.

6905A – CATHERINE ROGERS

Mr. Okum made a motion, Mr. de la Garza seconded, to deny a service connected disability retirement since the employer can accommodate. The motion passed unanimously.

X. DISABILITY RETIREMENT CASES TO BE HELD IN CLOSED SESSION

A. Applications for Disability (Continued)

<u>APPLICATION NO. & NAME</u>	<u>BOARD ACTION</u>
6906A – LILLIE M. TATUM*	<p>Mr. Okum made a motion, Chair Kehoe seconded, to deny a service connected disability retirement and find the applicant not permanently incapacitated.</p> <p>Ms. Gray made a substitute motion, Mr. Chery seconded, to refer back to staff for additional information. The makers of the motion withdrew their motion.</p> <p>The motion to deny a service connected disability retirement and find the applicant not permanently incapacitated passed unanimously.</p>
6907A – ROBERT L. MINER	<p>Mr. Chery made a motion, Mr. de la Garza seconded, to deny a service connected disability retirement without prejudice. The motion passed unanimously.</p>
6908A – ROBERTO A. GOODEN	<p>This case was pulled at the request of the applicant.</p>
6909A – WANDA R. JAMERSON	<p>Mr. Adams made a motion, Chair Kehoe seconded, to deny a service connected disability retirement and find the applicant not permanently incapacitated. The motion passed unanimously.</p>

*Applicant Present

X. DISABILITY RETIREMENT CASES TO BE HELD IN CLOSED SESSION

A. Applications for Disability (Continued)

<u>APPLICATION NO. & NAME</u>	<u>BOARD ACTION</u>
6626A – AUGUA A. ANDREWS	Mr. de la Garza made a motion, Ms. Gray seconded, to deny a service connected disability retirement and find the applicant not permanently incapacitated. The motion passed unanimously.
6900A – FRANCES H. TEASLEY	Mr. de la Garza made a motion, Mr. Chery seconded, to grant a service connected disability retirement pursuant to Government Code Section 31720. The motion passed unanimously.
6910A – M1508DRSM	Mr. Chery made a motion, Mr. Bravo seconded to grant a service connected disability retirement. The motion passed (roll call) with Messrs. Adams, Bravo, Robbins, Chery, Chair Kehoe, and Ms. Gray voted yes; and Messrs. Kelly, Okum, and de la Garza voting no.

B. Referee Reports

<u>APPLICATION NO. & NAME</u>	<u>BOARD ACTION</u>
GINA L. MCDOWELL – Danny T. Polhamus for the applicant Allison E. Barrett for the respondent	This item was pulled from the agenda by the applicant's attorney.

September 7, 2016

Page 11

Green Folder Information (Information distributed in each Board Member's Green Folder at the beginning of the meeting)

1. Retirement Board Listing dated September 7, 2016
2. Disability Retirement Evaluation Report Correction Memo – James E. Deruyter (Memo dated August 29, 2016)

XI. ADJOURNMENT

There being no further business to come before the Board, the meeting was adjourned at 9:58 a.m.

WILLIAM DE LA GARZA, SECRETARY

SHAWN R. KEHOE, CHAIR



September 21, 2016

TO: Each Member
Board of Retirement

FROM: Ricki Contreras, Division Manager
Disability Retirement Services

SUBJECT: **APPEALS FOR THE BOARD OF RETIREMENT'S MEETING
OF OCTOBER 5, 2016**

IT IS RECOMMENDED that your Board grant the appeals and requests for administrative hearing received from the following applicants, and direct the Disability Retirement Services Manager to refer each case to a referee:

6906A	Lillie M. Tatum	In Pro Per	Deny SCD
6781A	Teresa Sanchez	In Pro Per	Deny SCD Employer Can Accommodate
6905A	Catherine Rogers	Mark Singer	Deny SCD Employer Can Accommodate



September 20, 2016

TO: Each Member
Board of Retirement

FROM: Disability Procedures & Services Committee
Vivian H. Gray, Chair
William de la Garza, Vice Chair
Yves Chery
Les Robbins
David Muir, Alternate

FOR: October 5, 2016 Board of Retirement Meeting

SUBJECT: **CONSIDER APPLICATION(S) FOR LACERA PANEL OF EXAMINING PHYSICIAN(S)**

On September 7, 2016, the Disability Procedures & Services Committee reviewed the attached application for the LACERA Panel of Examining Physicians.

The application package has been reviewed by the Committee. After discussion, the Committee voted to accept the application of the following physician and submit to the Board of Retirement for approval to the LACERA panel.

IT IS THEREFORE RECOMMENDED THAT the Board approve the following physician to the LACERA Panel of Physicians for the purpose of examining disability retirement applicants.


Richard C. Rosenberg, M.D. - Board Certified Orthopedist

Attachments

VG:RC/mb

August 23, 2016

TO: Disability Procedures & Services Committee
Vivian H. Gray, Chair
William de la Garza, Vice Chair
Yves Chery
Les Robbins
David Muir, Alternate

FROM: Ricki Contreras, Manager 
Disability Retirement Services

FOR: September 7, 2016, Disability Procedures and Services Committee Meeting

SUBJECT: **CONSIDER APPLICATION OF ORTHOPEDIST, RICHARD C. ROSENBERG, M.D., TO THE LACERA PANEL OF EXAMINING PHYSICIANS**

On July 26, 2016, Debbie Semnanian interviewed Richard C. Rosenberg, M.D., a physician seeking appointment to the LACERA Panel of Examining Physicians.

Attached for your review and consideration are:


- Staff's Interview Summary and Recommendation
- Panel Physician Application
- Curriculum Vitae
- Sample Report(s).

IT IS THEREFORE RECOMMENDED THAT THE COMMITTEE accept the staff recommendation to submit the application of Richard C. Rosenberg, M.D., to the Board of Retirement for approval to the LACERA Panel of Examining Physicians.

Attachments

JJ:RC/mb

NOTED AND REVIEWED:



JJ Popowich, Assistant Executive Officer



August 16, 2016

TO: **Ricki Contreras, Manager**
Disability Retirement Services

FROM: **Debbie Semnanian, WCCP** *DS*
Supervising Disability Retirement Specialist

SUBJECT: **INTERVIEW OF ORTHOPEDIC SURGEON APPLYING FOR
LACERA PHYSICIAN'S PANEL**

On July 26, 2016, I interviewed **Richard C. Rosenberg, M.D.** at his office at 18370 Burbank Blvd., Suite 614, Tarzana, CA 91356. The office space is located in a well maintained seven-story building with patient paid parking (maximum \$6.00) located in the back of the building

Dr. Rosenberg is board certified in orthopedic surgery, and has been in private practice for over thirty years. Dr. Rosenberg's office has six complete examination rooms. He estimates that 50 percent of his practice is devoted to patient treatment, while the other 50 percent of his time is devoted to IME, QME, and AME evaluations within the workers' compensation system. Dr. Rosenberg shares office space with a chiropractor.

As referenced in his Curriculum Vitae, Dr. Rosenberg received his undergraduate degree from the University of California at Berkeley, and received his medical degree from the University of Texas in 1976. He completed an internship at the University of California at Irvine in 1977, and a residency at the University of California at Irvine in 1981. Dr. Rosenberg has held teaching appointments at the VA Medical Center in North Hills, California, and at Northridge Hospital Medical Center.

Dr. Rosenberg's office was clean with adequate seating. The office and restrooms are handicap accessible. Dr. Rosenberg has a staff of twelve employees.

Staff reviewed the LACERA Disability Retirement procedures and expectations in its evaluation of County Employees applying for both service-connected and non service-connected disability retirements. The importance of preparing impartial and non-discriminatory reports that are clear and concise and address issues of causation and incapacity were discussed with the doctor. He understood that he would adhere strictly to the HIPAA laws that would also apply for LACERA reports. Staff reviewed with Dr. Rosenberg the Panel Physician Guidelines for evaluating LACERA applicants and defined the relationship between workers'

compensation and disability retirement. Staff discussed the need to rely on his own objective and subjective findings rather than the opinions of previous physician reports and/or comments.

Dr. Rosenberg agreed to adhere to LACERA's standard of having his evaluation reports sent to us within 30 days of examination. Staff confirmed that Dr. Rosenberg is agreeable with accepting payment per the Official Medical Fee Schedule (OMFS). He has also been advised of the requirement to immediately notify LACERA if any license, Board certification, or insurance coverage is lapsed, suspended or revoked. Dr. Rosenberg was informed that if he is approved by the Board to be on our panel of physicians, he is required to contact the specialist assigned to the case for approval of any special tests or extraordinary charges. He was also informed that a Quality Control Questionnaire is sent to each applicant regarding their visit.

RECOMMENDATION

Dr. Rosenberg has an established practice and provides examinations in areas in which LACERA has a pressing need to add physicians. This will not only enable us to have patients travel shorter distances for examinations, but will also provide more equal distribution of examinations among our panel orthopedic specialists. Dr. Rosenberg expressed not only a willingness to be on our panel, but also an enthusiasm for building a relationship with LACERA.

Based on our interview and the need for his specialty, staff recommends Dr. Rosenberg's application be presented to the Board for approval as a LACERA Panel Physician.



300 N. Lake Ave., Pasadena, CA 91101 ■ Mail to : PO Box 7060, Pasadena, CA 91109-706 626/564-2419 • 800/786-6464

GENERAL INFORMATION		Date
Group Name:	Physician Name: <u>Richard C. Rosenberg, MD</u>	
I. Primary Address:	<u>18370 Burbank Blvd #614 Tarzana CA 91356</u>	
Contact Person	<u>Caroline Shredner</u>	Title <u>Administration</u>
Telephone:	<u>818 996 6800</u>	Fax <u>818 996 2029</u>
II. Secondary Address		
Contact Person	Title	
Telephone	Fax	
PHYSICIAN BACKGROUND		
Field of Specialty	<u>Orthopedics</u>	Subspecialty
Board Certification	<input checked="" type="checkbox"/> Yes <input type="checkbox"/> No	License # <u>634887</u> Expiration Date <u>1/31/18</u>
EXPERIENCE		
Indicate the number of years experience that you have in each category.		
Evaluation Type		
I. Workers' Compensation Evaluations		
<input type="checkbox"/> Defense	How Long? <u>30+</u>	<input type="checkbox"/> IME How Long? <u>30+</u>
<input type="checkbox"/> Applicant	How Long? <u>30+</u>	<input type="checkbox"/> QME How Long? <u>30+</u>
<input type="checkbox"/> AME	How Long? <u>30+</u>	
II. <input type="checkbox"/> Disability Evaluations How Long? <u>30+</u>		
For What Public or Private Organizations?		
Currently Treating? <input checked="" type="checkbox"/> Yes <input type="checkbox"/> No		
Time Devoted to:	Treatment <u>50</u> %	Evaluations <u>50</u> %
Estimated Time from Appointment to Examination	Able to Submit a Final Report in 30 days?	
<input type="checkbox"/> 2 weeks	<input checked="" type="checkbox"/> Yes <input type="checkbox"/> No	
<input checked="" type="checkbox"/> 3-4 Weeks		
<input checked="" type="checkbox"/> Over a month		
LACERA's Fee Schedule		
Examination and Initial Report by Physician	\$1,500.00 flat fee	
Review of Records by Physician	\$350.00/hour	
Review of Records by Registered Nurse	\$75.00/hour	
Supplemental Report	\$350.00/hour	

Other Fees	
Physician's testimony at Administrative Hearing (includes travel & wait time)	\$350.00/hour
Deposition Fee at Physician's office	\$350.00/hour
Preparation for Expert Testimony at administrative Hearing	\$350.00/hour
Expert Witness Fees in Superior or Appellate Court	\$3,500.00 half day \$7,000 full day
Physician agrees with LACERA's fee schedule? Yes No	
Comments	

Name of person completing this form:

Caroline Shrednick Title: Administrators
(Please Print Name)

Physician Signature: [Signature] Date: 3/24/16

FOR OFFICE USE ONLY	
Physician Interview and Sight Inspection Schedule	
Interview Date: <u>7/21/16</u>	Interview Time: <u>11:00 A.M</u>
Interviewer: <u>Debbie Linneman</u>	



Orthopedic Surgery

RICHARD C. ROSENBERG, M.D.

Diplomate American Board of Orthopedic Surgery

CONTACT INFORMATION	818.996.6800 drrosenberg@tarzanaortho.com www.drrosenberg.com
PRACTICE FOCUS	Fractures ▪ Joint Injuries & Arthritis ▪ Neck & Back Injuries Foot & Hand Injuries
COLLEGE	University of California at Berkeley, Berkeley, CA Bachelor of Sciences
MEDICAL SCHOOL	University of Texas Medical Branch at Galveston, Galveston, TX M.D. 1976
INTERNSHIP	University of California at Irvine, Irvine, CA General Surgery 1976 - 1977
RESIDENCY	University of California at Irvine, Irvine, CA Orthopedic Surgery 1977 - 1981
PROFESSIONAL SOCIETIES & BOARD CERTIFICATION	Diplomate of American Board of Orthopedic Surgery Fellow American Academy of Orthopedic Surgeons California Orthopedic Association Western Orthopedic Association
PRIOR TEACHING APPOINTMENTS	VA Medical Center, North Hills, CA Clinical Instructor through 1994 Northridge Hospital Medical Center, Northridge, CA Clinical Instructor - Residency Program through 2005
HOSPITAL PRIVILEGES	Providence Tarzana Medical Center, Tarzana, CA Sherman Oaks Hospital, Sherman Oaks, CA St John's Hospital, Oxnard, CA
EVALUATIONS	IME, QME, AME, Expert Testimony

Tel 818.996.6800 | Fax 818.996.2929

18370 Burbank Boulevard | Suite 614 | Tarzana | California | 91356

Satellite Offices | Santa Ana | Oxnard

SAMPLE REPORT # 1

[REDACTED]

[REDACTED]
[REDACTED]
[REDACTED]

Law Offices of [REDACTED]
[REDACTED]
[REDACTED]

ATTN: [REDACTED]
[REDACTED]

ATTN: [REDACTED]

RE: [REDACTED]
D/I: [REDACTED]
EMP: [REDACTED]
PT FILE #: [REDACTED]
D/E: [REDACTED]
CLAIM #: [REDACTED]
PICTURE ID: [REDACTED]

AGREED MEDICAL EVALUATION

The above-captioned patient is a [REDACTED] year-old, right-handed [REDACTED] who was seen in my office on [REDACTED] for an **AGREED MEDICAL EVALUATION** of injuries which [REDACTED] associates with an accident that occurred at work.

EMPLOYMENT HISTORY:

[REDACTED] began [REDACTED] employment with the [REDACTED] in the [REDACTED] in [REDACTED] [REDACTED] was hired for the position of [REDACTED] [REDACTED] became an [REDACTED] 1-1/2 years later. [REDACTED] states that 6 years later [REDACTED] changed departments. [REDACTED] began working in the [REDACTED] [REDACTED] says that around [REDACTED] began working in the [REDACTED]

[REDACTED] job duties as an [REDACTED] include reconciling payments, reconciling and closing deposits, monitoring payments, posting payments and reversing uncollected

[REDACTED]
[REDACTED]
Page 2

payments. [REDACTED] supports management and trains employees. [REDACTED] sometimes has to do research, which requires [REDACTED] to access boxes which are stacked on top of each other in a storage area.

The physical requirements consisted of prolonged computer and intermittent use of the telephone. [REDACTED] stands, walks, bends, reaches, does repetitive arm and hand movements and fine finger manipulation. [REDACTED] lifts and carries boxes weighing up to 20 pounds. [REDACTED] works 9 hours per day, 9 days every two weeks.

[REDACTED] is currently working regular duty for this employer as an [REDACTED]. [REDACTED] says that while [REDACTED] was on disability they re-assigned some of [REDACTED] job duties. [REDACTED] no longer closes deposits. [REDACTED] says [REDACTED] still does research, but does not have to access boxes as much as before.

CONCURRENT EMPLOYMENT:

[REDACTED] denies concurrent employment.

SUBSEQUENT EMPLOYMENT:

[REDACTED] denies subsequent employment.

PRIOR EMPLOYMENT:

Prior to working for the subject employer, [REDACTED] worked for an [REDACTED] company as a [REDACTED]. [REDACTED] denies any injuries.

HISTORY OF INJURY:

[REDACTED] states that [REDACTED] started having pain in [REDACTED] bilateral wrists, in [REDACTED] right thumb, right 2nd finger and right 3rd finger and numbness in the 4th and 5th fingers of [REDACTED] left hand sometime in [REDACTED] attributed this to use of [REDACTED] keyboard at work. [REDACTED] states that to do [REDACTED] work, [REDACTED] had to cross [REDACTED] left hand over [REDACTED] right hand. [REDACTED] said [REDACTED] would shake [REDACTED] hands when [REDACTED] had discomfort. [REDACTED] mentioned to [REDACTED] supervisor that [REDACTED] hands were getting tired.

Page 3

then started having numbness in the tops of both of wrists, below her 5th fingers. would massage this area and noticed that it was tender. says that over time, started having pain in both forearms and elbows. states that shoulders and neck were also uncomfortable at times. recalls doing neck and arm exercises, which helped somewhat, however, states that over time, symptoms worsened. In or began having an "electric shock sensation" in left arm and hand. would occasionally feel a "pulsating sensation" in left forearm and palm. recalls "arms felt dead" when woke up in the morning. says had to close and open hands several times to get the circulation going. says everything (from neck to fingers) felt heavy.

phoned claims adjuster because felt that it was related to previous claim, however, adjuster told to inform supervisor and file a claim. filed a claim in and was subsequently referred to , a hand and wrist specialist.

says that prescribed Tramadol, a muscle relaxer and anti-inflammatory medication and took off work. was referred for MRI scans of shoulders, arms and wrists. He referred to a spine specialist to review the films.

saw a spine specialist at . cannot recall his name. He referred for physical therapy. says had a lot of tenderness in neck and right shoulder at this time. had 24 sessions of physical therapy to neck, shoulders and upper arms with temporary benefit. was recommended epidural steroid injections. asked if could have acupuncture instead. had acupuncture treatment with benefit. states that neck, arm and hand pain decreased to the level of 3-4 out of 10, but if did activities, it increased to 8 out of 10. believes that completed the acupuncture in or . states that had stopped taking the medications prescribed because they caused to hallucinate.

states that did not have any treatment after acupuncture. While having acupuncture, the spine specialist requested a cervical spine epidural injection. The request was denied twice.

then retained legal counsel, who referred to , an orthopedic surgeon. He recommended trigger point injections. does not know if these were authorized or denied but has not had these injections.

██████████
██████████
Page 4

██████████ was returned to work by ██████████ in ██████████ with some restrictions. ██████████ does not remember what the restrictions were, but they were not accommodated. ██████████ asked that the restrictions be removed, and they were. ██████████ says that while ██████████ was gone, some of ██████████ job duties were assigned to others.

██████████ uses hot and cold compresses and massages the areas where ██████████ has pain. ██████████ says that massaging ██████████ aggravates ██████████ elbows, arms and hands. ██████████ does neck exercises every other day. ██████████ says ██████████ was given some "rubber" to stretch ██████████ arms, but it broke. ██████████ does not do any other home exercises. ██████████ takes Tylenol, as needed.

PRE-POST CAPACITY FOR LIFTING:

Prior to this claim, ██████████ states that ██████████ was able to lift and carry approximately 50 pounds comfortably. Presently, ██████████ is able to lift and carry approximately 10 pounds comfortably.

PAST MEDICAL HISTORY:

██████████ denies heart disease, diabetes, hypertension, lung disease, cancer, arthritis, fibromyalgia, and osteoporosis or blood disorders.

██████████ states that in ██████████ was involved in a motor vehicle accident. ██████████ vehicle hit a light pole. ██████████ injured ██████████ neck. ██████████ had physical therapy and ██████████ symptoms resolved in 3-6 months.

About ██████████ years ago ██████████ was a ██████████ for the ██████████ and was supervising 5 people. ██████████ says ██████████ was required to pull and push a "cash truck". ██████████ says that it like a 2-drawer file cabinet on rollers and made of steel. ██████████ had to pull it out of the vault and push it under the counter each morning and in the evening ██████████ had to put it back in the vault. ██████████ was unable to state how much the cabinet weighted. ██████████ says doing this also required a lot of bending and stooping. ██████████ began to have pain in ██████████ right arm, wrist, 2nd finger and thumb. ██████████ was diagnosed with right wrist, thumb and 2nd finger tendonitis. ██████████ had therapy on and off, approximately 30 visits all together. ██████████ had benefit. ██████████ believes ██████████ stopped treating for this injury less than a year after the claim was filed. ██████████ believes the claim was "left open". ██████████ says ██████████ job changed after that. ██████████ states ██████████ did not have treatment again until after ██████████ filed ██████████ claim.

[REDACTED]
[REDACTED]
Page 5

[REDACTED] denies any other prior or subsequent work, auto or sports-related accidents or injuries.

SOCIAL/RECREATIONAL HISTORY:

[REDACTED] is divorced with [REDACTED] children.

[REDACTED] has problems with dressing. [REDACTED] says [REDACTED] has to do everything slowly.

[REDACTED] has problems with doing household chores such as sweeping and vacuuming. [REDACTED] says [REDACTED] can only clean [REDACTED] house once a month.

[REDACTED] notes problems with opening and closing jars and drawers due to pain and loss of strength. [REDACTED] says [REDACTED] drops things.

[REDACTED] has problems with driving. [REDACTED] has to shift slowly and steer slowly. [REDACTED] cannot turn [REDACTED] head quickly to look for other drivers.

[REDACTED] sometimes has problems sleeping because of sharp pain [REDACTED] neck.

[REDACTED] feels stressed due to [REDACTED] physical condition and the inability to function as before.

EXTRA CURRICULAR ACTIVITIES:

[REDACTED] no longer plays volleyball, bowls or swims.

ALLERGIES & MEDICATIONS:

[REDACTED] has allergic to Penicillin, aspirin, steroid medication and muscle relaxers.

At the present time, takes Tylenol, as needed.

Page 6

PRESENT COMPLAINTS:

NECK: [REDACTED] experiences pain in the neck, which is constant. The pain increases with prolonged positioning and repetitive movement of the head and neck, forward bending, pushing, pulling and lifting. [REDACTED] sometimes feels that [REDACTED] neck pain radiates to [REDACTED] head.

LEFT SHOULDER/ARM: [REDACTED] experiences pain in the left shoulder between [REDACTED] neck and left shoulder blade, which is constant. The pain increases with forward and backward reaching and pushing, pulling, repetitive movement and lifting greater than 5-10 pounds. [REDACTED] is unable to tell if the pain radiates. There is numbness and a feeling of heaviness in [REDACTED] left arm.

RIGHT SHOULDER/ARM: [REDACTED] experiences pain in [REDACTED] right rotator cuff, which is intermittent. The pain increases with forward, lateral or overhead reaching, pushing, pulling, repetitive movement and lifting greater than 5-10 pounds. There is radiating pain down [REDACTED] arm to [REDACTED] hand.

BILATERAL ELBOWS: [REDACTED] experiences pain in the bilateral elbows, which is intermittent. The pain depends on the position of [REDACTED] arms and how long [REDACTED] arms have been in a certain position. [REDACTED] feels neither elbow is worse than the other. The pain increases with flexing, extending, pushing, pulling and repetitive movements.

RIGHT HAND/WRIST: [REDACTED] experiences pain in [REDACTED] right hand and wrist, which is intermittent. [REDACTED] also notes pain in [REDACTED] fingers and thumbs. The pain increases with grasping, torquing motions, fine finger manipulation, repetitive hand movement, pushing, pulling and lifting greater than 5-10 pounds. [REDACTED] has numbness in [REDACTED] 5th finger that radiates to [REDACTED] elbow. [REDACTED] has tingling in [REDACTED] thumb and in the 3rd and 4th fingers of [REDACTED] right hand.

LEFT HAND/WRIST: [REDACTED] experiences pain "somewhere" in [REDACTED] left hand which feels like "ants biting [REDACTED]" and this is intermittent. [REDACTED] experiences tenderness in [REDACTED] wrist "in the bone below [REDACTED] 5th finger". [REDACTED] has frequent numbness in [REDACTED] 4th and 5th fingers. [REDACTED] notes no tingling in the left hand.

Page 7

PHYSICAL EXAMINATION:

Weight: [REDACTED] pounds. Height: [REDACTED]
 Blood Pressure: [REDACTED]

For range of motion measurements, please see Range of Motion Inclination report attached.

[REDACTED] is an alert, well nourished [REDACTED].

Examination of the cervical spine shows no torticollis. There is tenderness at the base of the left side of the neck, with associated muscle spasm to deep palpation, along the medial trapezius and paracervical region at approximately C5-6. There is some guarding with right lateral bending. There is a negative foraminal compression test and a negative Spurling's sign.

Comprehensive motor examination of the upper extremities including the shoulder abductors, flexors and extensors, the wrist flexors and extensors, the forearm supinators and pronators, the finger extensors, flexors and intrinsic muscles shows 5+/5+ motor power bilaterally.

Reflexes	Right	Left
Biceps jerks	2+	2+
Triceps jerks	2+	2+
Brachioradialis	2+	2+

Comprehensive sensory examination of the upper extremities shows a normal dermatomal pattern to pinprick and deep touch.

There is no scapulothoracic crepitus or pain. There is no winging of the scapulae. Adson's and Valsalva tests for thoracic outlet syndrome are negative, as is Roos test.

Examination of the left shoulder shows diffuse tenderness over the left deltoid. There is a negative Neer and a negative Hawkins impingement sign. There is good range of motion of the left shoulder and there is good strength of the abductors.

Page 8

Examination of the right shoulder shows mild anterior subacromial tenderness. There is a negative Neer and a negative Hawkins impingement sign. There is good range of motion of the shoulder. There is good strength of the abductors of the shoulder.

Examination of the elbows shows a positive Tinel's sign bilaterally over the medial epicondyle. There is no lateral epicondylar tenderness. There is full range of motion.

Examination of the bilateral hands and wrists shows a negative Finkelstein's test bilaterally. There is a positive Tinel's sign over the carpal tunnel, bilaterally. There is a negative Phalen's test.

Sensation is normal in the distribution of the radial, ulnar and median nerves, bilaterally. There is no intrinsic muscle atrophy bilaterally.

Upper extremity measurements:

Major Hand: Right

Circumferences:	Right	Left
Biceps at greatest circumference	25 cm	25.5 cm
Elbow	22 cm	22.5 cm
Forearm (2" below elbow)	22.5 cm	22.5 cm
Wrist	14 cm	14 cm
Hand	19.5 cm	18.75 cm

Grip strength:

Jamar Dynamometer Readings

Right	Left
10 kg	13 kg
14 "	14 "
14 "	12 "

REVIEW OF RECORDS:

Received are medical records regarding the above captioned patient.

There is a Qualified Medical Examination report dated [REDACTED] by [REDACTED] [REDACTED], a [REDACTED] year-old, right-handed [REDACTED] stated that [REDACTED] initially developed symptoms affecting [REDACTED] right hand

██████████
██████████
Page 9

in ██████████ while working as the ██████████ for the ██████████. ██████████ was referred for physical therapy and it was noted that ██████████ had never been off work. Later, on ██████████ ██████████ developed radiation of pain from the hand and wrist proximally involving the right elbow and shoulder. ██████████ had physical therapy that consisted of electrical stimulation and ultra-sound. ██████████ was then "advised to use the left upper extremity to make it easier for the right" and had since developed pain in ██████████ left shoulder which ██████████ had some sessions of physical therapy for. ██████████ was placed on a home exercise program and had an ergonomic evaluation of ██████████ work space. ██████████ also said that ██████████ had EMG studies done.

Upon physical examination no abnormalities were noted. Diagnosis: Residuals of sprain, right major wrist. It was the opinion of ██████████ that the issues regarding the right shoulder/wrist and the left shoulder were industrially related and ██████████ was released to work at ██████████ present position without any restrictions. Future medical treatment included appropriate analgesics and short courses of physical therapy for exacerbation of pain. Apportionment: It was felt that 100% of ██████████ present permanent disability was due to the effects of the specific injury on ██████████ Impairment: ██████████ remained with a zero percent impairment of the whole person in keeping with the AMA Guidelines, 5th Edition.

A report by ██████████ dated ██████████ notes that after reviewing several records, his assessment, apportionment and impairment remained unchanged from his initial evaluation in ██████████

In a follow up report by ██████████ dated ██████████ he reported that ██████████ still continued to use ██████████ hands repetitively at work. ██████████ returned to him with chief complaints of pain, numbness and tingling in the thumb and index fingers bilaterally with pain in ██████████ neck "into" both arms, and with ██████████ symptoms being greatest in ██████████ bilateral shoulders. Upon physical examination it was noted that there was mild discomfort at the extremes of shoulder abduction bilaterally, mild bilateral trapezius tenderness, and mild limitation of cervical spine range of motion with discomfort.

Impression: 1. CTD of bilateral upper extremities and cervical spine. It was felt that this was a new injury as ██████████ symptoms were different than they were at the time of his initial evaluation in ██████████ 2. Rule out cervical radiculopathy and peripheral nerve entrapment. ██████████ disability status included no "flipping of pages with the left upper extremity". The plan was to consist of an ergonomic evaluation, MRI of the cervical spine, electrodiagnostic testing of bilateral upper extremities and cervical spine and a

[REDACTED]
[REDACTED]
Page 10

reevaluation in four weeks' time. The following medications were also prescribed; Voltaren, Protonix, Ultram, Flexeril (It was later revealed that [REDACTED] was allergic to aspirin and [REDACTED] was advised to discontinue the Voltaren).

Included is a first report of occupational injury by [REDACTED], dated [REDACTED]. [REDACTED] said that this was a "cumulative" injury that started on [REDACTED] while typing multiple documents working as an [REDACTED] for the [REDACTED]. There are multiple references to an attached report, however there were no narrative reports included in the submitted medical records.

There is an MRI study performed of the cervical spine dated [REDACTED] and interpreted by [REDACTED]. Indications for the exam were musculoskeletal symptoms referring to the limbs.

Findings:

There was a straightening of the cervical spine, which may have been positional or related to spasm. The visualized portions of the posterior fossa and cervical cord demonstrated normal morphology and signal intensity. The vertebral body heights were preserved.

C2-C3: There was no significant disk bulge or protrusion. The canal and neural foramina are patent the facet joints are not hypertrophied.

C3-C4: There was disk desiccation present. There was a 2mm central disk protrusion present. There were degenerative changes of the facet joints (left greater than right). There was a mild left uncovertebral joint arthropathy. There was mid left foraminal stenosis. The central canal and right neural foramen were patent.

C4-C5: There was disk desiccation and disk space height loss, consistent with degenerative disk disease. There was posterior osteophytic ridging/disk material (2-3mm), causing effacement of the anterior thecal sac. There were degenerative changes of the facet joints along with bilateral uncovertebral joint arthropathy, causing mild right and moderate left neural foraminal stenosis.

C5-C6: There was disk desiccation present. There was a small focus of increased T2 weighted signal intensity noted centrally within the posterior aspect of the disk, suspect from an annular fissure or tear. The latter was associated with a 2mm broad-based central

[REDACTED]
[REDACTED]
Page 11

disk protrusion. There were degenerative changes of the facet joints (left greater than right). There was a mild left neural foraminal stenosis. The central canal and right neural foramen were patent.

C6-C7: There were no significant disk bulges or protrusions. The canal and neural foramina were patent. Mild hypertrophic changes of the facet joints were present. There were nerve sleeve cysts noted in bilateral neural foramina.

C7-T1: There was disk desiccation present. There was a 1mm diffuse broad-based disk bulging present. There was no significant canal or neural foraminal stenosis noted. Nerve sleeve cysts were noted in bilateral neural foramina. The facet joints are mildly hypertrophied.

In a follow up report by [REDACTED] dated [REDACTED] it was noted that [REDACTED] continued to have pain in [REDACTED] neck to [REDACTED] right arm, most of the right thumb, index and middle finger and the left thumb and index finger. The mechanism and history of present injury remained unchanged. [REDACTED] reviewed the MRI studies and electrodiagnostic studies (which were not included in the records received). Impression: 1. CTD of bilateral upper extremities and the cervical spine, 2. Probable cervical radiculopathy. [REDACTED] was to have a spine surgery consultation and return for reevaluation in six weeks.

There is an initial orthopedic consultation by [REDACTED] dated [REDACTED]. [REDACTED]'s chief complaints were of neck and upper arm pain. While performing [REDACTED] at work on [REDACTED] [REDACTED] reportedly felt the onset of a "throbbing" pain to [REDACTED] neck, arms and hands along with numbness, no specific injury was recalled. [REDACTED] stated that pain in the neck and right arm were constant without radiation, that [REDACTED] had limited range of motion of the neck and right arm, was awakened by pain at night, had pain that was aggravated by turning [REDACTED] head to either side and was predominantly located on the left. [REDACTED] also noted difficulties with activities of daily living including, getting dressed, putting on socks and shoes, using the toilet, doing housework, driving and sleeping through the night.

In [REDACTED] past history of present complaints it was noted that [REDACTED] sustained injuries to both hands and wrists in [REDACTED] while working for the same employer. [REDACTED] received physical therapy and gradually improved. At the time of the evaluation [REDACTED] had worked for the [REDACTED] [REDACTED] for [REDACTED] years and as an [REDACTED] was required to type, flip pages,

██████████
██████████
Page 12

and use a computer. Following the ██████ injury ██████ continued working until ██████ and had remained off work since that date.

Upon physical examination there was some limitation of cervical range of motion, lateral tenderness to palpation over the right trapezius, sensory examination revealed diminished sensation to pinprick in the entire right arm. Diagnoses: 1. Cervical strain, 2. Degenerative cervical disc disease at C4-5 with a small central herniation at that level, 3. Normal electrodiagnostic testing of the neck and upper extremities "by report on ██████ (please note that this electrodiagnostic test was not present in the records received). The plan was for ██████ to follow up with ██████ primary physician, continue with a physical therapy program for ██████ neck, and if ██████ remained symptomatic, a cervical epidural block at the C4-5 level was to be considered.

There is a report of radiologic findings by ██████ dated ██████ in which he discussed a cervical x-ray taken that day and the MRI findings from ██████ listed above. His impressions after the records evaluation were: 1. Moderate degenerative disc narrowing at C4-5, 2. Small central disc protrusion/osteophyte at C4-5.

There are several follow up reports by ██████ ranging from ██████ to ██████. The mechanism and history of the injury remained unchanged throughout. On ██████ it was noted that ██████ symptoms were unchanged and that ██████ had bilateral trapezial tenderness and spasm, and limited cervical range of motion with discomfort. Impression: 1. CTD of bilateral upper extremities, 2. Probable cervical radiculopathy. The plan was to consist of a prescription for Soma, physical therapy 3x a week x4 weeks, and to return for reevaluation in six weeks. In the ██████ follow up report it is noted that ██████ had attended 2/12 physical therapy visits and continued to have radiating pain from neck to right shoulder and occasionally at the radial aspect of the right wrist. Impression was unchanged as was the plan. On ██████ it was noted that ██████ was receiving some relief with acupuncture but noticed weakness in ██████ bilateral upper extremities with some numbness in the left little finger. ██████ had a positive Tinel's sign at the ulnar nerve of the left elbow and the median nerve of the left wrist. The plan was for ██████ to have a surgical consultation with ██████ continue with acupuncture and return for reevaluation in four weeks.

In an orthopedic reexamination by ██████ dated ██████ it was noted that since ██████ initial examination ██████ had remained symptomatic with neck and upper extremity complaints and that the recommended cervical epidural block had been denied.

██████████
██████████
Page 13

Upon physical examination it was noted that ██████ had tenderness to palpation over the right trapezius. ██████ also said that the acupuncture did offer some relief but that ██████ could not sleep the night before due to the severity of ██████ neck pain. Diagnoses: 1.Cervical strain, 2.Degenerative cervical disc disease at C4-5 with a small central herniation at that level. Treatment: It was felt that ██████ was a candidate for a cervical epidural block. ██████ then deferred ██████ disability status to ██████████

Included in the records are further follow up reports by ██████████ ranging from ██████████ to ██████████. The mechanism and history of injury remained unchanged. On ██████████ a positive Tinel's sign was noted at the ulnar nerve of the left elbow and the median nerve of the left wrist with mild bilateral trapezial tenderness. The impression remained unchanged from his previous follow up reports and the plan was for ██████ to return in 5 weeks and obtain an epidural steroid injection. On ██████████ the impression was updated to include left cubital tunnel syndrome. The plan consisted of acupuncture and a reevaluation in 6 weeks. On ██████████ a physical evaluation revealed mild bilateral trapezial tenderness and mild limitation of cervical spine range of motion. At that time it was recommended that ██████ be released to regular duty, reexamined in six weeks, and return to activities as tolerated.

An Initial Physical Medicine and Rehabilitation Consultation and Electrodiagnostic Evaluation of the Neck and Bilateral Upper Extremities Report from ██████████ dated ██████████ is reviewed. The date of injury is ██████████. The present complaints include pain in the neck and bilateral arms, all the time, with limited range of motion of the neck and right arm, and pain aggravated by turning the head to either side.

Diagnosis: the electrodiagnostic study reveals evidence of mild left C6/C7 radiculopathy with chronic denervation. Recommendation was for follow-up with the undersigned for definitive care.

DIAGNOSES:

1. Cervical myofascial strain.
2. EMG evidence of mild left C6/C7 radiculopathy with chronic denervation.
3. Bilateral cubital tunnel syndrome, clinically, electrodiagnostically negative.

4. Bilateral carpal tunnel syndrome, clinically, electrodiagnostically negative.

DISCUSSION:

presents with complaints of pain in neck, bilateral shoulders, with numbness and feeling of heaviness in the left arm and radiating pain down the right arm to the hand, with pain in both elbows and pain and numbness and altered sensation in the bilateral wrists/hands, which relates to work related activities during the course of employment as a for the . There is no history of any specific incident or injury at work on and the complaints that describes attributes to repetitive, continuous trauma activity involving the upper extremities and neck. describes job activities as including working on a computer with intermittent use of a telephone, involving repetitive arm and hand movements, and fine finger manipulation, as well as lifting and carrying of boxes weighing up to 20 pounds. describes computer work, which involves maintaining the neck/head in prolonged positioning.

states noticed the onset of pain in both wrists/hands sometime in with numbness in the fourth and fifth fingers of left hand, which attributes to using a computer keyboard at work.

describes subsequent development of increased numbness in wrists and hands, and increased pain in upper extremities including shoulders, and notes that at times neck would also become uncomfortable. went on to describe further worsening of the upper extremity complaints, including development of electric shock sensation in left upper extremity and pulsating sensation in the right forearm and palm.

also has a past medical history of having filed a claim for an upper extremity injury at work in the past, and states has left the claim open.

also reports having been involved in a motor vehicle accident in in which sustained injury to neck, for which received physical therapy and symptoms resolved in 3-6 months.

[REDACTED]
[REDACTED]
Page 15

[REDACTED] states that [REDACTED] filed a claim for [REDACTED] neck and upper extremity complaints in [REDACTED] after discussing the matter with [REDACTED] adjuster for the previous claim. [REDACTED] states that [REDACTED] was referred to [REDACTED] who treated [REDACTED] with medications. [REDACTED] had MRI scans of [REDACTED] shoulders, arms and wrists, according to [REDACTED] history.

Should additional medical records be provided relating to MRI scans of [REDACTED] shoulders, arms and wrists, I would be interested in reviewing them and providing comment in a supplemental report.

[REDACTED] also states that [REDACTED] saw a spine specialist who referred [REDACTED] for physical therapy.

[REDACTED] also states that [REDACTED] had acupuncture treatment, and while receiving acupuncture the spine specialist had requested a cervical epidural injection that was denied.

After retaining legal counsel [REDACTED] was referred to an orthopedic surgeon who recommended trigger point injections.

[REDACTED] states that [REDACTED] saw [REDACTED] in [REDACTED] and returned [REDACTED] to work with restrictions for a period of time, and then the restrictions were removed, at [REDACTED] request.

On review of the available records, there is a Qualified Medical Examination Report dated [REDACTED] by [REDACTED], indicating [REDACTED] initially developed symptoms in [REDACTED] while working as a [REDACTED] for the [REDACTED]. It was noted that in [REDACTED] had radiation of pain from [REDACTED] hand and wrist proximally involving [REDACTED] right elbow and shoulder, and also developed left shoulder pain after [REDACTED] was advised to use the left upper extremity and make it easier for the right. [REDACTED] noted that on physical examination no abnormalities were noted and he diagnosed [REDACTED] with residuals of right major wrist sprain. [REDACTED] was released to work without any restrictions. Future medical care was indicated for exacerbations of pain, including analgesic medication and short courses of physical therapy. [REDACTED] noted that there was 0% impairment of the whole person, apportioned 100% to the specific injury of [REDACTED]

The [REDACTED] report by [REDACTED] indicates [REDACTED] was still using [REDACTED] hands repetitively at work and [REDACTED] was complaining of pain, numbness and tingling in [REDACTED] thumb and index fingers bilaterally with pain going from [REDACTED] neck into both arms. [REDACTED] also noted symptoms in both shoulders. An MRI of the cervical spine and electrodiagnostic

██████████
██████████
Page 16

testing of the bilateral upper extremities was indicated. ██████████ was treated with medications. ██████████ felt this was a new injury as ██████████ symptoms were different than that of his initial evaluation in ██████████

The first report by ██████████ dated ██████████ indicates this was a cumulative injury that started on ██████████ while typing multiple documents, working as an ██████████ for the ██████████.

An MRI of the cervical spine on ██████████ was interpreted as revealing straightening of the cervical spine, and findings consistent with cervical spondylosis throughout. At C4-5 there was noted to be moderate left neural foraminal stenosis, along with posterior osteophytic ridging/disc material measuring 2-3mm effacing the anterior thecal sac. At C5-6 the findings suggested annular fissure or tear with 2mm disc protrusion and some left neural foraminal stenosis at this level. Also at the C5-6 level there were findings suggestive of annular fissure or tear with 2mm disc protrusion. At the C6-7 level there were noted to be nerve sleeve cysts in the bilateral neural foramina, however no significant bulge or protrusion is present at this level.

██████████ consulted ██████████ on ██████████ who noted a small disc herniation at C4-5 with cervical strain, and normal electrodiagnostic testing of the neck and upper extremities as per the report dated ██████████

Of note, the ██████████ electrodiagnostic test report is currently unavailable for review, and when it is provided I would be able to review it and provide comment in a supplemental report.

██████████ indicated ██████████ was a candidate for a physical therapy program and if ██████████ remained symptomatic a cervical epidural block at C4-5 was considered.

For the latter half of ██████████ noted that ██████████ had no change in symptoms, and had developed positive Tinel's sign in the ulnar nerve at the left elbow and median nerve at the left wrist for which he recommended surgical consultation with ██████████ He also recommended treatment with acupuncture be continued.

On ██████████ again saw ██████████ who noted the cervical epidural block he had recommended was denied. He felt that ██████████ was a candidate for a cervical epidural block.

[REDACTED]
[REDACTED]
Page 17

In the first half of [REDACTED] treating physician again recommended an epidural steroid injection. The plan was for acupuncture. Then on [REDACTED] was released to regular duty.

At the present time [REDACTED] reports continuous neck pain that increases with a number of activities, and [REDACTED] describes numbness and heaviness in the left arm, and numbness in the left fourth and fifth fingers. [REDACTED] also describes a sensation like "ants biting [REDACTED]" somewhere in the left hand that occurs intermittently.

Examination of the cervical spine shows tenderness at the base of the left side of the neck, with associated muscle spasm to deep palpation, along the medial trapezius and paracervical region at approximately C5-6. There is some muscle guarding with right lateral bending of the cervical spine. Spurling's sign is negative, as is foraminal compression test, and motor, sensory and reflex examinations of the cervical dermatomes are unremarkable, indicating no need for cervical spine injections or surgery at this point. [REDACTED] has found a left C6, C7 mild chronic radiculopathy on EMG, however on review of his report, sensory, motor and reflex examinations of the upper extremities are all normal, and Spurling's sign is negative as well.

It would appear that [REDACTED] has requested [REDACTED] restrictions be removed so that [REDACTED] can work without restriction.

On physical examination the cervical spine is stable and has reached maximum medical improvement at this time.

Subjective factors for the cervical spine are characterized as frequent minimal to slight discomfort that intermittently increases to slight and occasionally slight to moderate.

The objective factors include the results of x-rays, cervical MRI scan and EMG and nerve conduction studies of the cervical spine, as well as the findings on physical examination in my office.

As there is no clear cut clinical correlation to support the EMG findings, there is no indication for any formal work restrictions for the neck.

██████████
██████████
Page 18

Whole person impairment for the cervical spine is based on the objective findings. Tenderness is present at the base of the left side of the neck, with associated muscle spasm, along the medial trapezius and paracervical region at approximately C5-6. Right lateral bending causes some muscle guarding. Spurling's sign is negative, as is Foraminal Compression Test, and motor, sensory and reflex examinations of the upper extremities are all unremarkable, although the EMG does demonstrate some clinical evidence of a mild chronic radiculopathy in the left C6, C7 distribution, which is somewhat supported by the findings on MRI scan. At C5-6 there is an annular fissure or tear suspected. It is known that annular tear or annular fissure can cause radicular complaints without frank nerve root compression.

Considering the MRI and EMG findings support a cervical radiculopathy, subclinically, DRE Cervical Category III, low end, is appropriate for 15% whole person impairment.

Future medical care for the cervical spine should include a regular home exercise program and over-the-counter analgesic and non-steroidal anti-inflammatory medications as needed for symptomatic relief. For significant flare-ups ██████ can return to ██████ treating physician for appropriate prescription medications and short courses of physical therapy limited to 12 sessions per flare-up. Should the cervical spine condition deteriorate and fail to respond to more conservative treatment, as there is EMG evidence of cervical radiculopathy, and MRI evidence somewhat supportive of cervical radiculopathy, cervical epidural steroid injections would be a potential treatment option, particularly if there is clinical correlation for cervical radiculopathy. As there is no clinical evidence to support cervical radiculopathy at this time there is no indication for cervical spine surgery as part of her future medical care for this injury based on the objective findings.

██████████ reports a history of prior injury to ██████ neck in a motor vehicle accident a number of years ago, for which ██████ received treatment for approximately half a year. The MRI of the cervical spine demonstrates significant degenerative changes throughout, including disc desiccation consistent with degenerative disc disease, osteophytic ridging and degenerative changes of the facet joints, which are all findings of longstanding duration, pre-existing the injury at work reported on ████████████████████ which appear to be contributing to the current level of impairment. The work ████████████████████ has described performing at work has involved repetitive upper extremity activity with development of complaints involving ██████ shoulders and cervical spine, and as ██████ has been performing prolonged computer work, involving prolonged positioning of the neck/head, it would

[REDACTED]
[REDACTED]
Page 19

appear that [REDACTED] occupational duties have caused or contributed to continuous trauma to the cervical spine on an industrial basis.

[REDACTED] has a history of having been working for this employer since [REDACTED]. [REDACTED] has a history of having sustained a prior injury to [REDACTED] upper extremities with symptoms that began in [REDACTED] and the Qualified Medical Evaluator on [REDACTED] found [REDACTED] had 0% impairment of the whole person in regard to that prior injury. It would appear that some of the degenerative changes in the cervical spine developed as a result of the aggravation of the underlying degenerative condition while working for the [REDACTED], in addition to the natural aging process. Should a continuous trauma claim be filed for the cervical spine I would inclined to apportion 20% of the cervical spine impairment to the underlying degenerative condition that may well have been contributed to by the period of inflammation following the prior motor vehicle accident on a non-industrial basis, and also contributed to by the effects of the natural aging process, and 80% would be apportioned to continuous trauma at work involving prolonged positioning of the neck/head while working with the injured upper extremities on a cumulative trauma basis.

Both shoulders appear to be symptomatic. The symptoms increase with activities.

After examining both shoulders there is no indication for any invasive treatment to the shoulders and [REDACTED] can be considered to have reached maximum medical improvement at this time.

Subjective factors for the left shoulder are characterized as continuous minimal to slight discomfort that intermittently increases to slight and occasionally becomes slight to moderate. The right shoulder subjective complaints are characterized as intermittent minimal to slight discomfort that occasionally becomes slight.

Objective factors for the shoulders include the findings on physical examination in this office.

[REDACTED] can continue working without restrictions referable to both shoulders.

Examination of the left shoulder shows diffuse tenderness over the deltoid muscle, and otherwise there is good but not excellent range of motion of the left shoulder on goniometry. There is good strength of the abductors of the left shoulder. On J-Tech

[REDACTED]
[REDACTED]
Page 20

Inclinometry there is loss of motion of the left shoulder for which there is 1% upper extremity impairment for loss of flexion, 1% for extension and 1% for internal rotation totaling 3% upper extremity impairment, converting to 2% whole person impairment for the left shoulder.

Examination of the right shoulder reveals mild anterior subacromial tenderness, and otherwise there is good range of motion of the right shoulder; however, goniometry measurements are not recorded. There is good strength of the abductors of the shoulder. On J-Tech Inclinometry there is loss of motion of the right shoulder, 2% upper extremity impairment for loss of flexion, 1% for extension, and 1% for abduction totaling 4% upper extremity impairment, converting to 2% whole person impairment.

Future medical care for both shoulders should include a regular home exercise program and over-the-counter analgesic and non-steroidal anti-inflammatory medications as needed for symptomatic relief.

There is no history of any prior shoulder injury involving impairment.

Based on the information available to me I would apportion 100% of the bilateral shoulder impairment to the work related injury that appears to have been reported on [REDACTED] consistent with continuous trauma as a result of the work activities subsequent to the prior Qualified Medical Examination of [REDACTED] when there was 0% impairment relating to the shoulders and upper extremities.

[REDACTED] complains of pain in both elbows that increases with some activities.

Examination of both elbows has demonstrated a positive Tinel's sign over the medial epicondyle, bilaterally, consistent with cubital tunnel syndrome clinically. I ordered EMG and nerve conduction studies of the cervical spine and bilateral upper extremities, which have ruled out cubital tunnel syndrome, electrodiagnostically, indicating there is no need for cubital tunnel release surgery at this time.

Both elbows have reached maximum medical improvement as of the date of examination in this office.

Subjective factors for the bilateral elbows are characterized as intermittent slight discomfort that occasionally increases to slight to moderate.

Page 21

Objective factors for both elbows include the results of the EMG and nerve conduction studies, and the findings on physical examination in this office.

can continue working without formal restriction referable to elbows.

Whole person impairment for both elbows is based on the objective findings.

Examination of the elbows shows a positive Tinel's sign bilaterally over the medial epicondyle. On goniometry in the examination room there appeared to be full range of motion of the elbows; however, measurements on goniometry were not recorded. On J-Tech Incliniometry there is some loss of motion of the left elbow, 3% upper extremity impairment for loss of flexion. For the abnormal sensations, pain during positive Tinel's testing, with clinical findings beneath the threshold of the electrodiagnostic studies for carpal tunnel syndrome there is Grade IV, 10% sensory deficit as per Table 16-10, multiplied by 7% with reference to Table 16-15 resulting in 0.7 rounded to 1% upper extremity impairment. Combining the 3% for loss of motion and 1% for the sensory deficit results in 4% upper extremity impairment, converting to 2% whole person impairment for the left elbow.

For the right elbow there is loss of flexion for which there is 5% upper extremity impairment. For the abnormal sensations and pain during positive Tinel's testing, with clinical findings beneath the threshold of the electrodiagnostic studies for cubital tunnel syndrome, there is Grade IV, 10% sensory deficit as per Table 16-10, multiplied by 7% with reference to Table 16-15 resulting in 0.7 rounded to 1% upper extremity impairment. Combining the 5% for loss of motion and 1% for loss of sensation results in 6% upper extremity impairment, converting to 4% whole person impairment for the right elbow.

Future medical care for both elbows should include a regular home exercise program and over-the-counter analgesic and non-steroidal anti-inflammatory medications as needed for symptomatic relief. For significant flare-ups can return to treating physician for appropriate prescription medications, splinting/bracing, and local cortisone injections. Based on the electrodiagnostic study findings, there is no basis for carpal tunnel release surgery at this time; however, should the elbow cubital tunnel condition deteriorate, and updated electrodiagnostic studies demonstrate significant cubital tunnel syndrome, at that point, cubital tunnel release surgical procedures would be indicated, along with appropriate post-operative physical/occupational therapy.

There is a history of upper extremity injury at work in the past; however, the Qualified Medical Evaluator on [REDACTED] has found [REDACTED] to have 0% whole person impairment relating to the upper extremities. Should a subsequent bilateral elbow continuous trauma claim be filed, I would be inclined to apportion 100% of the impairment of both elbows to continuous trauma resulting from [REDACTED] work activities subsequent to [REDACTED].

There are complaints of pain in both wrists/hands, with numbness in the right fifth finger, tingling in the right thumb and in the third and fourth fingers of the right hand as well as numbness in the fourth and fifth fingers of the left hand. Phalen's testing is negative bilaterally. There is no clear-cut decrease in sensation in the median and ulnar nerve or radial nerve distributions at the hands and wrists bilaterally, other than altered sensation on positive Tinel's testing at the median nerve bilaterally. There is no intrinsic muscle atrophy bilaterally. There is no loss of motion of the wrists. On examination of the wrists/hands there is a positive Tinel's sign at the carpal tunnel bilaterally, supportive of bilaterally carpal tunnel syndrome clinically. However as the EMG and nerve conduction studies do not provide electrodiagnostic confirmation of this at this point there is no indication for carpal tunnel release surgery.

The bilateral wrists/hands carpal tunnel conditions have reached maximum medical improvement as of the date of examination in my office.

Subjective factors for both wrists/hands are characterized as intermittent minimal to slight discomfort that occasionally becomes slight and at times becomes slight to moderate.

Objective factors for both wrists/hands include the results of EMG and nerve conduction studies, and the findings on physical examination in this office.

[REDACTED] may continue working at full, unrestricted duty, with regard to both wrists/hands.

Whole person impairment for both wrists/hands is based on the objective findings. Range of motion of both wrists is unrestricted. Orthopedic testing of the bilateral wrists/hands is negative except for positive Tinel's sign over the carpal Tunnel bilaterally. For the abnormal sensations, pain during positive Tinel's testing, with clinical findings beneath the threshold of the electrodiagnostic studies for carpal tunnel syndrome there is Grade

[REDACTED]
[REDACTED]
Page 23

IV, 10% sensory deficit as per Table 16-10, multiplied by 39% with reference to Table 16-15, resulting in 3.9 rounded to 4% upper extremity impairment converting to 2% whole person impairment for the right wrist/hand and 2% whole person impairment for the left wrist/hand.

Future medical care for both wrists/hands should include a regular home exercise program and over-the-counter analgesic and non-steroidal anti-inflammatory medications as needed for symptomatic relief. For significant flare-ups [REDACTED] can return to [REDACTED] treating physician for appropriate prescription medications, splinting/bracing, and local cortisone injections. Should the bilateral wrist/hand carpal tunnel syndrome conditions deteriorate and fail to respond to additional conservative treatment, and updated electrophysiologic studies show positive findings supportive of carpal tunnel syndrome electrophysiologically, carpal tunnel release surgical procedures would be appropriate at that time, followed by appropriate courses of post-operative physical therapy.

There previously was an injury involving the upper extremities on a work related basis that resulted in 0% whole person impairment as per the Qualified Medical Evaluation Report by [REDACTED] dated [REDACTED]. Should a continuous trauma claim be filed referable to bilateral wrist/hand carpal tunnel syndrome subsequent to that date, I would be inclined to apportion 100% of the bilateral wrist/hand impairment to continuous trauma while employed as a [REDACTED] for the [REDACTED].

[REDACTED] has had appropriate periods of temporary total disability when [REDACTED] was placed off work for the work related injury, and an appropriate period of temporary partial disability when [REDACTED] was working with restrictions, subsequent to the work related injury reported on [REDACTED] and this would relate to a continuous trauma claim subsequent to [REDACTED] when it is filed.

Referable to [REDACTED] complaints of feeling stressed due to [REDACTED] physical condition and inability to function as before, and difficulties sleeping, comment is deferred to the appropriate psychiatrist/psychologist.

Additional records that may be provided will be reviewed and commented upon in a supplemental report.

DISCLOSURE:

This report, as well as all other reports which I have submitted (if any), is not to be construed as a complete physical examination or recommendations for general healthcare purposes. These reports are being submitted pursuant to the patient's claim(s) for Workers' Compensation benefits for alleged orthopedic industrial injury/injuries, and are submitted in compliance with the Workers' Compensation Laws of the State of California. They are submitted/intended to address the issues required by the California Labor Code in Workers' Compensation claims, and involve those symptoms which the undersigned, as an orthopedic surgeon, believes have been involved in, or which may be related to, the injury/injuries alleged. Unrelated symptoms/conditions have not been assessed/addressed.

The history contained within may have been outlined by a historian, but was reviewed and elaborated upon with the patient by myself. All x-rays obtained in this office were reviewed by me. The physical examination was performed by myself. The opinions expressed herein are entirely my own.

DECLARATION

In compliance with recent Workers' Compensation legislation [Labor Code Section 4628 (j) and 5703 (a) (2)] and Insurance Code Section 556, I declare under penalty of perjury that I have not violated Labor Code Section 139.3 and that the information contained in this report and its attachments (if any), is true and correct to the best of my knowledge and belief, except as to information that I have indicated that I received from others. As to that information, I declare under penalty of perjury that the information accurately describes the information provided to me and, except as noted herein, that I believe it to be true. Furthermore, this evaluation is in compliance with the guidelines established by the Industrial Medical Council or Administrative Director pursuant to paragraph (5) of subdivision (3) of Labor Code Section 139.2 and 5307.6.

[REDACTED]
[REDACTED]
Page 25

If you have any further questions regarding this patient, please do not hesitate to contact me.

Date [REDACTED]

Signed _____
RICHARD C. ROSENBERG, M.D.

Dated and signed in [REDACTED]

[REDACTED]

SAMPLE REPORT # 2

[REDACTED]

[REDACTED]
[REDACTED]
[REDACTED]
[REDACTED]

[REDACTED]
[REDACTED]
[REDACTED]

ATTN: [REDACTED]

ATTN: [REDACTED]

RE: [REDACTED]

D/I: [REDACTED]

EMP: [REDACTED]

PT FILE #: [REDACTED]

D/E: [REDACTED]

CLAIM #: [REDACTED]

AGREED MEDICAL EVALUATION

The above-captioned patient is a [REDACTED]-year-old, right-handed [REDACTED] who was seen in my office on [REDACTED] for an **AGREED MEDICAL EVALUATION** of injuries which [REDACTED] associates with an accident that occurred at work.

EMPLOYMENT HISTORY:

[REDACTED] began [REDACTED] employment with the [REDACTED] on [REDACTED] as a [REDACTED]. [REDACTED] job duties include wearing a uniform and Sam Browne belt that held the gun, bullets, baton, pepper spray, handcuffs and a radio; altogether, the belt weighed approximately 15 pounds. [REDACTED] is required to wear a bulletproof vest that [REDACTED] estimates weighed 7-10 pounds. [REDACTED] patrols a given jurisdiction, which sometimes requires [REDACTED] to issue citations, arrest suspects, and administer field sobriety tests. [REDACTED] participates in qualification exercises for use of firearms, as well as martial arts training, and maintaining physical fitness through weight training and cardiovascular exercise. [REDACTED] drives a [REDACTED] car.

[REDACTED]
Page 2

The physical requirements of [REDACTED] job duties consist of prolonged driving, frequently entering and exiting a vehicle, alternating sitting, standing and walking; regularly climbing stairs, climbing fences, jumping, running, entering private residences and buildings, occasionally moving furniture, using weapons and firearms, using self-defense techniques, restraining aggressive persons, and involvement in physical altercations. [REDACTED] work also requires frequently bending at the knees and waist, twisting and turning at the waist, stooping, squatting and kneeling, sometimes pushing the weight of a vehicle (varies), pushing and pulling the weight of a person (varies), reaching, overhead reaching, repetitive arm and hand movement, simple and forceful grasping, torquing motions and fine finger manipulation. [REDACTED] is frequently exposed to needles, drug paraphernalia, broken glass, vapors, fumes, structural fires, gasoline and diesel fumes, and hazardous chemicals.

[REDACTED] lifts over fifty pounds.

[REDACTED] works twelve hours per day, three to four days per week.

[REDACTED] is currently working on regular duties.

CONCURRENT EMPLOYMENT:

[REDACTED] denies concurrent employment.

SUBSEQUENT EMPLOYMENT:

[REDACTED] denies subsequent employment.

PRIOR EMPLOYMENT:

The patient has worked for C [REDACTED] for [REDACTED] years.

Page 3

HISTORY OF INJURY:

██████████ indicates that on ██████████ was involved in a motor vehicle accident while on patrol duty. ██████████ was the passenger and the other car hit ██████████ side. ██████████ was able to get out of the car on ██████████ own. ██████████ experienced immediate pain in ██████████ neck, right shoulder, hand, bilateral knees and back.

The paramedics were summoned and ██████████ was transported via ambulance to ██████████. X-rays were obtained, the results of which revealed right hand fractures, which was placed in a soft cast.

██████████ was placed on temporary total disability.

Approximately two to three days later, ██████████ was referred to ██████████ Clinic to address ██████████ right shoulder and right hand. ██████████ received treatment with medications, ██████████ was started on a course of physical therapy, and ██████████ right hand was placed in a hard cast. ██████████ states that ██████████ has not fully recovered and continues to experience soreness, occasional numbness and tingling sensations.

██████████ right shoulder was treated with physical therapy and cortisone injections, with partial benefit noted. The pain levels have greatly improved; however, ██████████ continues to experience weakness.

In ██████████ ██████████ returned to work on modified duties for two weeks, after which ██████████ resumed working regular duties.

The patient's last appointment was in ██████████, and was released from medical care.

██████████ was referred to ██████████ to address ██████████ neck, back and bilateral knees symptoms. ██████████ received treatment with medications and physical therapy directed to all the injured body parts, with partial and temporary benefit noted.

██████████ also received cortisone injections with minimal benefit noted. ██████████ has not fully recovered and continues to experience pain.

The patient last appointment was on ██████████, and ██████████ was released from medical care.

[REDACTED]
[REDACTED]
Page 4

PRE-POST CAPACITY FOR LIFTING:

Prior to this claim, [REDACTED] states that [REDACTED] was able to lift and carry approximately 75 pounds comfortably. Presently, [REDACTED] is able to lift and carry approximately five to seven pounds comfortably.

PAST MEDICAL HISTORY:

[REDACTED] had a history of hypertension and hyperlipidemia which subsided when [REDACTED] lost weight five years ago. [REDACTED] has no known history of heart disease, diabetes, lung disease, cancer, arthritis, fibromyalgia, and osteoporosis or blood disorders.

The patient states that throughout [REDACTED] career with the [REDACTED] department, [REDACTED] has been involved in several minor motor vehicle accidents; however, [REDACTED] did not sustain any injuries.

In [REDACTED], while working for the same employer, the patient sustained injuries to [REDACTED] left knee, which were treated surgically. [REDACTED] states that [REDACTED] fully recovered. [REDACTED] closed the case and received a financial settlement.

The patient has undergone [REDACTED] in [REDACTED]. [REDACTED] also underwent a [REDACTED] and the [REDACTED] from [REDACTED] in [REDACTED]. In [REDACTED] underwent left knee surgery.

SOCIAL/RECREATIONAL HISTORY:

[REDACTED] and has [REDACTED] children.

[REDACTED] denies having any problems bathing and dressing.

[REDACTED] denies any problems with doing household activities.

[REDACTED] denies having problems with driving; however, when turning to look to the sides or back the pain in [REDACTED] neck increases.

[REDACTED] denies having problems sleeping.

[REDACTED]
[REDACTED]
Page 5

[REDACTED] feels stressed due to [REDACTED] physical condition and the inability to function as before.

EXTRA CURRICULAR ACTIVITIES:

[REDACTED] states that [REDACTED] still goes to the gym and exercises to keep up with the required physical activities; [REDACTED] has increased pain when running and lifting weights.

ALLERGIES & MEDICATIONS:

[REDACTED] has is allergic to [REDACTED]

The patient takes [REDACTED] and a prescribed medication for thyroid disease.

PRESENT COMPLAINTS:

NECK: The patient complains of constant neck pain, radiating to [REDACTED] head, causing [REDACTED] headaches. [REDACTED] also complains of stiffness, numbness, as well as clicking, grinding and popping sensations. The pain increases when turning [REDACTED] head from side-to-side, when looking towards the back, with flexion and extension, driving and prolonged positioning.

RIGHT SHOULDER: The patient complains of constant right shoulder pain, radiating throughout [REDACTED] right arm. [REDACTED] also complains of limited range of motion, occasional tingling, and weakness, as well as clicking, grinding and popping sensations. The pain increases with lifting and carrying over five to ten pounds, reaching overhead, pushing and pulling.

RIGHT HAND: The patient complains of frequent right hand pain, radiating to [REDACTED] fingers. [REDACTED] also complains of seldom numbness and occasional tingling sensations. The pain increases with lifting and carrying over five to ten pounds, and when [REDACTED] arm is hanging to the side. [REDACTED] has difficulty opening and closing jars and bottles.

LOW BACK: The patient complains of frequent low back pain, radiating to the left side of [REDACTED] mid back. [REDACTED] also complains of spasms. The pain increases with prolonged sitting, standing, walking for longer than twenty minutes.

BILATERAL KNEES: The patient complains of constant right and left knee pain, which is localized and more intense in right knee. also complains of sensitivity to touch, swelling, as well as clicking, grinding and popping sensations. The pain increases with prolonged squatting and sitting for longer than twenty minutes and ascending or descending stairs.

PHYSICAL EXAMINATION:

Weight pounds. Height:
 Blood Pressure:

For range of motion measurements, please see Range of Motion Incliniometry report attached.

is an alert, well nourished

Examination of the cervical spine shows tenderness in the suboccipital region and upper paracervical area. There is muscle spasm with deep palpation. There is no guarding. There is a negative foraminal compression test and a negative Spurling's sign.

Comprehensive motor examination of the upper extremities including the shoulder abductors, flexors and extensors, the wrist flexors and extensors, the forearm supinators and pronators, the finger extensors, flexors and intrinsic muscles shows 5+/5+ motor power bilaterally.

Reflexes	Right	Left
Biceps jerks	2+	2+
Triceps jerks	2+	2+
Brachioradialis	2+	2+

Comprehensive sensory examination of the upper extremities shows a normal dermatomal pattern to pinprick and deep touch.

There is no scapulothoracic crepitus or pain. There is no winging of the scapulae.

Examination of the right shoulder shows diffuse anterior and posterior subacromial tenderness. There is a negative Neer and a negative Hawkins impingement sign. There is good strength of the abductors of the shoulder. There is a negative O'Driscoll's sign.

Page 7

Examination of the right hand shows mild tenderness over the shaft of the 5th metacarpal. There is full range of motion of all of the fingers. There is no deformity of the hand. There is a negative Tinel's sign over carpal tunnel and over Guyon's canal. Sensation is normal in the distribution of the radial, ulnar and median nerves. There is no intrinsic muscle atrophy.

Upper extremity measurements:

Major Hand: Right

Circumferences:	Right	Left
Biceps at greatest circumference	26 cm	27 cm
Elbow	23.5 cm	24 cm
Forearm (2" below elbow)	23 cm	23 cm
Wrist	15 cm	15.25 cm
Hand	20 cm	19 cm

Grip strength:

Jamar Dynamometer Readings

Right	Left
14 kg	24 kg
16 "	25 "
14 "	21 "

Examination of the lumbar spine shows mild paralumbar tenderness without spasm. There is no guarding with range of motion. There is no tenderness along the sacroiliac joints or the path of the sciatic nerve. The straight leg raising sign is negative bilaterally.

Comprehensive motor examination of the lower extremities including extensor hallucis longus, anterior tibialis, gastrocsoleus, peroneus longus and brevis shows 5+/5+ motor power bilaterally.

Page 8

Reflexes	Right	Left
Knee jerks	2+	2+
Ankle jerks	2+	2+
Plantar response	Downward bilaterally	

Comprehensive sensory examination of the lower extremities shows a normal dermatomal pattern to pinprick and deep touch.

Examination of the knees shows tenderness bilaterally over the pes bursa. There is full range of motion of both knees. There is no lateral or medial joint line tenderness, bilaterally. There is no effusion of either knee. There is no retropatellar crepitus or pain. There is no ligamentous instability detected. There is a negative Lachman's test and a negative McMurray's sign.

Lower extremity measurements:

Circumferences	Right	Left
Mid-foot	23.5 cm	22.5 cm
Ankles (on the malleolus)	23 cm	25 cm
Ankles (smallest circ)	19.5 cm	20 cm
Calves (largest circ)	35.5 cm	36 cm
Knees (on the patella)	39 cm	38 cm
Thighs (mid-thigh - 1/3 of distance between upper pole of patella and umbilicus)	44 cm	42.5 cm
Leg lengths:	Right	Left
Anterior superior spine to tip of malleolus (actual)	82.5 cm	82.5 cm

X-RAYS:

I will review the x-rays.

Page 9

REVIEW OF RECORDS:

A Return to Work slip dated [REDACTED] by [REDACTED] indicates [REDACTED] was treated in the emergency department at [REDACTED] Center on [REDACTED]. It was noted that [REDACTED] may return to work on [REDACTED] with no use of the affected extremity and was to follow-up and wear a splint until seen for follow-up.

A Treatment Disability slip from [REDACTED], dated [REDACTED] indicates the diagnosis was fracture, right hand. Treatment included initial exam, consultation, splint/brace and x-rays. [REDACTED] was on temporary total disability until the next visit. It was noted that [REDACTED] will continue as the Secondary Treating Physician.

An Initial Orthopedic Hand Surgeon Evaluation Report by [REDACTED], dated [REDACTED] indicates the date of injury was [REDACTED] and the employer is [REDACTED] was in a motor vehicle accident on [REDACTED] injuring [REDACTED] right hand, when [REDACTED] was a passenger in a vehicle that was hit by another car. [REDACTED] was seen in the emergency room and given a splint. Three views of the right hand revealed evidence of a spinal non-displaced fracture of the fifth metacarpal. The plan was for ulnar gutter cast, and return in two weeks for repeat x-rays. [REDACTED] was temporarily totally disabled.

A Progress Report from [REDACTED] dated [REDACTED] indicates x-rays of the right hand showed no change in the appearance of a fracture, and overall alignment is satisfactory. Impression: 2 ½ week old fifth metacarpal shaft fracture, healing well, right hand. [REDACTED] was to receive a short arm cast so [REDACTED] may start moving the right fifth MP joint and get better motion from the small finger. [REDACTED] was to return in about three weeks for cast removal and repeat x-rays. [REDACTED] is temporarily totally disabled.

A Progress Report from [REDACTED] dated [REDACTED] indicates radiographs of the right hand showed the fracture to be healing very well, in good alignment. [REDACTED] was to have a right fifth metacarpal brace made by the occupational therapist and was to start occupational therapy twice a week for six weeks. [REDACTED] was to return in four weeks for x-rays of the right hand.

A Progress Report from [REDACTED], dated [REDACTED] indicates [REDACTED] had been seen by [REDACTED] and a brace had been recommended for [REDACTED] right hand. It was also noted that [REDACTED] had right shoulder and bilateral knee pain. [REDACTED] reported that [REDACTED] had

██████████
████████████████████
Page 10

injured █████ back, neck, bilateral knees, right shoulder as well as right hand during the accident. █████ was seen at █████ by █████. At that time █████ was seen for consultation and evaluation regarding the bilateral knees and right shoulder. An MRI of the right knee on █████ shows evidence of medial meniscus tear with a small leaking ruptured Baker's cyst and edema in the prepatellar bursa of the right knee. The consultation of █████ dated █████ is reviewed indicating █████ had been diagnosed with healing spiral fracture of the fifth metacarpal of the right hand. Assessment: history of motor vehicle accident on █████ while employed by the █████ spiral fracture of █████ right hand fifth metacarpal, currently being treated by █████; right shoulder rule out rotator cuff tear; medial meniscal tear of the right knee confirmed by MRI studies; bilateral knee pain. Recommendation is for a course of physical therapy and anti-inflammatories as conservative measures for the bilateral knees. For the right shoulder █████ requires an MRI scan. █████ was currently temporarily totally disabled for six weeks.

A Permanent and Stationary Report by █████ dated █████ indicates radiographs, three views, of the right hand show the fracture appears to have healed very well. Impression: well-healed right fifth metacarpal shaft fracture. █████ has reached the point of maximum medical improvement and is made permanent and stationary. █████ may resume regular duties with regard to █████ right hand only. █████ has 0% hand upper extremity impairment. No future medical care is anticipated. There are no factors of apportionment.

A Progress Report by █████ dated █████ indicates the MRI of the right shoulder on █████ indicated acromioclavicular joint osteoarthritis, bursitis and moderate tenderness over the supraspinatus tendon without evidence of rotator cuff tear or retraction. █████ stated that the right shoulder is more symptomatic than the right knee. Assessment: History of motor vehicle accident on █████ while employed by █████ Prior fracture of the right fifth metacarpal which was treated by █████, who declared █████ permanent and stationary. Medial meniscus tear of the right knee confirmed by MRI studies from █████ in █████ MRI studies from █████ for █████ right shoulder in █████ indicating rotator cuff tendonitis without evidence of tear. Status post Kenalog injection of the right shoulder in subacromial space on █████ Recommendation was for a Kenalog injection to the right shoulder and 12 sessions of physical therapy for the right shoulder. █████ was temporarily totally disabled and will be released to regular duty on █████

Page 11

A Primary Treating Physician's Progress Report by [REDACTED], dated [REDACTED] notes the date of injury is [REDACTED]. [REDACTED] returned for re-evaluation of [REDACTED] neck, low back and bilateral knees. [REDACTED] completed physical therapy for her knees and low back and was discharged to a home exercise program, which [REDACTED] was doing 5 days a week. [REDACTED] was still having residual ache and neck pain, slight residual achiness of the left lateral lumbar region, and still fluctuating knee pain. Diagnosis: Bilateral knee conditions; right knee effusion; bilateral pes anserine bursitis; right knee medial meniscus tear. There is mild to moderate femoral condyle articular cartilage fissuring. Mild to moderate degenerative changes at the medial compartment of the right knee. The femoral compartment demonstrates an 8mm chondral defect to the apex with small flap tear of the lateral patellar facet cartilage. There is mild prepatellar edema without discrete bursal fluid collection. Left knee status post ACL reconstruction, stable. Acute thoracic and lumbar strain. L5-S1 spondylitic spondylolisthesis. The treatment was plan was for continued home exercise program, bilateral Genutrain braces pending authorization. [REDACTED] was to resume her usual and customary work.

A Permanent and Stationary Report by [REDACTED] dated [REDACTED] indicates [REDACTED] stated the subacromial injection to the right shoulder had been beneficial. [REDACTED] felt much improved, and with regard to the right knee [REDACTED] indicated [REDACTED] was able to control [REDACTED] symptoms. [REDACTED] was considered to have reached maximum medical improvement and was declared permanent and stationary. Subjective and objective factors were listed, and [REDACTED] was to continue working unrestricted. Future medical care was addressed, along with diagnostic and operative arthroscopy of the right knee, analgesics and anti-inflammatories. [REDACTED] was to have potential injections with physical therapy for the right shoulder, and also was a candidate for arthroscopy.

For the left knee pain, right shoulder pain and right knee pain [REDACTED] has 3% whole person impairment due to Almaraz/Guzman decision.

A Primary Treating Physician's Progress Report by [REDACTED] dated [REDACTED] indicates [REDACTED] was re-evaluated for [REDACTED] neck, low back and bilateral knees. [REDACTED] was last seen on [REDACTED]. The plan was for a continued home exercise program, and MRI of the left knee, and possible Hyaluronic acid injections to both knees pending left knee MRI results. [REDACTED] was to continue with [REDACTED] usual and customary work.

[REDACTED]
[REDACTED]
Page 12

DIAGNOSES:

1. Cervical strain.
2. Right shoulder tendonitis, bursitis, acromioclavicular joint osteoarthritis.
3. Right fifth metacarpal shaft fracture, healed, with residual discomfort.
4. Lumbar strain, essentially subsided.
5. Right knee sprain; medial meniscus tear per records.
6. Status post left knee anterior cruciate ligament reconstruction, [REDACTED], per records, with residual left thigh atrophy.
7. Left knee sprain.

DISCUSSION:

[REDACTED] presents for evaluation of complaints relating to [REDACTED] neck, right shoulder, right hand, low back and both knees, which [REDACTED] relates to an injury at work on [REDACTED] [REDACTED] during the course of [REDACTED] employment as a [REDACTED] with the [REDACTED]
[REDACTED]

[REDACTED] states that [REDACTED] was working on [REDACTED] and was a passenger in a car while on patrol duty when that car was hit on [REDACTED] side and [REDACTED] experienced immediate pain in [REDACTED] neck, right shoulder, right hand, back, and bilateral knees. Paramedics transported [REDACTED] by ambulance to [REDACTED] Hospital where x-rays were obtained that revealed a right hand fracture that was placed in a cast. [REDACTED] was placed on temporary total disability.

[REDACTED] subsequently received treatment at [REDACTED] [REDACTED] referable to [REDACTED] right shoulder and right hand. [REDACTED] received treatment that included a cast, initially, and subsequently physical therapy for the right hand. [REDACTED] also received physical therapy and cortisone injections to the right shoulder.

[REDACTED]
[REDACTED]
Page 13

[REDACTED] was referred to [REDACTED] referable to [REDACTED] neck, back and bilateral knee symptoms. [REDACTED] received treatment that included cortisone injections, medications and physical therapy.

[REDACTED] describes having been released from medical care by [REDACTED]

[REDACTED] reports a past medical history of having sustained injury to [REDACTED] left knee in [REDACTED] while working for the same employer, for which [REDACTED] received surgical treatment. [REDACTED] states that [REDACTED] case was closed and [REDACTED] received a financial settlement for that injury.

At the present time [REDACTED] reports neck pain that increases with some activities.

On examination of the cervical spine there is tenderness in the suboccipital region and upper cervical area, with muscle spasm to deep palpation. Spurling's sign is negative, as is foraminal compression test, and motor, sensory and reflex examinations of the upper extremities are all unremarkable, ruling out cervical radiculopathy clinically. The neck is stable and requires no treatment at this time.

The cervical spine has reached maximum medical improvement and can be considered permanent and stationary as of the date of this report.

The subjective factors for the cervical spine are characterized as frequent minimal to slight discomfort that intermittently increases to slight pain.

Objective factors for the cervical spine include the findings on physical examination in this office.

Whole person impairment for the cervical spine is based on the objective findings. There is slight loss of motion of the cervical spine on J-Tech Inclinometry; however, variation is rather high, greater than 20% on some planes of motion, suggesting those measurements are not accurate for rating purposes. There is tenderness in the suboccipital region and upper cervical area, with muscle spasm on palpation. The objective factors are consistent with DRE Cervical Category II, 5% whole person impairment.

[REDACTED] complains of right shoulder pain that increases with some activities.

[REDACTED]
[REDACTED]
Page 14

Examination of the right shoulder shows diffuse anterior and posterior subacromial tenderness. Impingement signs are negative at the right shoulder. There is good strength of the abductors of the right shoulder. There is some loss of motion of the right shoulder in comparison to the left shoulder. The records suggest there was tenderness of the rotator cuff of the right shoulder, with bursitis, and also acromioclavicular joint osteoarthritis, but no evidence of rotator cuff tear.

The right shoulder has reached maximum medical improvement and can be considered permanent and stationary when so determined by the treating physician on [REDACTED]

Subjective factors for the right shoulder are characterized as frequent minimal to slight discomfort that intermittently increases to slight pain.

Objective factors for the right shoulder include the results of the findings on physical examination in my office and MRI findings. According to the records, the MRI of the right shoulder on [REDACTED] indicated acromioclavicular joint osteoarthritis and bursitis, and moderate tendonitis over the supraspinatus tendon without evidence of rotator cuff tear or retraction.

Whole person impairment for the right shoulder is based on the objective findings. There is loss of motion of the right shoulder, 3% upper extremity impairment for loss of flexion, 2% for extension, 5% for abduction and 1% for internal rotation totaling 11% upper extremity impairment. There is also loss of motion of the uninjured, asymptomatic left shoulder, totaling 5% upper extremity impairment. Subtracting the 5% from the 11% for the right shoulder results in 6% upper extremity impairment, converting to 4% whole person impairment for the right shoulder.

Future medical care for the right shoulder should include a regular home exercise program and over-the-counter analgesic and non-steroidal anti-inflammatory medications as needed for symptomatic relief. For significant flare-ups [REDACTED] can return to [REDACTED] treating physician for appropriate prescription medications and local cortisone injections.

There is no history of any prior or subsequent injury to the right shoulder. Based on the information available to me, I would apportion 100% of the right shoulder impairment to the [REDACTED] work injury.

[REDACTED] also describes pain in the right hand that increases with a number of activities.

██████████
████████████████████
Page 15

Examination of the right wrist/hand reveals mild tenderness over the shaft of the fifth metacarpal. Otherwise examination of the right hand is unremarkable. There is some loss of motion of the right wrist.

After reviewing the available records, and examining the right hand, my impression is that ██████ has a right fifth metacarpal shaft fracture that has healed, with residual discomfort on some activities.

The right hand has reached maximum medical improvement at this time.

The subjective factors for the right hand are characterized as frequent minimal discomfort that intermittently to occasionally increases to slight discomfort.

The objective factors include the x-rays demonstrating a spiral non-displaced fracture of the fifth metacarpal, the subsequent x-rays demonstrating healing of the fracture, and the findings on physical examination in this office.

Whole person impairment for the right hand is based on the reliable objective findings. There is decreased grip strength on the right, compared to the left. There is a painful condition in the right hand with tenderness over the shaft of the fifth metacarpal, and there is loss of range of motion of the right wrist, indicating grip strength measurements cannot be rated, according to page 508 of the AMA Guides. The right hand actually measures 1cm greater than the left hand, and there is no atrophy of the right forearm, in comparison to the left forearm, indicating ██████ has been using the right hand as much, if not more than the left hand, indicating grip strength measurements are not supported by the truly objective findings. There is loss of motion of the right wrist, for which there is 2% upper extremity impairment for loss of extension, converting to 1% whole person impairment for the right hand/wrist. There is no history of any prior or subsequent injury to the right hand/wrist. Based on the information available to me, I would apportion 100% of the right wrist/hand impairment to the work related injury on ████████████████████.

The right wrist/hand reached maximum medical improvement when so determined by ██████ on ████████████████████ however there were no range of motion measurements at that time.

[REDACTED]
[REDACTED]
Page 16

Future medical care for the right hand/wrist should include a regular home exercise program and over-the-counter analgesic and non-steroidal anti-inflammatory medications as needed for symptomatic relief.

[REDACTED] also reports low back pain. [REDACTED] states the pain extends into the left side of [REDACTED] mid back.

On examination of the thoracic and lumbar spine there is mild paralumbar tenderness, without spasm. There is no muscle guarding with range of motion. There is no tenderness along sacroiliac joints or along the path of the sciatic nerve. Straight leg raising sign is negative bilaterally, and motor, sensory and reflex examinations of the lower extremities are all unremarkable, ruling out lumbar radiculopathy clinically.

The lumbar spine is stable and has reached maximum medical improvement as of the date of examination in this office.

The objective factors are consistent with DRE Lumbar Category I, 0% whole person impairment.

There are complaints of bilateral knee pain that increase with a number of activities.

Examination of both knees reveals tenderness over the pes bursa bilaterally. Range of motion of both knees appear to be good on goniometry in the examination room, however, goniometry measurements were not recorded. On J-Tech Incliniometry there is some loss of motion of both knees, and variation of the measurements is less than 20%, indicating the measurements are accurate for rating purposes with analogy to page 508 of the AMA Guides.

Both knees are stable and have reached maximum medical improvement as of the date [REDACTED] was determined to have reached permanent and stationary status by [REDACTED] treating physician [REDACTED]

Referring to Table A-3 on page 598, and Table 17-10 on page 537 of the AMA Guides, the right knee has flexion limited to 99 degrees indicating 4% whole person impairment.

For the left knee, flexion is limited to 112 degrees, and with interpolation of Table 17-10 there is 3% whole person impairment for the left knee.

██████████
████████████████████
Page 17

The available medical records indicate ██████ is status post left knee anterior cruciate ligament reconstruction, consistent with ██████ history of left knee surgery in ██████. Currently there is 1.5cm atrophy of the left thigh, which appears to relate to the post-operative left knee condition for which there is 2% whole person impairment with reference to Table 17-6. However, referring to Table 17-2, there is a 3% whole person impairment for the left knee.

There was mention of bilateral knee contusion by ██████; however, ██████ did not note any contusion of either the right knee or the left knee.

Future medical care for the bilateral knees should include a regular home exercise program and over-the-counter analgesic and non-steroidal anti-inflammatory medications as needed for symptomatic relief.

The records of ██████ and ██████ would suggest a significant amount of pathology in the right knee, based on the MRI findings. However, while ██████'s McMurray's testing was positive at the right knee, ██████ did not note positive McMurray's testing. While ██████ noted there was medial joint line tenderness at the right knee, ██████ felt there was tenderness at the medial joint line of not only the right knee but also the left knee. ██████ felt there were contusions to both knees, and ██████ noted no knee contusion. ██████ felt there was right knee effusion, and ██████ noted no knee effusion, nor any swelling or ecchymosis. There appears to have been some inconsistencies in the findings of the prior treating physicians. It would appear that the majority of the findings noted in the records are no longer present in the right knee, suggesting some interim improvement. Currently there are no confirmatory clinical findings to support medial meniscectomy to the right knee, and there is no basis for surgery to the right knee at the present time.

Should the right knee condition deteriorate and fail to respond to more conservative treatment, an MRI of the right knee at a reputable facility would be indicated, with treatment as may be indicated consistent with the clinical findings.

According to ██████ history ██████ underwent left knee surgery in ██████. As noted above, there is 1.5cm left thigh atrophy, which appears to be a residual of the prior left knee surgery. There may also have been some loss of motion associated with the underlying condition prior to the ██████ work related injury. Based on the information available to

[REDACTED]
[REDACTED]
Page 18

me, I would apportion 35% of the left knee impairment to the underlying, pre-existing condition that objectively supports the residuals of the prior surgery, including left thigh atrophy, and 65% of the left knee impairment is apportioned to the [REDACTED] work related injury that aggravated the underlying condition and caused the need for medical treatment on an industrial basis.

I would apportion 100% of the right knee impairment to the work related injury of [REDACTED] based on the information available to me.

[REDACTED] is currently working regular duty and [REDACTED] may continue working in this capacity.

Referable to [REDACTED] complaints of feeling stressed due to her physical condition and inability to function as before, comment is deferred to the appropriate psychiatrist/psychologist.

[REDACTED] has had an appropriate period of temporary total disability when [REDACTED] was off work after the [REDACTED] injury through [REDACTED] when [REDACTED] treating physician released [REDACTED] to return to work full duty on [REDACTED]

Should any additional records be provided I would be interested in reviewing them and providing comment in a supplemental report.

DISCLOSURE:

This report, as well as all other reports which I have submitted (if any), is not to be construed as a complete physical examination or recommendations for general healthcare purposes. These reports are being submitted pursuant to the patient's claim(s) for Workers' Compensation benefits for alleged orthopedic industrial injury/injuries, and are submitted in compliance with the Workers' Compensation Laws of the State of California. They are submitted/intended to address the issues required by the California Labor Code in Workers' Compensation claims, and involve those symptoms which the undersigned, as an orthopedic surgeon, believes have been involved in, or which may be related to, the injury/injuries alleged. Unrelated symptoms/conditions have not been assessed/addressed.

The history contained within may have been outlined by a historian, but was reviewed and elaborated upon with the patient by myself. All x-rays obtained in this office were

[REDACTED]
[REDACTED]
Page 19

reviewed by me. The physical examination was performed by myself. The opinions expressed herein are entirely my own.

DECLARATION

In compliance with recent Workers' Compensation legislation [Labor Code Section 4628 (j) and 5703 (a) (2)] and Insurance Code Section 556, I declare under penalty of perjury that I have not violated Labor Code Section 139.3 and that the information contained in this report and its attachments (if any), is true and correct to the best of my knowledge and belief, except as to information that I have indicated that I received from others. As to that information, I declare under penalty of perjury that the information accurately describes the information provided to me and, except as noted herein, that I believe it to be true. Furthermore, this evaluation is in compliance with the guidelines established by the Industrial Medical Council or Administrative Director pursuant to paragraph (5) of subdivision (3) of Labor Code Section 139.2 and 5307.6.

If you have any further questions regarding this patient, please do not hesitate to contact me.

Date [REDACTED]

Signed _____
RICHARD C. ROSENBERG, M.D.

Dated and signed in [REDACTED]

[REDACTED]



September 20, 2016

TO: Each Member
Board of Retirement

FROM: Disability Procedures & Services Committee
Vivian H. Gray, Chair
William de la Garza, Vice Chair
Yves Chery
Les Robbins
David Muir, Alternate

FOR: October 5, 2016 Board of Retirement Meeting

SUBJECT: **CONSIDER APPLICATION(S) FOR LACERA PANEL OF EXAMINING PHYSICIAN(S)**

On July 6, 2016, the Disability Procedures & Services Committee reviewed the attached application for the LACERA Panel of Examining Physicians.

The application package has been reviewed by the Committee. After discussion, the Committee voted to accept the application of the following physician and submit to the Board of Retirement for approval to the LACERA panel.

IT IS THEREFORE RECOMMENDED THAT the Board approve the following physician to the LACERA Panel of Physicians for the purpose of examining disability retirement applicants.


Michael M. Bronshvag, M.D. - Board Certified Internist/Neurologist

Attachments

VG:RC/mb

June 20, 2016

TO: Disability Procedures & Services Committee
Vivian H. Gray, Chair
William de la Garza, Vice Chair
Yves Chery
Les Robbins
David Muir, Alternate

FROM: Ricki Contreras, Manager 
Disability Retirement Services

FOR: July 6, 2016, Disability Procedures and Services Committee Meeting

SUBJECT: **CONSIDER APPLICATION OF INTERNIST/NEUROLOGIST,
MICHAEL M. BRONSHVAG, M.D., AS A LACERA PANEL PHYSICIAN**

On June 7, 2016, Debbie Semnanian interviewed Michael M. Bronshvag, M.D., a physician seeking appointment to the LACERA Panel of Examining Physicians.

Attached for your review and consideration are:


- Staff's Interview Summary and Recommendation
- Panel Physician Application
- Curriculum Vitae
- Sample Report(s).

IT IS THEREFORE RECOMMENDED THAT THE COMMITTEE accept the staff recommendation to submit the application of Michael M. Bronshvag, M.D., to the Board of Retirement for approval to the LACERA Panel of Examining Physicians.

Attachments

JJ:RC/mb

NOTED AND REVIEWED:



JJ Popowich, Assistant Executive Officer

Date: 6/24/16



June 21, 2016

TO: **Ricki Contreras, Manager**
Disability Retirement Services

FROM: **Debbie Semnanian** 
Disability Retirement Specialist Supervisor

Debbie Semnanian, WCCP
Supervising Disability Retirement Specialist

SUBJECT: **INTERVIEW OF INTERNIST/NEUROLOGIST APPLYING FOR
LACERA'S PHYSICIAN'S PANEL**

On June 7, 2016, I interviewed **Michael M. Bronshvag, M.D.** at his office location at 15350 Sherman Way, Suite 250, Van Nuys, CA 91406. The office space is located in a well-maintained five-story building with patient paid parking on the ground floor of the building.

Dr. Bronshvag is Board Certified in both internal medicine and neurology, and has been in private practice for forty years. Dr. Bronshvag's office has three examination rooms. He estimates that 5 percent of his practice is devoted to patient treatment, while the other 95 percent of his time is devoted to IME evaluations for other retirement systems and for QTC (Quality Timely Cost-Effective Medical Examinations – a private provider of government occupational health and disability examination services) for federal issues.

As referenced in his Curriculum Vitae, Dr. Bronshvag graduated from Columbia University College of Physicians and Surgeons in New York, with his Medical Degree in 1964. He completed a residency in internal medicine at Northwestern University Medical Center, and a residency in neurology at Letterman General Hospital in San Francisco. Dr. Bronshvag served in the U.S. Army, where he held the position of US-IRR (Colonel) from 1987-1996, and retired in 2000. Dr. Bronshvag advised staff that, throughout his practice, fifty percent of his examinations have been for patients with internal conditions and 50% for patients with neurologic conditions.

The office was clean with ample seating. A handicap accessible restroom is located within the office. There is a staff of two office personnel.

Staff reviewed the LACERA Disability Retirement procedures and expectations in its evaluation of County Employees applying for both service connected and non-service connected disability retirements. The importance of preparing impartial and non-discriminatory reports that are clear and concise and address issues of

causation and incapacity were discussed with the doctor. He understood that he would adhere strictly to the HIPAA laws that would also apply for LACERA reports. Staff reviewed with Dr. Bronshvag the Panel Physician Guidelines for evaluating LACERA applicants and defined the relationship between workers' compensation and disability retirement. Staff discussed the need to rely on his own objective and subjective findings rather than the opinions of previous physician reports and/or comments.

Dr. Bronshvag agreed to adhere to LACERA's standard of having his evaluation reports sent to us within 30 days of examination. Staff confirmed that Dr. Bronshvag is agreeable with accepting payment pursuant to LACERA's contract and billing procedures. Dr. Bronshvag was informed that if he is approved by the Board to be on our panel of physicians, he is required to contact the specialist assigned to the case for approval of any special tests or extraordinary charges. He has also been advised of the requirement to immediately notify LACERA if any license, Board certification, or insurance coverage is lapsed, suspended or revoked. He was informed that a Quality Control Questionnaire is sent to each applicant regarding their visit.


RECOMMENDATION

Based on our interview and the need for his specialties, staff recommends Dr. Bronshvag's application be presented to the Board for approval as a LACERA Panel Physician.

**INFORMATION ONLY**

September 21, 2016

TO: Each Member
Board of Retirement

FROM: Ricki Contreras, Division Manager 
Disability Retirement Services

FOR: October 5, 2016 Board of Retirement Meeting

SUBJECT: Supplemental Memo Considering Application of Internist/Neurologist,
Michael M. Bronshvag, M.D., as a LACERA Panel Physician

EXECUTIVE SUMMARY

On July 6, 2016, the Disability Procedures & Services Committee reviewed the attached application package for the LACERA Panel of Examining Physicians. After discussion, the Committee voted to accept the application of internist/neurologist Michael M. Bronshvag, M.D. and submit Dr. Bronshvag to the Board of Retirement for approval to the LACERA panel.

On July 7, 2016, as Disability Retirement Staff was preparing the documents for the August 3, 2016 Board of Retirement meeting, it was discovered that Dr. Bronshvag included a page with his patient's name that appeared to be unintentionally inserted into the middle of an article the doctor provided as a reference to one of his sample reports. This page was part of the original memo provided to the Board of Retirement's Disability Procedures & Services Committee on July 6, 2016 and was posted online for a period of 7 days.

Disability Retirement Services Staff immediately advised the Executive Office and a Privacy Incident Response Team was convened on July 11, 2016 to discuss LACERA's responsibility related to notifying the patient that his private health information may have been compromised. It was determined that as the patient was not a LACERA member, it would be the responsibility of the doctor to notify his patient of the occurrence. Additionally, it was determined LACERA would notify the doctor verbally and in writing and inquire about the overall security of the protected

health information maintained by Dr. Bronshvag, as well, as their office protocol for responding to potential privacy breaches. A copy of the doctor's July 22, 2016 written response is attached for your review and consideration.


DISCUSSION

Dr. Bronshvag has provided his assurances that he believes a privacy breach has not occurred and all reasonable measures are taken by his office to safeguard and protect patient information including adhering to industry best practices.

Protecting our member's private and protected health information is a key priority in Disability Retirement Services. Therefore, after careful review and consideration of the information provided by Dr. Bronshvag and due to the sensitive nature of the matter, staff felt it necessary to provide a supplemental report outlining the subsequent events which occurred after the July 6, 2016 Disability Procedures and Services Committee and recommend your Board consider this privacy incident as they consider the application for Dr. Bronshvag.

Staff believes it is important to advise the Board, that had this privacy incident been identified prior to the Disability Procedures and Services Committee's meeting, staff would have recommended the Committee reject the doctor's application. This recommendation is based on our belief that the initial application and related materials provided by a potential panel physician should represent the best work of the applicant who is applying for a position. Given the importance of our focus on protecting member information, and the fact these applications are meant to be a reasonable example of the applicant's performance, staff has determined that it would not be prudent to add Dr. Bronshvag to the LACERA Panel of Examining Physicians at this time.

REVIEWED AND APPROVED



JJ Popowich
Assistant Executive Officer

Attachment

July 22, 2016

Delivered via email to rmcontreras@lacera.com

Ms. Ricki Contreras
Manager, Disability Retirement Services Division
Los Angeles County Employees Retirement Association (LACERA)
300 N. Lake Avenue
Pasadena, California 91101
rmcontreras@lacera.com

Dear Ms. Contreras:

I have received your letter dated July 12, 2016. I was pleased to learn that the Disability Procedures and Services Committee of the Board of Retirement had approved my application for consideration, but saddened that their decision was reconsidered in light of the fact that an unredacted page of a medical report was inadvertently placed among the published articles submitted. Please accept my apologies for any concerns that this has caused you and the LACERA Board of Retirement. It is my sincere hope that the following explanation will alleviate any apprehension that the Board has with regard to this occurrence.

Your letter posed five key questions, and I will respond to each of them in turn. However, first I would like to provide a bit of clarifying information as it relates to the information that you received.

I chose to send workers' compensation reports as samples because they are often complex and challenge the doctoring and writing abilities of the candidate. The single unredacted page of a medical report that you received - among the copies of the published articles I provided - was that of a workers' compensation patient of mine. Workers' compensation reports are discoverable and in the public domain (redacted or unredacted). As such, the single page of the workers' compensation report that was inadvertently placed among the pages of my published articles was in no way a breach of confidential information as this is information that was already available within the public domain.

For answers to the questions you have posed, please review the following responses:

Question: What protocols do you have in place to safeguard patient data?

ExamWorks Response: Please find the enclosed policies and procedures entitled *Data Confidentiality and Security* and *Information Management*. These policies and procedures outline detailed information regarding ExamWorks' protocols for the management and safeguarding of confidential information including but not limited to Protected Health Information (PHI) and Individually Identifiable Health Information (IIHI), and also include procedures for the handling of any unauthorized disclosures of the same.

Question: Do you have a process in place for responding to a privacy breach? If so, please describe.

ExamWorks Response: Yes. ExamWorks follows a detailed process for responding to a suspected privacy breach. In summary, ExamWorks' Privacy Officer fully investigates and documents any/all incidents of unauthorized disclosures of PHI, develops action plans to address any identified incidents which include corrective actions to prevent future occurrences, maintains a complete record of the incident, reports any unauthorized disclosure to requisite parties as required by law or contract, and reports any unauthorized disclosures of PHI to the ExamWorks Quality Management Committee. Please refer to the previously mentioned policies and procedures for more detailed information.

Question: How and when will the affected patient be notified?

ExamWorks Response: This incident was not determined to be a breach by our Privacy Officer because the information in the unredacted report is information that is/was already available in the public domain.

Question: Has your office inadvertently released protected private health information previously? If so, please discuss.

ExamWorks Response: Although we have policies and procedures in place for incidents involving the inadvertent release of PHI/IIHI we have not had an incident where we have inadvertently released such information.

Question: What assurances will LACERA have that this will not happen in the future, especially to LACERA members?

ExamWorks Response: Even when state and Federal privacy and security requirements are followed explicitly and the requisite physical, technical, and administrative safeguards are implemented, we realize that no one is infallible and simple human error has the potential to create a breach. Because we understand that human error is inevitable despite the most rigid policies and procedures and safeguards, we take other measures to eliminate these risks as much as possible. As a result, we encourage staff to self-report any privacy or security concerns that may have occurred as a result of human error - whether the error was their own or that of someone else - and to do so without fear of reprisal. This approach affords us the opportunity to intervene as quickly as possible

when a suspected breach occurs, and allows us to mitigate any potential harm that may result. Additionally, it allows us to determine if there are any “holes” in our process that could be tightened up to prevent similar issues in the future. Provided that a potential breach is unintentional we want our employees to have no fear of punishment, and as a result, they are willing to report concerns instead of looking for ways in which to hide them, for fear of potential disciplinary action.

We also provide privacy and security training to all employees *before* they assume their job functions, as well as annual refresher training to significantly reduce - with the goal of eliminating - common human errors. We automate as much of the independent medical evaluation process as feasible, not only to be efficient in our processing of cases, but to eliminate as many opportunities for human error as possible.

Finally, our Compliance Department also proactively audits our work (which includes a regulatory component) and those results are shared with staff, management, senior management, and the quality oversight committee governed by our Board of Directors. For any issue that appears to be a trend or pattern, corrective action interventions are developed and implemented to minimize future reoccurrences.

The protection of confidential and personal information is the central premise around which the ExamWorks’ network and physical infrastructure was built. The U.S. Health and Human Services Department does levy fines, and any company or organization that has experienced a breach of HIPAA knows well the cost of remediation, detriment to reputation, and the individual whose records have been violated.

From a technological standpoint, ExamWorks offers clients access to the most secure virtual private cloud-based network, self-managed data centers by accredited professionals and the leading secure web application and portal with state-of-the-art encryption appliances. Accredited professionals manage our offices and follow strictly outlined protocols for physical security and paper document handling. ExamWorks is meticulous in the management of its network, data centers and document handling. ExamWorks has received the SOC 2® report. Our clients and accredited independent auditors can attest to these attributes.

ExamWorks’ privacy and security infrastructure policies and procedures address all requirements associated with Federal and state privacy and security guidelines in the United States. All employees undergo an annual training on privacy and security standards and complete and certify the company’s Code of Business Conduct and Ethics Policy. Selected relevant policies and procedures include: Data Confidentiality and Security, Information Management, Data Integrity, Business Continuity and Disaster Recovery, Data Backup, Encryption, Financial Application Security, Incident Response, Information Risk Management, Information Systems Security, Intrusion Detection, Network Security and Monitoring, Physical Asset Inventory Control, Security Awareness and Training, Sensitive Information Security and Vulnerability, and Patch Management.

These policies embody best-practices for both electronic transmission and physical handling of company and claimant data providing the highest assurances for that sensitive information remains secure.


ExamWorks' data centers adhere to best practices access controls. Access controls include: entry record management, company identification cards, key pads, biometrics, visitor identification badges and physical escort requirements.

These measures - coupled with a rigorous annual training and the other administrative, physical, and technical safeguards we have in place - speak to the fact that the possibility of a "systems type" error is virtually eliminated.

Please allow me to assure you that at ExamWorks we take privacy and security very seriously. If there is anything that we can do to further restore your faith in our abilities to keep data protected and secured, please do not hesitate to ask us.

If LACERA wishes, I would welcome the opportunity to appear at your August 3, 2016 Board Meeting to further clarify any outstanding questions or concerns.

Respectfully,



Michael M. Bronshvag, M.D.

Enclosures: Policy and Procedure: *Data Confidentiality and Security*
Policy and Procedure: *Information Management*

Title: Data Confidentiality and Security

Subject: Data Confidentiality and Security

Policy: ExamWorks provides for data confidentiality and security of its information system(s) (for both electronic and paper environments) by implementing written policies and procedures that address the following:

- An assessment of the potential risks and vulnerabilities to the confidentiality, integrity, and availability of information systems
- Prevention of confidentiality and security breaches, and
- Detection, containment and correction of confidentiality and security violations

Purpose: Proactive information systems management helps to maintain confidentiality and consistent information flow, supporting ExamWorks' ability to provide appropriate and timely services within the confines of applicable confidentiality requirements.

Responsibility: Operations, Quality & Compliance, Information Technology

Definitions:

- **Covered Entity (CE)** - A health plan, a health care clearinghouse, or a health care provider that electronically stores, maintains, or transmits health information
- **Business Associate (BA)** - A person or entity, who on behalf of the CE, performs or assists in the performance of a function or activity that involves the use or disclosure of PHI
- **Protected Health Information (PHI)** - As defined in 45 CFR § 164.501 includes any information, whether oral or recorded in any form or medium, that is created for or received from Covered Entity and that:
 - Relates to the past, present or future physical or mental health or condition of an individual, provision of health care to an individual, or the past, present or future payment for health care provided to an individual; and
 - Identifies the individual or provides a reasonable basis to believe that it may be used to identify the individual
- **Individually Identifiable Health Information (IIHI)** - Information that could be used alone, or in combination with other information, to identify an individual who is the subject of the information. Individually Identifiable Health Information includes:
 - Names
 - All geographic subdivisions smaller than a state including, street address, city, county, precinct, zip code, and their equivalent geocodes
 - All elements of dates (except year) for dates directly related to an individual, including birth date, admission date, discharge date, date of death; and all ages over 89 and all elements of dates (including year) indicative of such age, except that such ages and elements may be aggregated into a single category of age or older
 - Telephone numbers
 - Fax numbers
 - Electronic mail addresses
 - Social Security Numbers
 - Medical record numbers
 - Health plan beneficiary numbers
 - Account numbers

Title: Data Confidentiality and Security

- Certificate/license numbers
- Vehicle identifiers and serial numbers, including license plate numbers
- Device identifiers and serial numbers
- Web Universal Resource Locators (URLs)
- Internet Protocol (IP) address numbers
- Biometric identifiers, including finger or voiceprint
- Full face photographic images and any comparable images
- Any other unique identifying number, characteristic or code

- ExamWorks ensures that claimant-specific information is:
 - Kept confidential in accordance with state and federal laws
 - Used solely for the purposes of the requested service and for quality management
 - Shared only with those entities or individuals who have authority to receive such information
 - Shared only with those individuals who need access to such information in order to conduct the requested service, quality management, and related processes

Procedure:

1. All ExamWorks employees complete a training session for compliance of data confidentiality and security as it applies to HIPAA Regulations and the HITECH Act.
2. All ExamWorks employees and all physician consultants to ExamWorks sign a Confidentiality Agreement, indicating that they will abide by HIPAA Regulations and the HITECH Act.
3. All ExamWorks employees utilize login names and passwords to access their desktop computer records.
4. ExamWorks shall approve the installation and use of any software used on all computers.
5. ExamWorks computers are configured to automatically power off following a maximum of ten (10) minutes of inactivity.
6. Staff use the Control+Alt+Insert keys in a virtual environment when leaving computer unattended.
7. Staff are not be permitted to share or allow unauthorized users to log into ExamWorks computer.
8. An individual, who believes that he or she has observed or otherwise is aware of a violation of this Policy, is required to report the violation to their immediate supervisor.
9. ExamWorks designated Privacy Officer will conduct an investigation of the incident.
10. Individuals found to have violated HIPAA's Privacy Rule (45 CFR 164.502, 164.532) or the HITECH Act may be subject to temporary or permanent reduction or elimination of some or all IT privileges. Alleged violations of this Policy will be pursued in accordance with the appropriated disciplinary procedures for staff.
11. In addition to ExamWorks discipline, staff may be subject to prosecution, civil liability, or both for unlawful use of any IT System.
12. Any staff member found to have violated this policy may be subject to disciplinary action, up to and including suspension and/or termination.

Administrative Oversight

- ExamWorks designates an employee to serve as the "Privacy Official"
 - The Privacy Official has the overall responsibility, when applicable, for:
 - Ensuring the safeguarding of PHI, whether oral, written, electronic or in any form, and that is stored and/or transmitted
 - Ensuring compliance with HIPAA Regulations and the HITECH Act

Title: Data Confidentiality and Security

- Ensuring compliance with URAC standards related to individually identifiable information
- Development and implementation of P&Ps related to the safeguarding of PHI and compliance with HIPAA Regulations, the HITECH Act and URAC standards
- Serving as the contact person responsible for receiving complaints related to PHI
- Serving as the contact person responsible for responding to CE requests for access and/or amendments to PHI
- Duties and function of the Privacy Official are incorporated into the job description of the designated employee

Disclosure of PHI from CEs to ExamWorks as a Business Associate

- CEs may disclose PHI, or allow ExamWorks to receive or create PHI on the CEs behalf, if the CE has obtained assurances from ExamWorks, as a Business Associate, that ExamWorks will safeguard PHI
 - Documentation of assurances may take the form of a written Business Associate Agreement between the CEs and ExamWorks
 - If a CE chooses not to require ExamWorks to sign a Business Associate Agreement, ExamWorks retains no responsibility as a result
- When disclosing PHI, CEs (and therefore ExamWorks as the Business Associate) will make reasonable efforts to limit PHI to the minimum necessary to accomplish the intended purpose of the use or disclosure
- A CE (and therefore ExamWorks as the Business Associate) will not use, disclose, or request an entire medical record, except when the entire medical record is specifically justified as the amount that is reasonably necessary to accomplish the intended purpose of the use or disclosure

Disclosure of PHI from ExamWorks to Subcontractors and/or Agents (When Applicable)

- ExamWorks uses/discloses PHI solely for the management and administration of conducting requested services and/or quality management
- When disclosing PHI, ExamWorks makes reasonable efforts to limit PHI to the minimum amount necessary to accomplish the intended purpose of the use or disclosure
 - All referrals and PHI are screened by ExamWorks prior to its disclosure to subcontractors or agents
- Prior to any permitted disclosure of PHI, ExamWorks:
 - Verifies the identity and authority of an individual or entity prior to telephonic disclosure of PHI by requesting and obtaining one of the following verifying information:
 - Claimant's name
 - Claimant's date of birth
 - Obtains reasonable assurances that disclosed PHI will be held confidentially and used only for the purpose of conducting requested services
 - Reasonable assurances from subcontractors or agents are obtained in the form of signed confidentiality agreements
 - Obtains reasonable assurances from subcontractors or agents that any breach of confidentiality will be reported to ExamWorks
 - Reasonable assurances are obtained in the form of signed confidentiality agreements

Safeguarding PHI

Title: Data Confidentiality and Security

All confidential information is secured in order to protect privacy, and to prevent unauthorized persons from gaining access to such information. All staff members complete/sign a confidentiality agreement in which they agree to keep claimant information confidential in accordance with applicable state and federal laws and regulations. In addition, all board members and committee members complete/sign confidentiality agreement in which they agree to keep claimant information confidential in accordance with applicable state and federal laws and regulations. When state or federal regulations are more stringent than those of ExamWorks, state and/or federal regulations prevail.

- ExamWorks has administrative, technical, and physical safeguards in place to reasonably safeguard PHI from intentional or unintentional unauthorized use or disclosure
 - Administrative safeguards include:
 - Designation of a Privacy Official with the responsibility of ensuring the safeguarding of PHI
 - Signed confidentiality agreements with all employees, board members, physician consultants, subcontractors, vendors, and visitors
 - Employee confidentiality agreements are maintained in the employee's personnel file
 - ExamWorks' verification of the identity and authority of the individuals or entities receiving PHI
 - Fax cover sheets with privacy notice required for all outgoing faxes
 - Technical safeguards include:
 - Network security logins unique to each individual employee
 - Network access required to enable users to access the database that contains PHI
 - User access levels determine which employee has access to which type of information in the database
 - User access levels are assigned by Operations Management
 - PHI stored in the ExamWorks database is unable to be altered by any employee once a case comment has been entered and saved
 - Exceptions include altering an individual's name spelling, address, DOB, etc. for those instances where the information had been entered incorrectly into the demographic screens
 - Security log-ins, access password-protected for all employees
 - Physical safeguards:
 - PHI is maintained in a locked business office with access restricted by a locked door to ExamWorks employees, board members and physician consultants
 - The use of recording equipment (i.e. cameras in mobile devices) in areas where PHI/PII work is performed is strictly prohibited

Security of electronic PHI:

- ExamWorks develops, implements, maintains, and uses administrative, technical, and physical safeguards that reasonably and appropriately protect the confidentiality, integrity, and availability of Electronic PHI that ExamWorks creates, receives, maintains or transmits as required by the Security Rule, 45 C.F.R. Part 164, Subpart C.
- ExamWorks secures and protects confidentiality of information submitted by or generated for clients, including that referred to as "Protected Health Information".
- All computer systems are accessed via a confidential password and login. Each staff member uses this password to access demographic and claimant information. When a computer is not used during the day, the screen is brought back to the main menu. All computer sessions are logged out of at the end of the

Title: Data Confidentiality and Security

day. When a staff member leaves employment with ExamWorks, the account is disabled, thus preventing the individual the capability of entering the computer system.

- Faxes are a secure transmission by their very nature. Fax transmissions are done in a dial-up manner and each is a point-to-point secure connection that only exists for the duration of the call (transmission). The information sent is not in a text format but rather an image that cannot be modified
- If records are transferred via fax, all fax cover sheets contain the following confidentiality notice, or a confidentiality notice similar in content:

"This communication, along with any documents, files or attachments is intended only for the use of the addressee and may contain legally privileged and confidential information. If you are not the intended recipient, you are hereby notified that any dissemination, distribution or copying of any information contained in or attached to this communication is strictly prohibited. If you have received this message in error, please notify the sender immediately and destroy the original communication and its attachments without reading, printing, or saving in any manner. This communication does not form any contractual obligation on behalf of the sender or, the sender's employer, or the employer's parent company, affiliates or subsidiaries."

- All fax machines are located in a secure area. To maintain confidentiality, the fax machines are not accessible to the public and sending/receiving documents are not visible to the public
- Training and understanding of responsibilities regarding confidentiality and the handling of confidential materials is provided to all staff members, board members, and physician consultants
- Paper records that have satisfied their legal, fiscal, administrative and archival requirements may be destroyed in a manner that ensures the confidentiality of the records and renders the information no longer recognizable as ExamWorks' records

Confidentiality Agreements

- All ExamWorks employees, board members and physician consultants are required to sign a confidentiality agreement agreeing to protect PHI according to ExamWorks P&Ps
- Any/all ExamWorks subcontractors and agents are required to sign a confidentiality agreement
- All ExamWorks visitors/vendors are required to sign a confidentiality agreement

Training

- ExamWorks trains and documents training of all ExamWorks employees on the policies and procedures related to PHI
 - The ExamWorks Privacy Official, or designee, conducts the employee training
 - Training content includes:
 - Overview and key aspects of the HIPAA Privacy and Security Rules and the HITECH Act as well as URAC standards (when applicable) regarding Information Management (confidentiality), and Confidentiality of Individually Identifiable Health Information

Title: Data Confidentiality and Security

- Responsibilities of ExamWorks and its employees under the HIPAA Privacy and Security Rules, the HITECH Act, and URAC standards (when applicable) regarding Information Management (confidentiality), and Confidentiality of Individually Identifiable Health Information
- Documentation of training is maintained in the employee's personnel file or on sign-in sheets and maintained in a training log

Unauthorized Disclosure of Protected Health Information

- The ExamWorks Privacy Official:
 - Fully investigates and documents any/all incidents of unauthorized disclosure of PHI by ExamWorks
 - Develops action plans to address the identified incident and includes actions to prevent future occurrences
 - Maintains a complete record of the incident
 - Reports any unauthorized disclosure of PHI to the CE as required
 - Reports any unauthorized disclosure of PHI to the Quality Management Committee

Documentation

- ExamWorks retains PHI in compliance with applicable laws and regulations, as applicable

Approved*Approval Signature on File*

SVP, Compliance & Network Development

Title: Information Management

Subject: Information Management

Policy: ExamWorks implements information management processes (electronic and paper) to collect, maintain, and analyze information necessary for organizational management that:

- Provides for data integrity and;
- Includes a plan for storage, maintenance and destruction of information

Purpose: To ensure information utilized is accurate, handled in a confidential manner, and is consistently available to assure timely service.

Responsibility: Operations, Quality & Compliance, General Counsel, Information Technology

Definitions:

- N/A

Procedure:

Data Integrity

ExamWorks ensures data integrity through the following procedures:

- Administrative Support Staff Training and Supervisory Oversight
 - All Customer Service Representatives (CSRs) receive data integrity training from a CSR Supervisor or Operations Manager
 - All new CSRs have all aspects of their data entry and data integrity work checked and approved by a CSR Supervisor or Operations Manager until such time that the CSR demonstrates satisfactory work
 - New CSRs may be required to have their data entry and data integrity work checked for a period of time beyond the period at the discretion of the CSR Supervisors or Office Managers
 - Any/all CSRs may be required to have their data entry and data integrity work checked, regardless of their length of service, at the discretion of the CSR Supervisors or General Managers
- The Quality Audit
 - Components of the Quality Audit include the following oversight elements related to CSR data entry and data integrity:
 - All referral information entered correctly
 - All demographic information entered correctly
 - Type of case entered correctly
 - Service request entered correctly
- Individual Case Report Quality Assurance Check
 - Each and every case report undergoes thorough Quality Assurance review by Quality Analyst (QA) that includes ensuring that all demographic data is correct
 - All QAs receive training on all aspects of performing quality assurance reviews including verification of demographic data
- Unique Case Number Identifiers
 - The case processing application creates a unique case identification number for every case record that is established

Title: Information Management

- Verification of Prior Cases / Checking for Duplicate Entries
 - When ExamWorks receives a new referral:
 - The CSR institutes a system search of the databases for prior records
 - Search results provide a list of all related spellings and configurations of the target name search
 - The CSR reviews the appropriate case records and verifies the:
 - ExamWorks case number
 - Referred individual's first and last name
 - Referred individual's date of birth
 - Case files that are determined to be duplicate files by the CSR are brought to the CSR Supervisor or General Manager for review
 - The CSR Supervisor or General Manager verifies if a duplicate file exists
 - If a duplicate file does exist the CSR Supervisor, General Manager, or his/her designee:
 - Cancels the duplicate case
 - Cross-references the canceled file and correct file and documents the actions in the "case comments" sections of both cases

Data Storage, Maintenance, and Destruction

- PHI
 - Is maintained electronically and in secure file cabinets in a locked business office with access restricted to ExamWorks employees, physician consultants and board members.
 - Case file hard copies are maintained in accordance with applicable laws and regulations
 - Case electronic files are maintained for a minimum of 7 years, or in accordance with applicable laws and regulations
- Waste Paper Disposal
 - Waste paper is stored in the ExamWorks facility in a secure storage container
 - A recycling entity is contracted to dispose of the waste paper and appropriate Sub-Business Associate Agreements are executed
- Data and Media Destruction
 - Hard disk data is destroyed using a procedure compliant with NIST 800-88. Encrypted datacenter disks can be "Cryptographically Erased" via a procedure compliant with NIST 800-88. Permanent media (i.e., CDs and DVDs) must be physically destroyed. An NAID certified vendor will be used for all Hard Disk destruction. A certificate of destruction must be received from this service.
- Reuse of Media
 - A "secure deletion" program must be used to erase data from hard disks that contain PII before being reused.
- IT Asset Disposal
 - Personnel request disposal of IT assets by completing an IT asset requisition/disposal form and forwarding the form to the Information Technology Department Asset Manager
 - The Asset Manager directs the Help Desk to dispose of IT assets in accordance with applicable IT procedures
 - All IT assets are disposed of only through approved waste handlers or recyclers, in accordance with applicable IT procedures, and in a manner that complies with applicable Federal, state, and local statutes and guidelines. Possible destinations for disposable IT assets include but are not limited to:

Title: Information Management

- Reuse or reclamation by the Help Desk
- Returning to the vendor for failure of the asset to perform as expected or to conform to business requirements
- Returning leased assets to the vendor at the time of lease expiration
- Disposal of obsolete software versions in a manner approved by the vendor
- Sending the purchased asset to a sanitary landfill
- Sending the purchased asset to an approved recycler
 - Upon disposal of said assets, the Asset Manager updates the applicable documents
- Wiping of Hard Drives
 - ExamWorks performs a low-level format on all hard drives before disposal. Even though data is never stored on local hard drives as it is always stored on the servers, low-level formatting for all hard drives still occurs.
- E-mail Encryption
 - ExamWorks encrypts email using TLS encryption.

Approved

Approval Signature on File

SVP, Compliance & Network Development



300 N. Lake Ave., Pasadena, CA 91101 ■ Mail to : PO Box 7060, Pasadena, CA 91109-706 626/564-2419 • 800/786-6464

GENERAL INFORMATION		Date
Group Name: ExamWorks		Physician Name: Michael M. Bronshvag, M.D.
I. Primary Address: 11010 White Rock Road Suite 120, Rancho Cordova, CA 95670		
Contact Person Kristina Lewis	Title General Manager	
Telephone: 916 403 1769	Fax 916 920 2515	
II. Secondary Address 11010 White Rock Road Road Suite 110, Rancho Cordova, CA 95670		
Contact Person Shawnette Davis	Title Lead Scheduler	
Telephone 916 403 1784	Fax 916 920 2515	
PHYSICIAN BACKGROUND		
Field of Specialty Internal Medicine and Neurology	Subspecialty	Board Certified Internal Med and Neurology
Board Certification <input checked="" type="checkbox"/> Yes <input type="checkbox"/> No	License # G015805-CA	Expiration Date <u>04/30/2018</u>
EXPERIENCE Indicate the number of years experience that you have in each category.		
Evaluation Type		
I. Workers' Compensation Evaluations		
<input checked="" type="checkbox"/> Defense How Long? <u>40 years</u>	<input checked="" type="checkbox"/> IME How Long? <u>40 years</u>	How Long? <u>40 years</u> How Long? <u>25 years - since QME program began</u>
<input checked="" type="checkbox"/> Applicant How Long? <u>40 years</u>	<input checked="" type="checkbox"/> QME	
<input checked="" type="checkbox"/> AME How Long? <u>40 years</u>		
II. <input checked="" type="checkbox"/> Disability Evaluations How Long? <u>40 Years</u>		
For What Public or Private Organizations? SSA, CALPERS, DOL, LAPFP		
Currently Treating? <input checked="" type="checkbox"/> Yes <input type="checkbox"/> No		
Time Devoted to: Treatment	<u>5</u> %	Evaluations <u>95</u> %
Estimated Time from Appointment to Examination		Able to Submit a Final Report in 30 days?
<input checked="" type="checkbox"/> 2 weeks (if needed)		<input checked="" type="checkbox"/> Yes <input type="checkbox"/> No (more quickly if needed)
<input checked="" type="checkbox"/> 3-4 Weeks (Usually)		
<input checked="" type="checkbox"/> Over a month (rarely)		
LACERA's Fee Schedule		
Examination and Initial Report by Physician	\$1,500.00 flat fee	
Review of Records by Physician	\$350.00/hour	
Review of Records by Registered Nurse	\$75.00/hour	
Supplemental Report	\$350.00/hour	

-OVER-

Other Fees	
Physician's testimony at Administrative Hearing (includes travel & wait time)	\$350.00/hour
Deposition Fee at Physician's office	\$350.00/hour
Preparation for Expert Testimony at administrative Hearing	\$350.00/hour
Expert Witness Fees in Superior or Appellate Court	\$3,500.00 half day \$7,000 full day
Physician agrees with LACERA's fee schedule? Yes No	
Comments	
40 year interest in musculo-skeletal injuries, infections, metabolic disorders, hernias	


Name of person completing this form:

Michael M. Bronshvag, M.D.

(Please Print Name)

Title: M.D.

Physician Signature:



Date:

16 MAR 16

FOR OFFICE USE ONLY	
Physician Interview and Sight Inspection Schedule	
Interview Date: 6/7/16	Interview Time: 9:30 a.m.
Interviewer: Debbie Jannan	

CURRICULUM VITAE

MICHAEL M. BRONSHVAG, M.D.

EDUCATION

1956 - 1960 New York University - A.B. 1960; Phi Beta Kappa
1960 - 1964 Columbia University College of Physicians and Surgeons - M.D., 1964

INTERNSHIP AND RESIDENCIES

1964 - 1965 Passavant Memorial Hospital (Northwestern University Affiliated Hospital) Mixed Medical Internship

1965 - 1968 Northwestern University Medical Center, Residency in Internal Medicine

1971 Board Certified in Internal Medicine, American Board of Internal Medicine

1968 - 1971 Letterman General Hospital, San Francisco, California
Residency in Neurology

1974 Board Certified in Neurology, American Board of Psychiatry and Neurology

LICENSURE - Current

California License #G15805
Qualified Medical Evaluator, State of California

TEACHING APPOINTMENT -Current

University of California, San Francisco, in Neurology
(Assistant Clinical Professor of Neurology)

MILITARY SERVICE

1968 - 1980 ACTIVE DUTY - U.S. ARMY
1968 - 1980 Letterman Army Medical Center and
Letterman Army Institute of Research (Colonel, Medical Corps)

1980 - 1981 ACTIVE DUTY - United States Public Health Service Hospital,
San Francisco (0-6)

1982 - 2000 ACTIVE RESERVES - U.S. ARMY
6253 G.H. (Lt. Col., United States Army Reserve)
Hamilton Field, Novato, California

1986 - 1987 146 CSH, California Army National Guard (Colonel)

1987 - 1996 USAR-IRR (Colonel)

1996 - 1999 6250 USAH, Ft. Lewis, Washington

1999 - 2000 2290 USAH, WRAMC, Washington, D.C.

2000- RETIRED - 31 YEARS - U.S. ARMY
Colonel, Retired Reserves, U.S. Army

EMPLOYMENT - PRIVATE PRACTICE

1981 - 1985 Ross Valley Medical Clinic, 1350 South Eliseo, Greenbrae
1982 - 1991 350 Parnassus Avenue, San Francisco
1991 - Present 3000 "L" Street, Suite 308, Sacramento and
10 Commercial Boulevard, Suite 108, Novato, CA 94949

RESEARCH INTERESTS

CHILD AND ADULT DEVELOPMENT, NEUROPSYCHIATRIC AND PSYCHOLOGICAL EVALUATION

1979 "Ontogenesis of Human Brainstem Evoked Potential Amplitude,"
by A. Salamy, C. Birtley-Fenn, and Michael M. Bronshvag
in *Developmental Psychobiology*

DISEASES OF PERIPHERAL NERVES

February 1978 "Spectrum of Gustatory Sweating with Especial Reference to its Presence
in Diabetics with Autonomic Neuropathy," by Michael M. Bronshvag,
American Journal of Clinical Nutrition Volume XXI, pages 307-309

"Treatment of Painful Diabetic Neuropathy with Hydroxocobolamin--
Clinical Observations, Electrophysiologic Measurements. and
Measurement of Urinary Myoinositol Levels," by Michael M. Bronshvag,
Valerie Coppes and R.H. Herman.

HEADACHE

1978 "Vascular Headaches in Mixed Connective Tissue Disease," by
Michael M. Bronshvag, Steven D. Prystowsky, and Daniel C. Traviesa,
Headache Volume XVIII, pages 154-169

ANOXIC ISCHEMIC CEREBRAL PATHOLOGY AND INJURY

July 1978 "Cellular Basis of Anoxic Ischemic Brain Injury," by Michael M.
Bronshvag, *Western Journal of Medicine* Volume CXXIX, pages 8-18

"Clinical Electroencephalographic Effects of Subacute Hemorrhagic
Shock in Sleep," by Michael M. Bronshvag, *Military Medicine*

"Cerebral Pathophysiology in Hemorrhagic Shock, Nuclide Scan,
Fluorescence Microscopy, and Anatomic Correlations," by Michael M.
Bronshvag--accepted for publication, *STROKE*

"Cerebral Pathophysiology in Hemorrhagic Shock, Effects of
Hemorrhagic Shock Upon Visual Evoked Potentials"

DIAGNOSIS AND EVALUATION OF HEAD INJURY

"Evaluation and Detection of Superior Sagittal Sinus Occlusion in the
Sheep Employing Electroencephalography and Radio-Labeled
Fibrinogen"

ELECTROENCEPHALOGRAPHY

"EEG Study of Normal Volunteers Before, During, and After Pyridoxine Deficient Diet"

PUBLICATIONS

- BRONSHVAG, M., "Cellular Basis of Anoxic-Ischemic Brain Injury. Present Concepts in Internal Medicine," *Neurology Symposium* 1975, pages 112-122
- BRONSHVAG, M., "Cellular Basis of Anoxic-Ischemic Brain Injury," *Western Journal of Medicine* Volume CXXIX, pages 8-18, 1978
- BRONSHVAG, M., PRYSTOWSKY, S.D., AND TRAVIESA, D.C., "Vascular Headaches in Mixed Connective Tissue Disease," *HEADACHE* Volume XVIII, Pages 154-160, 1978
- BRONSHVAG, M., "Spectrum of Gustatory Sweating with Especial Reference to Its Presence In Diabetics with Autonomic Neuropathy," *American Journal of Clinical Nutrition*, Volume XXXI, pages 307-309, 1978
- SALAMY, A., FENN, C.B., and BRONSHVAG, M., "Ontogenesis of Human Brainstem Evoked Potential Amplitude," *Developmental Psychology* Volume XII, pages 519-526, 1979
- BRONSHVAG, M., "Cerebral Pathophysiology in Hemorrhagic Shock, Nuclide Scan Data, Fluorescence Microscopy, and Anatomic Correlations," *Stroke* Volume XI, pages 50-59, 1980
- BRONSHVAG, M., "Clinical and Electroencephalographic Effects of Subacute Hemorrhagic Shock in Sheep," *Military Medicine* Volume CXXXV, pages 277-281, 1980
- BRONSHVAG, M., COPPES, V.G., and BROOKES, E.D., "Acute Reactive Mitochondrial Changes in Incremental Hemorrhagic Shock in Sheep," *Neurological Research*, Volume III, pages 381-391, 1981

PRESENTATIONS

- BRONSHVAG, M., and HERMAN, R., "New Concepts of Old Diseases: Treatment of Painful Diabetic Neuropathy with Hydroxo B12, Preliminary Observations," American College of Physicians Course, January 1977
- BRONSHVAG, M.M., MD, INC. - QME courses (each year)

CURRENT INTERESTS

Electrodiagnosis
Neuroanatomy
Work Injuries and Occupational Health
Dynamics of Medical Instruction

Sample Report #1

MICHAEL M. BRONSHVAG, M.D.
Diplomate in Neurology, ABP&N
Diplomate in Internal Medicine, ABIM

[REDACTED]

XXXXXXXXXXXXXXXXXXXX, [REDACTED]
XXXXX XXXXXXXXXXXXXXXXXXXXXXXXXXXXXXX
XXXX XXX XXXXX
XXXXXXXX XXXX, XX XXXXX-XXXX

XXXXXXXXXXXXXXXX X. XXXXXX, Esq.
XXXXX, XXXXXXXXXXX, XXXXXXX, XXXXXX, XXXX, XXXXXXXXXXX, XXXXXXX &
XXXX, LLP
XXXX XXXXXXX XXXXXXX, XXXXX XXXX
XXX XXXXXXXXXXX, XX XXXXX

AGREED MEDICAL EVALUATION

Re: XXXXXXXXXXXXXXX, XXXXX
Date of Injury: [REDACTED]
Employer: XXXXXXXXXXXXXXXXXXXXXXX
WCAB Case No.: XXXXXXXXXXXXXXX
Claim No.: XXXXXXXXXXX

Dear All:

Mr. XXXXX XXXXXXXXXXXXXXX presented for an Agreed Medical Examination in [REDACTED]
[REDACTED] on the [REDACTED]. This is my report of
my efforts.

The claimant, Mr. XXXXX XXXXXXXXXXXXXXX, is [REDACTED] years old and resides in XXXXX XXXX,
XXXXXXXXXXXX.

Under penalty of perjury, this report is submitted pursuant to 8 Cal. Code Regs. Section 9795(b) & (c) as a ML-104-94 Comprehensive Medical Legal Evaluation Involving Extraordinary Circumstances and meets the requirement of four complexity factors. These include: (5) 6+ hours spent on any combination of three of the complexity factors (1)-(3) which shall count as 3

Re: XXXXX XXXXXXXXXXXXX

Page 2

complexity factors; (6) Addressing the issue of medical causation, which shall count as one complexity factor;

Time spent in direct, face to face contact was .50 hour. Time spent reviewing records required 3 hours. Time spent on research was 3 hours. Time spent preparing the report was 1.50 hours. Total time spent on this case was 8 hours.

INITIAL COMMENT – I am consulted relevant to the specific problem of left basilica vein thrombosis. This apparently resulted from insertion-removal of a PICC vein line in [REDACTED]. Head blows are noted in [REDACTED] and then [REDACTED] (or [REDACTED]). Migraine, neck trauma and seizure versus non-seizure (?psyche?) problems are weighed.

The discussion to date does not weigh the genetically-determined issues of Migraine with Basilar Aura (MBA – also called Basilar Migraine) and Familial Hemiplegic Migraine (FHM). FHM-BMA have similar dominant genetic drivers. The two (MBA-FHM) may cause syncope/coma/psychosis episodes resembling seizure or psyche events. In view of the positive family history and the history of migraine since age seven, FHM/MBA may explain the 'seizure/pseudoseizure issue. Also, the literature until [REDACTED] stated that DHE was contraindicated for MBA/FHM, although the [REDACTED] literature (now) says that DHE is safely given in FBM-BMA

HISTORY

The claimant tells of interest in agribusiness and that he had worked for over [REDACTED] years as a [REDACTED] [REDACTED] – XXX until [REDACTED] sustained head trauma (two specific injuries) ([REDACTED] and then [REDACTED]), and also has had a history of back-spine trauma of a cumulative nature. He has been evaluated in detail by medical neurologist XXXXXX.

The claimant tells me his neck difficulties resulted from airplane turbulence injuries. His job was a XXX [REDACTED], and the plane he was in – doing surveillance – jolted (in [REDACTED] and then [REDACTED]) while he was wearing a five-pound helmet - he struck the ceiling of the plane with his head and he had the onset of left-sided neck pain and left-sided posterior head pain, apparently largely in the distribution of the left greater occipital nerve relevant to the [REDACTED] injury.

He was referred, apparently at the suggestion of Dr. XXXXXX, to a XXXX headache protocol which involved the infusion of DHE (dihydroergotamine) and this was by "PICC" line

Re: XXXXX XXXXXXXXXXXX
[REDACTED]

Page 3

(peripherally inserted central catheter). He developed phlebitis of the left arm, in what is described as the distribution of the left basilic vein in the upper medial part of the arm (largely proximal to the left elbow). He was thus then a candidate for anticoagulation, and Coumadin was chosen because of his previous history of gastroesophageal issues (rather than one of the Factor X inhibitors). He tells me that an left arm ultrasound performed more recently ([REDACTED] [REDACTED]) suggested that the clot was "dissipating" and thus the claimant's ongoing left upper arm symptoms are perhaps either due to vein occlusion and perhaps due to vein inflammation.

Accordingly, the sequence of events is of exposure to airplane turbulence in his job for the XXX (officer), diagnosis of left-sided neck symptoms and left-sided posterior head symptoms. His migraine history was noted and resulted in a diagnosis of "migraine plus trauma" and he was entered into a XXXX-DHE protocol. As a result of that DHE protocol (PICC line), he developed phlebitis as noted and the claimant has been on Coumadin therapy. His symptoms in the left proximal arm – medially – persist but are perhaps improving-improved.

The claimant still has the basis issues of

- a) Low back – cumulative and
- b) Left-sided neck difficulties and left posterior head difficulties (greater occipital neuralgia, migraine, cervical degenerative joint and disc disease, ?combination?, seizure v.s. other).

At this point I turn my attention to the letter from Attorney XXXXXXX. Attorney XXXXXXX takes note of a blood clot in the left arm believed to be a compensable consequence by Attorney XXXXXXX. The injuries in question to head, neck and left arm occurred in [REDACTED] and [REDACTED] (or [REDACTED]).

It is stated that the claimant was evaluated by Drs. XXXXXXX (neurology), XXXXXXXXXXXX (neuropsychologist), and XXXXXXX (orthopedist). Hearing loss was noted and low back cumulative trauma noted. The claimant's head pain difficulties since [REDACTED] are noted and the left arm blood clot issue of [REDACTED] is noted. The possibility of low back surgery was mentioned as well.

I review the AME letter from Claims Representative XXXXXXX as well. Issues involve left shoulder, upper back, internal organs, abdomen-groin, CHP. The issues of ongoing problems, back surgery and blood thinners are raised by Representative Valenti. It is stated that the claimant was medically retired in [REDACTED] and had been off work for several months prior to his retirement.

The more recent head blow occurred in [REDACTED] (Dr. XXXXXXX) or [REDACTED]

Re: XXXXX XXXXXXXXXXXXX

Page 4

MEDICAL REVIEW OF SYSTEMS

The claimant gives a history of gastroesophageal symptoms which interact with his Coumadin issues. He is being treated by lisinopril for blood pressure issues and nortriptyline for pain and sleep issues. He is being treated with Coumadin.

CURRENT COMPLAINTS

As noted above, the claimant continues to have symptoms (improved) relevant to the medial aspect of the left upper arm (basilic vein).

He has difficulty with prolonged lying down, sitting, standing and walking, and increased problems with climbing, lifting, bending, reaching, crouching, stooping, kneeling and balancing.

He is unable to work at the present time because of his migraines which he describes as debilitating, his head-neck pain, his low back pain, and also his left medial upper arm symptoms.

PREVIOUS MEDICAL HISTORY

As noted – above – prior to the [REDACTED] head and neck event, the claimant did have lower back symptoms as well.

JOB DESCRIPTION

The claimant has been a [REDACTED], including flight details, during his [REDACTED] years of service. He notes the heavy helmet.

PERSONAL AND SOCIAL HISTORY

The claimant is [REDACTED] with a weight of [REDACTED] pounds. He is under the care of Dr. XXXXXXXX of XXXXXX, Dr. XXXXXXXX of XXXX, and Dr. XXXXX of XXXXXX, plus treatment for the blood clot. He lists his airplane as a [REDACTED]. The claimant was hospitalized for what is described as “seizure”-like activity thought not to be actual seizures ([REDACTED]).

The family history is positive for diabetes. The mother has migraine headaches. He is a nonsmoker, nondrinker, and he denies drug misuse. He is a life-long Californian - [REDACTED]. He is

Re: XXXXX XXXXXXXXXXXXX

Page 5

continuing studies at XXXXXX XXXXX. He is able to read and write well. He had been a XXX [REDACTED] from [REDACTED] including flight duties. He has a driver's license, is right-handed, has difficulty walking a block, climbing more than a few steps or lifting more than a few pounds.

Thus the claimant, who is receiving pain relief treatment (nortriptyline), psychological treatment (Lexapro), blood pressure treatment (lisinopril), and remains on Coumadin, has a history of

- a) The left upper arm medial vein problem,
- b) Neck and left side of head difficulties described as migraine (?greater occipital neuralgia?),
- c) Low back issues, and
- d) History of gastrointestinal issues as well.
- e) Seizures versus psychological issues

MEDICAL RECORDS REVIEW

At this point I turn my attention to the (big stack of) medical records kindly provided at this time. These records are contained in a sizable stack.

I note that Dr. XXXXXXXX – medical neurologist – in [REDACTED] described a history of an injury in [REDACTED] and a further event in [REDACTED]. Dr. XXXXXXXX diagnosed chronic neck pain with musculoskeletal headaches, work-related, and he thought that there might be a brain tumor or intracranial cause. MRI of the head was thus planned by medical neurologist Cantrell.

The MRI of the head – [REDACTED] – took note of right maxillary sinusitis and no intracranial abnormalities. Dr. XXXXXXXX thus, after that negative study, stated that a cervical and root problem might be present. Neck abnormalities on the neck MRI were noted. Left-sided changes were prominent. Electrodiagnostics at that time were compatible with left carpal tunnel syndrome and no other overt abnormalities.

Dr. XXXXX had noted in [REDACTED] that the claimant had cervical radiculitis, neck pain, tension headache, myofascial syndrome, myopathic pain, chronic pain-related insomnia, and chronic pain syndrome.

Imaging studies documented normal carotid in [REDACTED].

Dr. XXXXX had noted acute right facial droop, with altered speech, and intractable headache (?migraine?).

Re: XXXXX XXXXXXXXXXXXX

Page 6

Dr. XXXX had recommended DHE treatment in [REDACTED].

Dr. XXXXXXXX had described the claimant's set of difficulties, noted that neurological issues were prominent, and that these all seemed to be related to his work efforts (turbulence – head bump). The possibility of seizure episode was mentioned in [REDACTED]. The issue of psychogenic causes for the seizure-like episodes was mentioned. PTSD was mentioned as well. Dr. XXXXXXXX in [REDACTED] mentioned the possibility of cervical epidural steroid injection, occipital nerve block, and medications. He did not urge trigger point injections and did not urge medical foods or creams. Epidural steroid injection was contemplated.

In [REDACTED], Dr. XXXXXXXXXXXX thought that there was a cognitive disorder – mild – post concussion.

EEG in [REDACTED] was normal.

It was stated that the claimant had a “known history of seizure disorder” (Dr. XXXXXXXXXXXX) and has presented in status epilepticus, with a seizure disorder, controlled hypertension, hypertensive heart disease with left ventricular hypertrophy and chronic neck pain. CT of the brain was described as normal. The EEG brain wave test was normal.

Dr. XXXXX had diagnosed occipital neuralgia, psychogenic nonepileptic seizures, and a mood disorder.

Dr. XXXXXXXX memorialized the vectors and stated in [REDACTED] that the claimant had a constant, dull, baseball-bat pain in the cervical occipital junction, a ram-horn distribution head pain, with migrainous “characteristics” and nausea, and a spike headache that appeared to be sexually related. The fabric of the four episodes was analyzed. Dr. XXXXXXXX did not come to closure but mentioned vascular seizure, periodic, and movement issues. The spectre of nonorganic disease was raised.

Dr. XXXXX noted lumbar puncture brain pressure measurement. He thought the most reasonable diagnosis was occipital neuralgia, left-sided. It was noted that EEG monitoring observation in [REDACTED] documented a typical episode, with a normal EEG.

The MRI of the low back dated [REDACTED] documented modest changes at L4-L5 and L5-S1 levels.

Re: XXXXX XXXXXXXXXXXXX

Page 7

The [REDACTED] note of Dr. XXXXXXXXXXXX stated that a seizure was not demonstrated and that psychogenic reasons were suspected by Dr. XXXXXXXXXXXX did not think that there was a clear-cut psychological problem.

Neurosurgeon XXXXXXXXXXXXXXX of Los Angeles had stated in [REDACTED] the claimant had normal neurodiagnostics and the diagnoses were occipital neuralgia, lump at the left occipital, cervical region, seizures vs pseudo-seizures, cervical radiculopathy, lumbar radiculopathy, shoulder pain, cognitive impairment, emotional distress and sleep disturbance. The doctor was curious about the lump at the back of his neck. EEG was advised. The electrodiagnostics were noted.

The imaging study of [REDACTED] described two soft tissue densities within the subcutaneous fat overlying the occiput in the region of clinical concern. [REDACTED] [REDACTED].

FCE evaluation is noted.

Clinical psychologist XXXX noted cognitive issues.

The psychological evaluation of Dr. XXXXXXXXXXXX in [REDACTED] again took note of cognitive issues.

Dr. XXXXXXXX continued to take note of neck and also low back issues.

Dr. XXXXXXXX had, in [REDACTED], advised of the complexity of the issues and suggested he see neurologist XXXXXXXX, MD, headache specialist referral.

Dr. XXXXXXXX had noted in [REDACTED] that further data were provided. Head pain since age of eight was described, with worsening relative to work injuries. Family history of headache was noted as well. CSF protein was 55 in [REDACTED]. Diagnosis of Dr. XXXXXXXX was chronic migraines with medication overuse and primary stabbing headaches, and likely migrainous vertigo. The issue of the claimant's motion sensitivity was noted. Dr. XXXXXXXX noted that the claimant should have the DHE protocol and then return to Dr. XXXXXXXX for followup. Opiate withdrawal was advised.

Headache service efforts were noted in [REDACTED]. Occasional headaches at age 8-9. Constant headaches were described in [REDACTED]. Left-sided photophobia, phonophobia and nausea, extreme movement sensitivity, neck stiffness, blurring of vision, lightheadedness, allodynia, difficulty concentrating, and mood changes were mentioned. Kidney stones, right inguinal hernia

Re: XXXXX XXXXXXXXXXXXX

Page 8

repair, vasectomy, sinus surgery, head trauma x2, degenerative joint disease of the neck, and upper and lower endoscopy – relevant to GI bleed – and proctitis was thought to be relevant to NSAID usage. Medications included gabapentin, Norco, Lexapro, lisinopril, and Botox. The discharge diagnosis of [REDACTED] – Dr. XXXXX and Dr. XXX – was chronic migraine.

PM&R specialist XXXXXXXXX stated in [REDACTED] the claimant had a history of traumatic brain injury, head pain and neck pain.

After the [REDACTED] and [REDACTED] ([REDACTED]) head bump events, he noted twisting difficulties in [REDACTED]. Loss of consciousness followed by headache was mentioned. Episodes of vertigo were noted. Rehab efforts were noted.

The UCSF notes from [REDACTED] describe IR PICC line placement. Successful midline placement was described, under ultrasound and fluoroscopic guidance. DHE administration was noted. Enoxaparin treatment was mentioned.

The efforts of Dr. Riggins are noted. The Midline (?Medline) was then pulled. The ED note – [REDACTED] – is noted. Left arm difficulty was noted. Numbness and swelling of the fingers were mentioned.

The note of Dr. XXXXXX of [REDACTED] is mentioned. Dr. XXXXXX had taken note of the [REDACTED] left arm phlebitis event. Dr. XXXXXX's rating formula is noted.

Dr. XXXXXXXX took note of the claimant's situation in note of [REDACTED]. Improvement of headaches was noted. Botox treatments were commented upon. Proctitis diagnosis was noted.

Dr. XXX was treating the claimant in the "local hematology office" for left upper extremity incompletely occlusive thrombus throughout the visible portion of the left basilic vein with Coumadin treatment.

Dr. XXXX – XXXXXXXXXXXX XXXXXXXXX & XXXXXXXX XXXXXXX – XXXXXXX – reported in [REDACTED].

Dr. XXXXXX had stated that the claimant cracked his flight helmet in [REDACTED] and had injury in [REDACTED]. Diagnostic audiometry mentioned bilateral high-frequency sensorineural hearing loss, high-frequency "mild to severe," was mentioned. Tinnitus, occipital neuralgia type dizziness, vestibular concussion, vestibular response impairment were also noted.

Re: XXXXX XXXXXXXXXXXXX

Page 9

The possibility of acoustic neuroma was weighed by Dr. XXXXXX and thought to be unlikely.

MRI and MRA in [REDACTED] and [REDACTED] were unremarkable. EEG video telemetry was normal. EEG at Pacific was negative. CT scan of the head in [REDACTED] showed the subcutaneous densities. Lumbar puncture in [REDACTED] described opening pressure of 28. Scintigraphy in [REDACTED] was described as normal. Coenzyme Q10 therapy was suggested.

The claimant added that the helmets that he had been employing when he was flying were very heavy ones (about 5 pounds) and more recently light-weight helmets have been substituted. It is the opinion of the claimant that the heavy helmets increased his difficulties relevant to skull-cervical spinal cord issues when head trauma was involved. (Narrator's comment: That matches up with the current thinking about heavy football helmets for high school football players.)

Thus the issues challenging the claimant – old and new – include gastroesophageal issues (nonsteroidal-related – proctitis), Coumadin therapy for his left basilic vein area phlebitis, low back pain, and left-sided head issues, and overall musculoskeletal issues.

PHYSICAL EXAMINATION

At the present time, my physical examination of the claimant does not demonstrate any overt cognitive, memory or language deficits. The claimant apparently is continuing in studies at [REDACTED].

He described to me no current overt psychological symptoms – nor were any evident to me. Vision and hearing were grossly normal (however, high-tone hearing loss has been demonstrated (?noise-related?). The blood pressure is measured at 136/83, the pulse is 101, and no overt dyspnea, cyanosis, edema or cough are noted. Eyes, fundoscopic exam, and cranial nerves are normal. ENT exam is normal. Neck shows no abnormality of trachea, veins, or thyroid. Lungs, heart, and pulses are normal. The abdominal and skin examinations are normal.

No arterial pulse deficits are noted.

The craniocervical junction is of note in that there is tenderness to palpation in the left craniocervical junction area over the course of the left greater occipital nerve.

(There is a greater occipital nerve – there is a third occipital nerve – there is a lesser occipital nerve – there is no “occipital nerve.”)

Re: XXXXX XXXXXXXXXXXXX

Page 10

The claimant complained of discomfort in the left occipital region of the scalp in the distribution of the left greater occipital nerve.

Range of motion of neck was slightly limited. There was tenderness to palpation in the left paracervical region. Shoulder, elbows, wrists, arms and hands were unremarkable. Midback was normal. There is tenderness to palpation over the low back and range of motion of low back was limited to 40 degrees of forward flexion, -5 degrees of extension, and 10 degrees bilaterally of lateral flexion. Hip rotation and straight leg raising were not limited.

The balance of the musculoskeletal examination was normal.

Examination of the left "upper" arm demonstrated residual tenderness in the distribution of the left basilic vein. I did not demonstrate gross stasis-venous in the upper arms, forearms or hands.

No overt sensory or motor neurological deficits are noted and the tendon reflexes are 1+.

DIAGNOSES

Accordingly, the appropriate diagnoses are:

- 1 Complex headache issue with positive family history of migraine; headaches with motion sensitivity dating back to youth; head injuries, most probably involving craniocervical junction and the left greater occipital nerve, with associated cervical issues as well; the combination of migrainous issues, and greater occipital nerve neuralgia issues are noted. Migraine with basilar aura (MBA) and variant Familial Hemiplegic Migraine (FHM) should be considered as MBA often causes peculiar episodes of loss of consciousness
- 2 Neck strain difficulties, cervical degenerative joint and disc disease - ? nature of lump in left occipital area ?.
- 3 Low back difficulties, low back degenerative joint and disc disease.
- 4 History of kidney stones.
- 5 Episodes of altered awareness and neurological difficulties, suspected to be seizures; seizures not demonstrated; the possibility of an ischemic problem or a migraine-related difficulty, possibility of ?familial hemiplegic migraine? ?migraine with basilar aura? noted at this time.
5. Occlusive phlebitis, left basilic vein – improving – treated.

Re: XXXXX XXXXXXXXXXXX

Page 11

INITIAL DISCUSSION

The primary issue I am challenged with is the left basilic vein and the left upper arm and to what extent the claimant will or will not require ongoing anticoagulation. As a rule of thumb (see references), a problem with phlebitis may require up to six months of therapy in the absence of ongoing phlebitis. Episodes of pulmonary embolism with obvious phlebitis are usually treated for six months. Episodes of pulmonary embolism in the absence of known phlebitis are often treated for a longer period of time (a year).

The diagnosis of "DVT" ("deep") has been offered but perhaps it is better to regard the basilic vein as a superficial ("S") vein. I do not observe any current documentation of spread of the process into the axillary area (issue of effort thrombosis – axillary vein) or more proximally (Lemierre's syndrome).

Accordingly,

Temporary total disability – This claimant has not worked in 2+ years. He apparently is not felt able to go back to his job as a [REDACTED] and [REDACTED].

His episode of left basilic vein thrombosis is almost certainly caused by the PICC line. If it is concluded that his headaches have an occupational component, and referral to UCSF was an occupational issue, then this phlebitis event is undoubtedly work-caused. The claimant did continue with his studies and examinations.

If this episode of basilic vein thrombosis had occurred while the claimant was actively working as a [REDACTED] and [REDACTED], a period of TTD would have been appropriate.

Permanent partial disability-MMI – Occlusive phlebitis disease of this type often remits entirely (sometimes it doesn't). Sometimes the periphlebitis (inflammatory issue) persists and gives ongoing symptoms even though flow has been regained. The claimant has been told that the basilic vein is partially functional at this time (see discussion below). Spread of the clot problem proximally into the chest is possible but unlikely.

AMA Guides Impairment Rating – I take note of the efforts of Drs. XXXXXXXXXX, XXXXXX and XXXXXXXX.

It is my understanding that I am being asked to comment only relevant to this claimant's left basilic vein area. It is possible that this area will "heal up entirely." I want to make sure that we are not dealing with anything that might lead to a troublesome vein problem more proximally

Re: XXXXX XXXXXXXXXXXXX

Page 12

(see discussion below). Therefore, relevant to AMA Guides rating, I will hold off at this time. I take note of the fact that Dr. XXXXXX has provided ratable language in other areas.

Subjective Symptoms – Relevant to the claimant’s left upper arm, he was acutely symptomatic in [REDACTED], with a swollen arm. His findings currently are much more benign and it is possible that they will entire remit (see discussion below).

Objective factors – At the present time there is tenderness over the course of the left basilic vein without other striking abnormalities.

Over and above that, the claimant quite obviously has other issues relevant to spine and head.

Causation – As noted above, assuming that the claimant’s head pain is at least partially work-caused (family history was noted), then his admission to XXXX in [REDACTED] was for work-related issues, and the removal of the PICC line and the onset of phlebitis would be a work-caused compensable issue.

Apportionment – Pending. It is possible and hoped for that there will be no residual ratable disability and therefore apportionment might not need to be contemplated relevant to the basilic vein.

Return-to-work issues – The claimant is a college student. He is probably going to be employable. Return to [REDACTED] work seems unlikely.

Treatment efforts – The claimant is on Coumadin. His doctors are tentative or uncomfortable with the newer Factor X inhibitors, because if they do cause bleeding, the bleeding might not be easily stopped (if a patient on Coumadin bleeds, you can give him or her a shot of vitamin K) (or have him eat a few Brussels sprouts).

Studies requested – The claimant requires a current MR–V study of the left arm and the left thoracic outlet area to make sure that the clot has not spread proximally.

Ultrasound is a reasonable modality for the basilic vein, but since the issue is not just the basilic vein but the more proximal areas (axillary-subclavian-vertebral), the MR “V” (high field 3 tesla) is appropriate. I am going to order up a collateral-companion blood count, chemistry panel, ESR and CRP relevant to the issue of an inflammatory disorder.

Re: XXXXX XXXXXXXXXXXXX
[REDACTED]

Page 13

Research performed – Please refer to the refereed-open source articles I have selected relevant to familial hemiplegic migraine, greater occipital neuralgia, effort thrombosis (axillary vein), basilic vein, Lemierre’s syndrome, and all anticoagulants (Coumadin versus Factor X inhibitors).

I request the privilege of seeing the claimant back again in two to four months to make sure that no worrisome residual vein problems are present.

If questions remain or arise, kindly write me back and I will respond immediately. As you will note, it is my assumption that Drs. XXXXXXXXXXX, XXXXXXX and XXXXXX are providing the ratings to areas “other than” the claimant’s left upper extremity. However, if further input is required on any of those “other” issues, let me know. As you will also note, I am looking forward to seeing the claimant back again to make sure that his venous system is ‘okay’.

As you will also note, I have commented upon the possibility of MBA-FHM, and the pertinent QMEs and treaters may choose to weigh those comments.

I certify that I took the complete history from the claimant, conducted the examination, reviewed all available medical records, and composed and drafted the conclusions of this report. The conclusions and opinions within this report are solely mine. I declare under penalty of perjury that the information contained in this report and its attachments, if any, is true and correct to the best of my knowledge and belief, except as to information that I have indicated I received from others. As to that information, I declare under penalty of perjury that the information accurately describes the information provided to me and, except as noted herein, that I believe it to be true. In accordance with Labor Code Section 57039(a), there has not been a violation of Labor Code Section 139.3, and the contents of the report are true and correct to the best of my knowledge. This statement is made under penalty of perjury.

Pursuant to 8 Cal. Code Regs Section 49.2-49.9, I have complied with the requirement for face-to-face time with the claimant in this evaluation. If necessary, I have discussed apportionment in the body of this report. If I have assigned disability caused by factors other than industrial injury, that level of disability constitutes the apportionment. The ratio of non-industrial disability, if any, to all described disability represents my best medical judgment of the percentage of disability caused by the industrial injury and the percentage of disability caused by other factors, as defined in Labor Code Sections 4663 and 4664.


Respectfully,

Michael M. Bronshvag, M.D.
Diplomate in Neurology, ABP&N
Diplomate in Internal Medicine, ABIM
Date of Report: [REDACTED]

PubMed

Abstract

Full text links



Angiology. 2000 Feb;51(2):173-7.

Internal jugular vein thrombosis, Lemierre's syndrome; oropharyngeal infection with antibiotic and anticoagulation therapy—a case report.

Nakamura S¹, Sadoshima S, Doi Y, Yoshioka M, Yamashita S, Gotoh H, Onoyama K.

Author information

Abstract

The authors present a case of Lemierre's **syndrome** that is an uncommon septic thrombophlebitis of the internal jugular vein. A **year-old** man developed pharyngeal pain one month before hospital admission when he suffered from a severe headache and painful swelling of the left side of his neck. He was diagnosed with tonsillitis. Contrast-enhanced computed tomography and magnetic resonance imaging of the neck revealed the presence of an occlusive thrombosis of the left internal jugular vein and an inflamed mesopharynx. His symptoms and the jugular vein thrombus showed remarkable improvement after administration of antibiotic and anticoagulation therapy. No pulmonary embolism or other metastatic infection were observed. It was suggested that accurate diagnosis during early treatment is essential to obtain a successful prognosis for Lemierre's **syndrome**.

PMID: 10701727 [PubMed - indexed for MEDLINE]

Publication Types, MeSH Terms

LinkOut - more resources

PubMed Commons

PubMed Commons home

0 comments

How to join PubMed Commons

PubMed ▼

Abstract

[Full text links](#)

Thromb Res. 2015 Sep 1. pii: S0049-3848(15)30103-1. doi: 10.1016/j.thromres.2015.08.020. [Epub ahead of print] **FULL-TEXT ARTICLE**

Systematic review of anticoagulant treatment of catheter-related thrombosis.

Baumann Kreuziger L¹, Onwuemene O², Kolesar E³, Crowther M⁴, Lim W⁵.

Author information

Abstract

Central venous catheter-related thrombosis (CRT) is a complication seen in patients requiring long-term intravenous access. Treatment of CRT is not standardized and international guidelines for treatment are based on extrapolation of evidence from lower extremity thrombosis. We performed a systematic review of the literature to evaluate if duration of anticoagulation affects the risk of recurrent venous thrombosis, post-thrombotic **syndrome**, or major hemorrhage. We searched PubMed, Embase, Medline, CINAHL, Cochrane, and ACP Journal club for studies of CRT treated with anticoagulation. Of 1648 titles and abstracts, 23 studies met our inclusion criteria. No randomized trials were identified. Duration of anticoagulation varied from 8days to more than 6months. Outcomes of patients with upper extremity thrombosis due to CRT or other etiologies were often combined. The incidence of post-thrombotic **syndrome** varied between 0 and 75% depending on the definition used. Seven percent of patients with upper extremity thrombosis treated with anticoagulation experienced recurrent **deep vein** thrombosis and 2.8% experienced pulmonary embolism. Major hemorrhage was reported in 2.8-4.9% of anticoagulated patients. Prospective studies evaluating the optimal duration of anticoagulation in patients with CRT are needed.

Copyright © 2015. Published by Elsevier Ltd.

PMID: 26342400 [PubMed - as supplied by publisher]

LinkOut - more resources

PubMed Commons

[PubMed Commons home](#)

0 comments

[How to join PubMed Commons](#)

PubMed ▼

Abstract

[Full text links](#)[J Formos Med Assoc.](#) 2006 Feb;105(2):182-6.[FULL-TEXT ARTICLE](#)

Effort thrombosis of the upper extremities related to an arm stretching exercise.

[Liang HW](#)¹, [Su TC](#), [Hwang BS](#), [Hung MH](#).

Author information

Abstract

"Effort" axillary-subclavian vein thrombosis (Paget-Schroetter syndrome) is an uncommon deep venous thrombosis due to repetitive activity of the upper limbs. Most cases of this condition are related to strenuous or prolonged sport or occupational activities, while others are associated with endogenous or exogenous risk factors. We report the case of a 43-year-old, previously healthy, male who developed right axillary-subclavian venous thrombosis, which was possibly associated with an exercise involving arm extension and shaking in a posture of shoulder abduction and outstretched for 10 minutes on 2 consecutive days. The condition improved but returned with increased severity when he resumed the exercise after a 2-day break, when he presented with a swollen and bluish arm at the emergency department. Sonographic examination showed moderate thrombotic stenosis of the right axillary vein. Effort thrombosis was diagnosed after ruling out associated coagulopathy or concomitant malignancy. External compression of the accessory ribs or lymph nodes were not detected. He was treated with low molecular weight heparin, followed by oral anticoagulant therapy for 6 months. Only partial resolution of thrombosis was achieved after 6 months of anticoagulant therapy, but pulmonary embolism did not occur during 18 months of follow-up. This case illustrates that, although unusual, Paget-Schroetter syndrome can occur in a healthy patient as a result of mild to moderate exercise.

PMID: 16477342 [PubMed - indexed for MEDLINE]

Publication Types, MeSH Terms, Substances

LinkOut - more resources

[PubMed Commons](#)[PubMed Commons home](#)

0 comments

Patient information: Deep vein thrombosis (DVT) (Beyond the Basics)

Authors

Menaka Pai, MD, FRCPC
James D Douketis, MD,
FRCPC, FACP, FCCP

Section Editor

Lawrence LK Leung, MD

Deputy Editor

Geraldine Finlay, MD

DEEP VEIN THROMBOSIS OVERVIEW

Venous thrombosis is a condition in which a blood clot (thrombus) forms in a vein. This clot can limit blood flow through the vein, causing swelling and pain. Most commonly, venous thrombosis occurs in the "deep veins" in the legs, thighs, or pelvis ([figure 1](#)); this is called a deep vein thrombosis, or DVT.

DVT is the most common type of venous thrombosis. However, a thrombus can form anywhere in the venous system. If a part or all of the blood clot in the vein breaks off from the site where it is formed, it can travel through the venous system; this is called an embolus. If the embolus lodges in the lung, it is called pulmonary embolism (PE), a serious condition that leads to over 50,000 deaths a year in the United States. In most cases, PE is caused when part of a DVT breaks off and lodges in the lung. The term "venous thromboembolism" is sometimes used when discussing both DVT and PE.

This topic review discusses the risk factors, signs and symptoms, diagnostic process, and treatment of a deep vein thrombosis. The diagnosis and treatment of pulmonary embolisms are discussed separately. (See "[Patient information: Pulmonary embolism \(Beyond the Basics\)](#)".)

DEEP VEIN THROMBOSIS RISK FACTORS

There are a number of factors that increase a person's risk of developing a deep vein thrombosis.

If a person is found to have a DVT and there is no known medical condition or recent surgery that could have caused the DVT, it is possible that an inherited condition is the cause. This is especially true in people with a family member who has also experienced a DVT or pulmonary embolism. In these cases, testing for an inherited thrombophilia may be recommended. However, finding an inherited thrombophilia does not change the way that doctors treat the venous thromboembolism, and may not increase the chance of the blood clot coming back. (See "[Finding the cause of venous thrombosis](#)" below.)

Medical conditions or medications — Some medical conditions and medications increase a person's risk of developing a blood clot:

- Pregnancy
- Obesity
- Smoking
- Heart failure
- Previous DVT or pulmonary embolism (PE)
- Increased age
- Cancer — Some cancers increase substances in the blood that cause blood to clot.

Anticoagulation in Deep Vein Thrombosis

• Author: Donald Schreiber, MD, CM; Chief Editor: Barry E Brenner, MD, PhD, FACEP more...

Updated: Jan 14, 2015

Advantages of Anticoagulant Therapy

Anticoagulant therapy remains the mainstay of medical therapy for deep venous thrombosis (DVT) because it is noninvasive, it treats most patients (approximately 90%) with no immediate demonstrable physical sequelae of DVT, it has a low risk of complications, and its outcome data demonstrate an improvement in morbidity and mortality. Meta-analyses of randomized trials of unfractionated heparin (UFH) and low-molecular-weight heparin (LMWH) showed that they were similar, with risk of recurrent DVT of 4%, a risk of pulmonary embolism (PE) of 2%, and a risk of major bleeding of 3%.^[1, 2]

Contributor information and Disclosures

Author

Donald Schreiber, MD, CM Associate Professor of Surgery (Emergency Medicine), Stanford University School of Medicine

Donald Schreiber, MD, CM is a member of the following medical societies: American College of Emergency Physicians

Disclosure: Nothing to disclose.

Specialty Editor Board

Mary L Windle, PharmD Adjunct Associate Professor, University of Nebraska Medical Center College of Pharmacy; Editor-in-Chief, Medscape Drug Reference

Disclosure: Nothing to disclose.

Chief Editor

Barry E Brenner, MD, PhD, FACEP Professor of Emergency Medicine, Professor of Internal Medicine, Program Director for Emergency Medicine, Case Medical Center, University Hospitals, Case Western Reserve University School of Medicine

Barry E Brenner, MD, PhD, FACEP is a member of the following medical societies: Alpha Omega Alpha, American Heart Association, American Thoracic Society, Arkansas Medical Society, New York Academy of Medicine, New York Academy of Sciences, Society for Academic Emergency Medicine, American Academy of Emergency Medicine, American College of Chest Physicians, American College of Emergency Physicians, American College of Physicians

Disclosure: Nothing to disclose.

Acknowledgements

Francis Counselman, MD, FACEP Chair, Professor, Department of Emergency Medicine, Eastern Virginia Medical School

Francis Counselman, MD, FACEP is a member of the following medical societies: Alpha Omega Alpha, American College of Emergency Physicians, Association of Academic Chairs of Emergency Medicine (AACEM), Norfolk Academy of Medicine, and Society for Academic Emergency Medicine

Disclosure: Nothing to disclose.

Gary Setnik, MD Chair, Department of Emergency Medicine, Mount Auburn Hospital; Assistant Professor, Division of Emergency Medicine, Harvard Medical School

Gary Setnik, MD is a member of the following medical societies: American College of Emergency Physicians, National Association of EMS Physicians, and Society for Academic Emergency Medicine

PubMed ▼

Abstract

Full text links

Headache. 2010(6):1057-9. doi: 10.1111/j.1526-4610.2010.01682.x. Epub [redacted].

Full Text Online 

Acute treatment of basilar-type migraine with greater occipital nerve blockade.

Baron EP¹, Tepper SJ, Mays M, Cherian N.

Author information

Abstract

Basilar-type migraine (BTM) precludes use of migraine-specific medications such as triptans and ergots based on concerns originating from the vascular theory of migraine, although data supporting this contraindication are lacking. Availability of effective treatments for acute BTM is limited. We report a case of BTM aborted with greater occipital nerve (GON) blockade given in the setting of prominent suboccipital tenderness. GON blockade may provide an additional option in acute management of BTM. It may be particularly useful when associated with prominent ipsilateral suboccipital tenderness.

PMID: 20487035 [PubMed - indexed for MEDLINE]

Publication Types, MeSH Terms

LinkOut - more resources

PubMed Commons

[PubMed Commons home](#)

0 comments

[How to join PubMed Commons](#)

ADVERTISEMENT

Sumatriptan
 6.5 mg / 4 hours

with the press of a  button

M

REGISTER NOW LOG IN

Migraine with Brainstem Aura

G+1 Tweet 2

CLICK TO RATE ★ ★ ★ ★ ★

Migraine with brainstem aura (MBA) is characterized by recurring attacks of certain temporary symptoms that are believed to originate in the brainstem. The brainstem is located at the base of the brain and connects to the top of the spinal cord; its function is to help regulate the two-way channel of communication between the brain and the body. Until 2013, MBA was known as "basilar-type migraine." In the updated version of the International Headache Society's guidelines – The International Classification of Headache Disorders, 3rd Edition (ICHD-III) – it was renamed "migraine with brainstem aura" because research now suggests that the basilar artery in the brain is not involved in causing its symptoms, as had previously been thought.¹

The ICHD-III classifies MBA as a sub-type of the broader category of migraine with aura, which was also revised in the newest guidelines to include MBA and three other sub-types: migraine with typical aura (MTA), hemiplegic migraine, and retinal migraine. MTA is the most common of those four, with MBA and the others being relatively rare. While researchers are unsure about precisely how many people have MBA worldwide, a 2006 study of 362 patients with MTA in Denmark reported that about 1 in 10 of those patients also had MBA.² Another study in China in 2011 found that 6.6% (23/348) of MTA patients had also experienced MBA attacks.³ In both studies, there were about 4 times as many women with MBA than men. Most people are initially diagnosed with MBA as teenagers or young adults.

Symptoms of migraine with brainstem aura

The ICHD-III defines a specific set of brainstem aura that are experienced as symptoms during MBA attacks:

- Vertigo is a type of dizziness described as the feeling that the body or surrounding environment is spinning or tilting, even though both are actually stationary.
- Dysarthria refers to difficulty controlling the speech-producing muscles (mouth, tongue, larynx, etc) resulting in slurring, mumbling, and general difficulty in producing sounds and

IHS Classification ICHD-II



English

ICHD-II Full Text Search

Home

Introduction

- Prefaces
- Introduction to the classification
- How to Use This Classification
- Subcommittees and working groups
- The Classification**
- Table of contents
- Part I: The primary headaches
- Part II: The secondary headaches
- Part III: Cranial neuralgias, facial pain and other headaches
- Appendix
- Definition of Terms

The International Headache Society (IHS) is the world's membership organisation for all whose professional commitment, whatever their discipline, is to helping people whose lives are affected by headache disorders.

[Visit the IHS website](#)

In Zusammenarbeit mit



Home » Basilar-type migraine [1.2.6]G43.103

1. MIGRAINE

- 1.1. Migraine without aura
- 1.2. Migraine with aura
 - 1.2.1. Typical aura with migraine headache
 - 1.2.2. Typical aura with non-migraine headache
 - 1.2.3. Typical aura without headache
 - 1.2.4. Familial hemiplegic migraine (FHM)
 - 1.2.5. Sporadic hemiplegic migraine
 - 1.2.6. Basilar-type migraine
- 1.3. Childhood periodic syndromes that are commonly precursors of migraine
- 1.4. Retinal migraine
- 1.5. Complications of migraine
- 1.5. Probable migraine
- Aggravating factors
- Trigger factors (precipitating factors)
- Bibliography

2. TENSION-TYPE HEADACHE (TTH)

3. CLUSTER HEADACHE AND OTHER TRIGEMINAL AUTONOMIC CEPHALALGIAS

4. OTHER PRIMARY HEADACHES

IHS	Diagnosis	ICD-10
1.2.6	Basilar-type migraine	G43.103
Previously used terms	Basilar artery migraine, basilar migraine	

Description:

Migraine with aura symptoms clearly originating from the brainstem and/or from both hemispheres simultaneously affected, but no motor weakness.

Diagnostic criteria:

- A. At least 2 attacks fulfilling criteria B-D
- B. Aura consisting of at least two of the following fully reversible symptoms, but no motor weakness:
 - 1. dysarthria
 - 2. vertigo
 - 3. tinnitus
 - 4. hypacusia
 - 5. diplopia
 - 6. visual symptoms simultaneously in both temporal and nasal fields of both eyes
 - 7. ataxia

Consult the Sitemap to learn more about the structure of the classification and its main chapters.

[More](#)

To facilitate headache diagnosis in daily practice, the classification provides the corresponding WHO ICD-10MA codes for each IHS code.

[More](#)

The Classification Subcommittee prepares and revises the International Classification of Headache Disorders.

[More](#)

ICHD-III Beta
The International Classification of Headache Disorders, 3rd edition, beta version

[ICHD-III Beta](#)

Extend your electronic library with important IHS publications. All documents may be downloaded free of charge.

[More](#)

Cephalalgia is the official journal of the IHS. It contains original papers on all aspects of headache. The journal provides an international forum for original research papers, review articles and short communications.

<http://cep.sagepub.com/>

Ask questions and share information about the 2nd edition of the Headache Classification in one of our

Occipital neuralgia

From Wikipedia, the free encyclopedia

Occipital neuralgia, also known as **C2 neuralgia**, or (rarely) **Arnold's neuralgia**, is a medical condition characterized by chronic pain in the upper neck, back of the head and behind the eyes. These areas correspond to the locations of the lesser and greater occipital nerves. The greater occipital nerve also has an artery that supplies blood that is wrapped around it - the occipital artery - that can contribute to the neuralgia. This condition is also sometimes characterized by diminished sensation in the affected area as well.

Occipital neuralgia

Classification and external resources

ICD-10 G52.8

(<http://apps.who.int/classifications/icd10/browse/2015/en#/G52.8>).^[1]
R51

(<http://apps.who.int/classifications/icd10/browse/2015/en#/R51>).^[2]
G44.847

ICD-9- 723.8 (<http://www.icd9data.com/getICD9Code.aspx?icd9=723.8>)

CM

Contents

- 1 Causes
- 2 Symptoms
- 3 Treatment
- 4 References
- 5 External links

Causes

Occipital neuralgia is caused by damage to these nerves. Ways in which they can be damaged include trauma (usually concussive), physical stress on the nerve, repetitive neck contraction, flexion or extension, and as a result of medical complications (such as *osteochondroma*, a benign tumour of the bone). Another rare but possible cause is CSF leaks.^[3] Yet another cause is from radio frequency nerve ablation. Rarely, occipital neuralgia may be a symptom of metastasis of certain cancers to the spine.^[4] There are several areas that have potential to cause injury from compression:

1. The space between the vertebral bones of C1 and C2
2. The atlantoaxial ligament as the dorsal ramus emerges
3. The deep to superficial turn around the inferiolateral border of the obliquus capitis inferior muscle and its tight investing fascia
4. The deep side of semispinalis capitis, where initial piercing can involve entrapment in either the muscle itself or surrounding fascia
5. The superficial side of semispinalis capitis, where completion of nerve piercing muscle and its fascia again poses risk
6. The deep side of the trapezius as the nerve enters the muscle
7. The tendinous insertion of the trapezius at the superior nuchal line
8. The neurovascular intertwining of the GON and the occipital artery

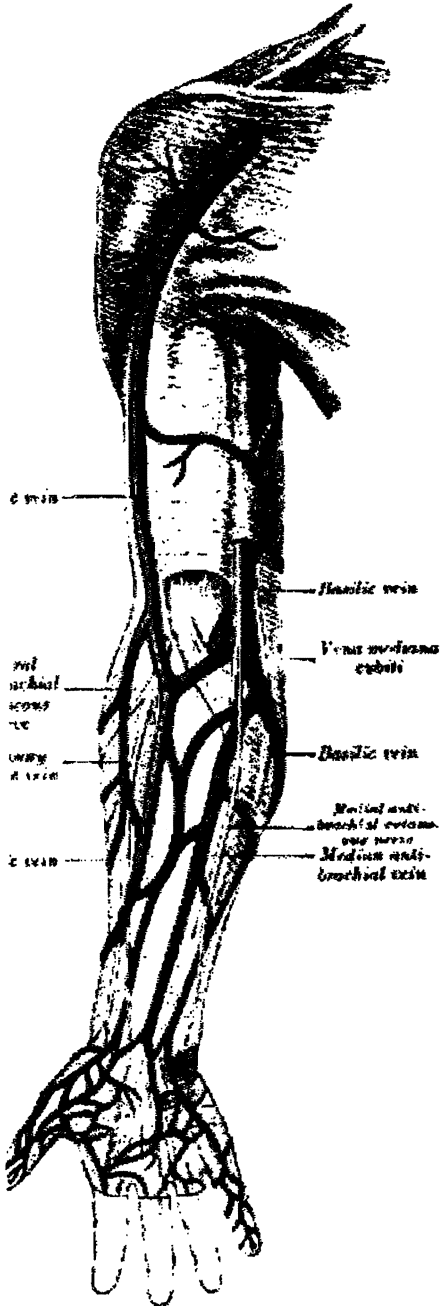
Symptoms

The main symptom of this condition is chronic headache. The pain is commonly localized in the back and around or over the top of the head, sometimes up to the eyebrow or behind the eye. Because chronic headaches are a common symptom of numerous conditions, occipital neuralgia is often misdiagnosed at first, most commonly as tension

Basilic vein

From Wikipedia, the free encyclopedia

Basilic vein



Superficial veins of the upper limb.



Migraine with brainstem aura (basilar-type migraine)

Authors

David F Black, MD
 Carrie Elizabeth
 Robertson, MD

Section Editor

Jerry W Swanson, MD

Deputy Editor

John F Dashe, MD, PhD

All topics are updated as new evidence becomes available and our [peer review process](#) is complete.

Literature review current through: Aug 2015. | This topic last updated: Feb 10, 2015.

INTRODUCTION AND DEFINITION — Migraine with brainstem aura (MBA), previously called basilar-type migraine, is a rare form of migraine with aura wherein the primary signs and symptoms seem to originate from the brainstem, without evidence of weakness. Originally described by Bickerstaff in 1961 as a distinct clinical entity [1], previous descriptions consistent with MBA were given by Aretaeus in ancient Greece and by Gowers in 1907 [1-3].

The terminology used to describe what some have called "Bickerstaff syndrome" has evolved over time; "basilar artery migraine" was replaced by "basilar migraine" and then by "basilar-type migraine." The disorder is now called migraine with brainstem aura [4]. Each subsequent term attempted to maintain the identity of the disorder, while weakening the association with the basilar artery. This evolution has occurred because there is no evidence that the basilar artery is involved, and because some of the symptoms may localize outside the territory of the basilar artery.

This topic will review the clinical manifestations, diagnosis, and treatment of MBA. Other aspects of migraine are discussed separately. (See "[Pathophysiology, clinical manifestations, and diagnosis of migraine in adults](#)".)

PATHOPHYSIOLOGY — Most experts now consider MBA as a subset of migraine with aura, and its etiology rests in the theory that cortical spreading depression produces the aura. Cortical spreading depression is a self propagating wave of neuronal and glial depolarization that spreads across the cerebral cortex (see "[Pathophysiology, clinical manifestations, and diagnosis of migraine in adults](#)" section on 'Cortical spreading depression'). The difference between MBA and migraine with typical aura is that the location of the aura symptoms in MBA primarily involves the brainstem or the bilateral occipital hemispheres, whereas in typical migraine the aura symptoms are mainly restricted to a unilateral hemisphere. However, cortical spreading depression as the cause of altered local blood flow and metabolism in the brainstem has only been proven in animals [5].

Bickerstaff invoked the vascular hypothesis, the prevailing theory at the time, to explain the symptoms of "basilar artery migraine" that were referable to either the brainstem or the bioccipital hemispheres [1]. In a later publication, he acknowledged that he had "rather loosely termed" this condition basilar artery migraine [6]. In truth, there is no evidence that the basilar artery is involved in the etiology of MBA, and abnormal flow in the basilar artery has never been proven in MBA. Only two cases, one with familial hemiplegic migraine with MBA-like symptoms, and one with MBA, have shown ictal spasm of the basilar artery on angiography [7,8]. Another case was reported with reduced mean flow velocity in both posterior cerebral arteries during a single MBA episode with resolution after the aura [9]. Despite these reports, it is unlikely that reversible ischemia is the source of the prolonged symptoms that occur with MBA.

Genetics — Data are limited regarding the genetic basis of MBA. A mutation in the ATP1A2 gene was found in three first-degree relatives with MBA [10], and another study reported that a single patient suffering from attacks of both MBA and episodic ataxia type 2 had a novel nonsense mutation in the CACNA1A gene, which has been frequently implicated in patients with familial hemiplegic migraine (FHM) [11]. These findings suggest a possible shared pathogenetic mechanism between MBA and FHM (see "[Hemiplegic migraine](#)", section on '[Pathophysiology and genetics](#)'). However, in a population-based study from Denmark, no causative mutation

MICHAEL M. BRONSHVAG, M.D.
Diplomate in Neurology, ABP&N
Diplomate in Internal Medicine, ABIM

Supplemental Report
Sample #1

[REDACTED]

XXXXXXXXXXXXXXXX, [REDACTED]
XXXXX XXXXXXXXXXXXXXXXXXXXXXXXXXXXXXX
XXXX XXX XXXX
XXXXXXXX XXXX, XX XXXXX-XXXX

XXXXXXXXXXXXX X XXXXXX, Esq.
XXXXX, XXXXXXXXXXX, XXXXXXXX, XXXXXX, XXXX, XXXXXXXXXXX, XXXXXXXXXXX & XXXX, LLP
XXXX XXXXXXX XXXXXXX, XXXXXX XXXX
XXX XXXXXXXXXXX, XX XXXXXX

AGREED MEDICAL REEVALUATION

Re: XXXXXXXXXXX, X
Date of Injury: [REDACTED]
Employer: XXXXXXXXXXXXXXXXXXXXXXX
WCAB Case No.: XXXXXXXXXXX
Claim No.: XXXXXXXX

Dear All:

XXXXX XXXXXXXXXXX was seen for an Agreed Medical Reevaluation on [REDACTED] at XXXX
XXXXXXXX XXXXXXX, XXXXXX XXX, XXXXXXX, XX XXXXXX.

Pursuant to Title 8 Cal Code of Regulations, Section 9795 (b) and (c), this report is submitted as a basic comprehensive medical-legal evaluation, ML 101-94. Time spent face-to-face with the claimant was 45 minutes, record review required 120 minutes and report preparation required 90 minutes. Total time spent on this case was 255 minutes.

Re: XXXXX XXXXXXXXXXXX
[REDACTED]

Page 2

I have seen the claimant, Mr. XXXXX XXXXXXXXXXXX, previously – [REDACTED]. At that time I took note of his left upper arm basilic vein thrombosis – apparently improving. I also took note of his complex set of difficulties – head pain, loss of consciousness-issues and also a history of low back issues, kidney stones, and the possibility of seizures, psychological problem, but I had suggested migraine with basilar aura (Bickerstaff's syndrome).

At this time the claimant returns.

I had commented upon greater occipital neuralgia.

The basic issue – however – was the claimant's left upper arm-basilic vein.

At this time I review the current cover letters from Attorney XXXXX and Specialist XXXXXXX, XXXX. Of note, it is also mentioned that the claimant suffered injury on [REDACTED] (left shoulder, upper back, internal organs, abdomen and groin). Attorney Dehner asks about doing further testing relevant to the phlebitis issue.

As you will note, I got the history that the claimant had been working as a [REDACTED] until [REDACTED]. He described to me two specific injuries ([REDACTED] and then he referred to a [REDACTED] injury) and he had told me he had a history of back-spine trauma of a cumulative nature.

The efforts of medical neurologist XXXXX were noted.

The claimant states that his neck difficulties appear to have resulted from several episodes of airplane turbulence while he was using a heavy (? too heavy ?) helmet (surveillance duties). As a result of the [REDACTED] event, relevant to airplane turbulence, the claimant had worsening of his left-sided neck symptoms and left-sided posterior head (greater occipital nerve) symptoms.

The diagnosis of "migraine plus trauma" was advanced. A DHE protocol was employed, as described. As a result of the DHE protocol, he developed phlebitis of the left basilic vein and has been placed upon Coumadin therapy.

Of note, the claimant has a history of hemorrhagic-type gastroesophageal difficulties and nonsteroidals are not thought to be a reasonable risk. Coumadin therapy was given and it was thought that the Factor X blocker anticoagulants were too much of a risk.

Re: XXXXX XXXXXXXXXXXX

Page 3

The basic issues thus were

- 1 Low back – cumulative.
- 2 Left-sided neck difficulties.
- 3 Left posterior head difficulties (greater occipital neuralgia).
- 4 Recurrent symptoms of a migraine nature.
- 5 Cervical degenerative joint and disc disease.
- 6 The issue of seizure versus psychosis or psychological issue (as an explanation for what appear to be syncopal episodes).
- 7 The ongoing current problem of thrombophlebitis in the left basilic vein.

Accordingly, there are two different areas that I am being tasked to comment upon at this time:

- 1 The left upper arm phlebitis (per Attorney XXXXXX).
- 2 Musculoskeletal difficulties involving neck and left arm (XXXX).

The claimant tells me that he is being followed by a hematologist and the most recent studies (which I don't have yet) suggest recurrence of the phlebitis problem-left basilic vein (rather than the hoped-for resolution).

The claimant continues to complain of pain and episodic swelling of the left upper arm in the medial area (where the basilic vein is). Initially the claimant's left hand had been swollen and purplish but this is not evident at this time.

Thus the claimant tells me at this time that as a result of injuries, including [REDACTED], he has head and neck symptoms, migraine headaches, and low back difficulties. Coumadin therapy is being continued. The claimant has not returned to work and it appears that he will not ever return to his usual and customary job ([REDACTED]).

TREATMENT EFFORTS

The claimant is being followed by Dr. XXXXXXXX (XXXXXX), Dr. XXXXXXXX (neurology – headache – UCSF), and Dr. XXXXX (XXXXXX), plus a hematology specialist. Imaging studies have been done recently.

Re: XXXXX XXXXXXXXXXXXX

Page 4

JOB DESCRIPTION

As noted – above – TSO until [REDACTED] – no work since, although the claimant is a college student now.

MEDICATIONS

The claimant is being treated with amitriptyline and Coumadin. He avoids nonsteroidals and is not a candidate for the "Factor X inhibitor" anticoagulants. He has been told that he needs to continue on Coumadin because of the apparent residual or recurrent clot activity in the left basilic vein (left upper arm).

COMMENT

As you will note, my previous effort provided a picture of the left basilic vein and discussion of the entity of migraine with basilar aura (migraine with basilar onset, Bickerstaff's syndrome).

It is my understanding that the detailed workup I had commented upon previously did not provide any primary evidence for either a seizure disorder or a psychological-psychiatric problem.

REVIEW OF SYSTEMS

The height is [REDACTED]. The weight is [REDACTED] pounds.

The claimant denies other primary evidence of lung or heart disease, high blood pressure or diabetes. There is no history of kidney or liver disease, gastrointestinal problems, weight loss or anemia. The family history is positive for diabetes – mother's side.

PERSONAL AND SOCIAL HISTORY

The claimant is [REDACTED] with a weight of [REDACTED] pounds. He does not smoke or drink. He denies drug misuse. He is a life-long [REDACTED]. He is able to read and write well. He is unable to return to his [REDACTED]. He does not employ crutches, a cane or a

Re: XXXXX XXXXXXXXXXXX

Page 5

brace. He has a driver's license, is right-handed, can walk a block, climb a flight of steps, and lift a few pounds.

Accordingly, as I approach the claimant today (repeat evaluation), the problems are

- 1 Left basilic vein – status – thrombophlebitis.
- 2 Head pain with migraine features, greater occipital neuralgia features, and the question of seizure versus psychological issue versus migraine with basilar aura (or combination or other).
- 3 The musculoskeletal issues relative to the [REDACTED] injury, and the claimant adds that injury had also occurred in [REDACTED] and cumulatively, with
 - a) Neck symptoms
 - b) Left shoulder area symptoms (before the basilic vein problem)
 - c) Low back symptoms.

The claimant denies bladder, bowel, or erectile deficits.

RECORDS REVIEW

Treating Doctor XXXXXXXX took note of the claimant's head pain, treatment by XXXX – Dr. XXXXXXXX, nortriptyline and tapering the gabapentin. Neck range of motion was abnormal. Impression included traumatic brain injury with sequelae, headaches, and chronic neck pain. Improvement with Botox was noted.

Input of Dr. XXXXXXXXXX is noted.

Dr. XXXXXXXX - XXXX - thought the claimant had "trauma - head pain." Video EEG of [REDACTED] was noted. Numbness in fourth and fifth fingers – left hand – was noted. Neck-spine symptoms were mentioned. Treatment efforts of Dr. XXXXX are noted. Dr. XXXXXXXX noted candesartan therapy in [REDACTED]. Dr. XXXXXXXX noted the [REDACTED] evaluation of [REDACTED] for left basilic vein thrombosis. Nonocclusive thrombus was recanalized. Venous flow was described with no evidence of thrombus in the left basilic vein at that time. It was thought that there was evidence for previous thrombus in the left subclavian vein.

Re: XXXXX XXXXXXXXXXXX

Page 6

The efforts of hematologist Rao are noted. The claimant had described the DHE treatment as otherwise reasonably successful and ultrasound of the left upper extremity had been planned for [REDACTED]. It was thought that NSAID therapy caused the proctitis.

Dr. XXXXXX had stated that the claimant could not take NSAIDs.

The [REDACTED] imaging study – CT – showed soft tissue densities in the occipital area.

The cisternography of [REDACTED] was physiologic, and the CTA head study in [REDACTED] was normal. The brain MRI of [REDACTED] was described as normal. Review of that study in [REDACTED] did not document left occipital abnormality.

Dr. XXXXXXX, as of [REDACTED], diagnosed posttraumatic chronic migraine with improvement with DHE treatment. Nortriptyline was offered. Botox was mentioned and treatment with candesartan. The possible significance of injections causing swelling in [REDACTED] was noted. Numbness of the left fourth and fifth fingers was noted.

PHYSICAL EXAMINATION

My physical examination of the claimant performed at this time demonstrated no evidence of memory, language or cognitive deficits. Overt anxiety and depression were not documented at this time. The vision and hearing were grossly normal. Blood pressure was measured at 135/80 with a pulse of 80, and no dyspnea, cyanosis, edema, or cough were noted. The eyes, funduscopic exam, and cranial nerves are normal.

There is tenderness to palpation in the left occipital skull area and slight sensory diminution in the distribution of the greater occipital nerve. Overt lumps or bumps are not palpated or appreciated at this time.

ENT exam is otherwise normal. Neck shows no abnormality of trachea, veins, or thyroid. Lungs, heart, and pulses are normal. The abdominal and skin examinations are normal.

The musculoskeletal examination is of note.

Re: XXXXX XXXXXXXXXXXXX

[REDACTED]

Page 7

To begin with, temporomandibular joints are normal. Neck range of motion shows slight limitation to full range of motion, with comfortable flexion allowed, forward flexion to plus 30 degrees, extension to minus 10 degrees, and lateral flexion bilaterally allowed to plus 10 degrees.

The right shoulder shows a full range of motion. Abduction of the left shoulder past 160 degrees causes symptoms.

Midback is normal. There is complaint of pain on range of motion of low back. Hip rotation is full and straight leg raising in the seated position is full. The balance of the musculoskeletal examination of the spine and legs is normal.

Right arm is normal. There is residual tenderness to palpation in the right medial upper arm area. I do not demonstrate gross or overt phlebitis changes at this time but the claimant notices symptoms in the area.

No sensory or motor neurological deficits are noted. Tone, stance and speech are normal, and the tendon reflexes are 1+. The balance of the neurological examination is unremarkable.

Accordingly, the claimant has been told by his hematologist (Dr. XXX) that there continues to be phlebitis activity in the left basilic area and mention is made of previous involvement of the left subclavian vein area (?).

INITIAL COMMENT

There are records from Dr. XXX (hematologist) and Dr. XXXXXX (gastroenterologist) that would be helpful at this time.

I have been given two different tasks.

- 1 Evaluate the claimant's left upper arm basilic vein problem (Attorney [REDACTED])
- 2 Evaluate this claimant's musculoskeletal-neuromusculoskeletal issues (SCIF – Specialist Valenti).

Re: XXXXX XXXXXXXXXXXX
[REDACTED]

Page 8

DIAGNOSTIC IMPRESSION

- 1 Occlusive phlebitis, left basilic vein – related to DHE procedure (catheter tube in left basilic vein) - ? current status – see discussion.
- 2 Complex history of headache, dizziness (? syncope ?), seizure, suspected psychological issue (not demonstrated), left greater occipital neuralgia.
- 3 Musculoskeletal issues involving neck, left shoulder, and low back, without striking neurological deficit.

DISCUSSION

The up-to-date data from Dr. XXX and Dr. XXXXXX are needed. I would prefer to get their data rather than order some tests that they probably have already been done.

Relevant to the claimant's musculoskeletal difficulties, neck, left shoulder, and low back, these are more straightforward. The physical findings are positive (but modest rather than severe). There is some question as to whether these are entirely secondary to the [REDACTED] injury, or are there contributions from the [REDACTED] injury, cumulative occupational microtrauma, and anything else (?). If the claimant indeed has active phlebitis in the left basilic vein and possible involvement of the left subclavian vein, these neck, left shoulder, low back issues are in "second position" (less important).

Temporary total disability – The claimant has been off work since the difficulties with the DHE infusion ([REDACTED]).

Of note, the DHE apparently really helped relevant to the head pain issues. There is discussion of giving DHE again with a catheter placed more centrally (PICC line) (?).

Permanent partial disability-MMI – As noted above, the claimant is most probably permanent, stationary, and ratable – MMI – relevant to primarily neck, left shoulder, and low back issues. I am going to ask for the privilege of having an orthopedist or physical medicine specialist QME evaluate the claimant as well, so my ratings will be as accurate as possible relevant to levels of impairment and the causation-apportionment issues. As noted above, the findings are definite but are not severe and are about ready to rate.

Re: XXXXX XXXXXXXXXXXX

[REDACTED]

Page 9

AMA Guides Impairment Rating – This is a complex issue, and some of the questions have not been posed directly to me. It is not clear to me to what extent this claimant's left upper arm-basilic vein-issues are ready to rate (? or not yet ?). His musculoskeletal difficulties (neck, left shoulder and low back) are in line for an AMA Guides rating.

To what extent this claimant's symptoms in the distribution of the left greater occipital nerve can be related to his multiple episodes of head trauma (the bulky helmet – hitting his head against the roof of the plane) needs to be clarified relevant to a rating for headache issues. I do note the claimant has a positive family history of migraine.

Subjective symptoms-complaints – Left upper arm pain, symptoms in neck, left shoulder and low back, head pain.

Objective findings – Impaired range of motion – modest – of neck, left shoulder, and low back. Discomfort and sensory diminution in left occipital area.

Causation – The causation of the claimant's left basilic vein is entirely the DHE procedure, which is a work-related treatment for a work-caused problem. Accordingly, the claimant's basilic vein problem is entirely work-related, without apportionment.

The claimant's neck, left shoulder and low back issues are related to a set of work-related issues (definitely [REDACTED], perhaps [REDACTED], and probably cumulative occupational microtrauma). Orthopedic QME input is needed.

The claimant's headaches are a complex combination of the multitrauma described by the claimant, and migraine susceptibility, plus objective findings (post trauma) in the distribution of the left greater occipital nerve.

Apportionment – As noted above, apportionment for anything other than the DHE treatment for the left basilic vein problem is not indicated.

As noted above, the claimant's neck, left shoulder, and low back difficulties are apportionable to the [REDACTED] injury (on the job) and further clarification is required relevant to the potential role of the [REDACTED] injury and cumulative efforts and events.

Re: XXXXX XXXXXXXXXXXX

[REDACTED]

Page 10

Studies reviewed – Stack of medical records provided at this time (please note I need the newer records) ([REDACTED]).

Studies performed time – Nothing further at this time.

Studies requested – The newer records, especially those of Dr. XXX and Dr. XXXXXX, and those of Dr. XXXXXXXX and anybody else (I think I have the up-to-date records from [REDACTED] headache neurology data).

Research performed at this time – None.

Return to work – Relevant to the [REDACTED] job, probably not. The claimant is finishing up a college education and this will probably lead to opportunities.

Treatment recommended – This is a complex issue. To begin with, I need to know what Dr. XXX thinks should and shouldn't happen relevant to this claimant's basilic vein and related areas.

Conservative treatment is indicated relevant to neck, left shoulder, and low back (findings are definite but not severe, and I do await orthopedic or physical medicine input). Relevant to the headache issue, and noting that the claimant is being treated in the Fresno area and also at UCSF, I refer and defer at this time. Relevant to the neck, low back and left shoulder area, I again await some further orthopedic input.

Further comment – As noted above, I am requesting the privilege of having the claimant seen by a QME orthopedist or physical medicine specialist. I am requesting any further and newer records. I would like to see the claimant back again in about three to six months. At that time hopefully his left arm vein problem will be cleared up, his head pain issue will be more clarified, and his neck, left shoulder and low back issues will be rated by me.

If questions remain or arise, kindly write me back and I will respond immediately.

I certify that I took the complete history from the claimant, conducted the examination, reviewed all available medical records, and composed and drafted the conclusions of this report. The conclusions and opinions within this report are solely mine. I declare under penalty of perjury that the information contained in this report and its attachments, if any, is true and correct to the best of my knowledge and belief, except as to information that I have indicated I received from others. As to that information, I declare under penalty of perjury that the information

Re: XXXXX XXXXXXXXXXXX
[REDACTED]

Page 11

accurately describes the information provided to me and, except as noted herein, that I believe it to be true. In accordance with Labor Code Section 5703(a) (2), there has not been a violation of Labor Code Section 139.3, and the contents of the report are true and correct to the best of my knowledge. This statement is made under penalty of perjury.

Pursuant to 8 Cal. Code Regs. Section 49.2-49.9, I have complied with the requirement for face-to-face time with the client in this evaluation. If necessary, I have discussed apportionment in the body of this report. If I have assigned disability caused by factors other than the industrial injury, that level of disability constitutes the apportionment. The ratio of nonindustrial disability, if any, to all described disability represents my best medical judgment of the percentage of disability caused by the industrial injury and the percentage of disability caused by other factors, as defined in Labor Code Sections 4663 and 4664.

Thanks again, and respectfully,

Michael M. Bronshvag, M.D.
Diplomate in Neurology, ABP&N
Diplomate in Internal Medicine, ABIM
Date of Report: [REDACTED]
[REDACTED]

Sample Report #2

MICHAEL M. BRONSHVAG, M.D.
Diplomate in Neurology, ABP&N
Diplomate in Internal Medicine, ABIM

XXXXX XXXXXX, [REDACTED]
XXXXXXXXXXXXXXXXXXXX XXXX XXXXXXXXXXXXXXXXXXXX
XXXX XXX XXXX
XXXXXX, XX XXXXX

Disability Evaluation Unit
Office of Benefit Determinations
Division of Workers' Compensation

XXXXXXXXXXXXXXXXXX
XXXX XXXXX XXX XXX XXXXXX
XXXXXXXX, XX XXXXX

QUALIFIED MEDICAL EVALUATION ELECTROENCEPHALOGRAM

[REDACTED]

Re XXXXXXXX, XXXXXXXX
Date of Injury: [REDACTED]
Employer: XXXXXX XX XXXXXX
WCAB Case No.: Unknown
Claim No.: XXXXXXXX

Dear Concerned Parties:

XXXXXXXXXXXXXXXXXX was seen for a Qualified Medical Evaluation on [REDACTED], at [REDACTED]
[REDACTED]

Pursuant to 8 Cal. Code of Regulations, Section 9795(b) and (c), this report is submitted as an ML 104-95 Comprehensive Medical-Legal Evaluation involving Extraordinary Circumstances and meets the requirement of four complexity factors. These factors include: (4) 4.50 hours spent on any combination of three of the complexity factors (1)-(3) which shall count as two complexity factors; (6) Addressing the issue of medical causation, which shall count as one complexity factor; (7) Addressing the issue of apportionment, which shall count as one complexity factor.

11030 White Rock Road, Suite 110, Rancho Cordova, CA 95670
Phone: (800) 458-1261 Fax: (916) 920-2515

Re: XXXXXXXX XXXXXXXX

Date: [REDACTED]

Page 2

Time spent in direct face-to-face contact with the claimant was .50 hour. Time spent reviewing records required 2 hours. Time spent on research was 2 hours. Time spent preparing the report was 1.50 hours. Total time spent on this case was 6 hours plus electroencephalogram.

PROBLEM STATEMENT

XXXXXXXX XXXXXXXX is [REDACTED] years old, lives in XXXXXXXX, and worked for the [REDACTED] department - XXXXXXXX XXXXXXXX. He had a stroke in [REDACTED]. The claimant asks me to comment on whether he can go back to his full job or not.

HISTORY of the PRESENT ILLNESS

He is currently doing light rather than full duty (he does phone work and reports). He tells me that he had the onset of difficulties in [REDACTED]. He noted he was having right eye area pain for several days before noting a problem after going off of work on the day in question (of [REDACTED]).

He states he had worked for 9 p.m. to 7:30 a.m., and then was noticing in his driveway, difficulties with the left arm (paralyzed). This problem seemed to remit but he noted that he was having recurrent symptoms daily for a week or so. Symptoms in addition to the left arm problems included fatigue, stuttering, and word finding problems.

Accordingly, this claimant's presentation of difficulties circa [REDACTED] included initially headache behind the right eye for several days, an episode of difficulty in his driveway on [REDACTED] and recurring symptoms for about a week further. The claimant, himself, tells me that he notes that he was in a high stress work environment and he was handling heavy equipment and was required to do long hours of work. He currently denies any overt psychological - psychiatric difficulties.

He is unaware of similar previous or subsequent stroke - like issues and he is unaware of having had a convulsion.

CURRENT COMPLAINTS

The claimant's current status is not alarming. He notes minimal residual symptoms, of this [REDACTED] set of difficulties, and is on the job at modified duties. He does not employ crutches, a cane, or a brace.

He can walk 1 to 4 blocks, climb a few steps, and lift 40 pounds. He has had to curtail job and hobbies because of his residual symptoms.

Re: xxxxxxxx xxxxxxxx

Date: [REDACTED]

Page 3

CURRENT TREATMENT

Plavix, Lipitor, and aspirin. He is under the care of Dr. XXXXX and cardiologist Dr. XXXXX and neurologist XXXXXXXX.

MEDICAL REVIEW OF SYSTEMS

The claimant did not provide a history of previous high blood pressure, diabetes, heart difficulties, or similar types of risk factors. The claimant described to me only minimal smoking and drinking.

Previous surgical history - the claimant had stomach surgery (fundoplication - for GERD symptoms in [REDACTED]. He was hospitalized for pneumonia in [REDACTED].

The claimant has a positive family history of heart disease and hypertension. He, himself, is allergic to penicillin and Bactroban.

JOB DESCRIPTION / EMPLOYMENT HISTORY

As noted above, law enforcement, XXXXXX XXXXXX [REDACTED] [REDACTED] - currently doing lighter - desk - telephone work since the events of [REDACTED].

SOCIAL HISTORY

He is right-handed. He smokes one or no cigars per day, and has a drink no more often than once every two weeks. He denies drug misuse. He is a lifelong California resident, [REDACTED] and has BA and further training. He is able to read and write well. He is skilled in law enforcement. He is on the job (telephone reports at this time). He has a driver's license. He is right-handed.

INITIAL COMMENT

Thus, the claimant's initial presenting symptom, while in his car, was left arm difficulty, which has not persisted, but dizziness, confusion, facial numbness, and problems speaking persisted for at least a week. Also, the claimant had described to me previous right eye pain for days (? significance ?). At this point, I turn my attention to the medical records kindly provided.

RECORDS REVIEW

I review the job description ([REDACTED]). I review the [REDACTED] occupational data. Dr. XXXXXXXX noted the onset of difficulties in the left hand, but he felt that the claimant had

Re: xxxxxxxx xxxxxxxx

Date: [REDACTED]

Page 4

recovered. The imaging study of this claimant (enhanced CT scan) showed multifocal areas of stenosis, especially in the middle cerebral arteries (right greater than left). Patchy - scattered hypo-dense areas were felt to be indicative of infarctions. No evidence of hemorrhagic transformation was described ([REDACTED]). Dr. XXXXXXXX had gotten the history of right-sided head pain. The difficulties when he came home from work are noted. The brain MRI ([REDACTED]) showed two right temporal lobe - parietal lobe abnormalities. The MRA study showed severe right M1 segment stenosis. The medical records previously do not document clear-cut preexisting vascular abnormalities.

PHYSICAL EXAMINATION

My physical examination of this claimant, performed at this time, demonstrates no overt deficits of memory, language function, or overall intelligence, except that the claimant speaks slowly and hesitantly. I do not document, at this time, overt depressive or anxiety data.

The blood pressure is measured at 129/78, and the pulse (fast) is 111. The height is [REDACTED] and the weight is [REDACTED] pounds in a right-handed person. Vision and hearing are grossly normal. Eyes, funduscopic exam, and cranial nerves are normal. ENT exam is normal. Neck shows no abnormality of trachea, veins, or thyroid. Lungs, heart, and pulses are normal. Abdominal and skin examinations are normal.

The musculoskeletal examination - performed at this time - demonstrates no gross or overt derangements.

Relevant to the neurological examination, I do not currently demonstrate clear-cut lateralized sensory or motor deficits at this time. Tone, stance, and speech are normal, and the tendon reflexes are 1+.

Because of actual or possible parenchymal or neurocognitive difficulties, EEG brain wave test is done at this time.

ELECTROENCEPHALOGRAM STUDIES

Please note that I had the benefit of help from technologist XXXXXXXX, who did the actual study and provided me with the data.

EEG - The claimant's basic waking clinical rhythm is a low-voltage fast activity. This is usually a normal (variant) rhythm, but sometimes indicates anxiety. The claimant's basic rhythm is interrupted episodically by slowing into the theta range, which does "not" have a lateralized or

Re: xxxxxxxx xxxxxxxx

Date: [REDACTED]

Page 5

paroxysmal flavor. This accordingly, is a borderline abnormal comment nonspecific basic rhythm.

Hyperventilation and photic stimulation did not demonstrate abnormalities. No clear-cut seizure - dysrhythmic abnormalities are noted. Accordingly, this is a borderline EEG of uncertain cause. Clinical correlation is required.

DIAGNOSTIC IMPRESSION

1. Encephalopathy, most probably ischemic, with description of at least two right-sided lesions compatible with ischemic disease (stroke) - no evidence of hemorrhage. Assuming no other evidence is demonstrated of medical - metabolic - ischemic disease, the possibility exists that the problem is autoimmune or inflammatory, however, the most likely possibility is ischemic disease caused by cerebrovascular arteriosclerotic disease.

2. Status post surgery - fundal - plication for gastroesophageal.

DISCUSSION

This claimant has clear-cut evidence of brain parenchymal difficulty. He is currently on limited duty, and his long-term prognosis is not yet established.

The possibility exists that something other than arteriosclerosis is present.

At the present time, I do not have evidence for heart or great vessel disease.

FURTHER STUDIES

The claimant requires at this time:

1. Current MRA - MRI of brain.
2. He requires EKG, chest x-ray, and a set of chemistries and immunochemistries. A serum homocysteine will be added.

I would like to have the privilege of seeing the claimant back again in two to four months, to try and comment further and fully relevant to the important questions, which include:

- A. What is his prognosis?
- B. What is the causation - apportionment conclusion?

On written approval from the carrier, we will schedule these diagnostic tests.

Re: xxxxxxxx xxxxxxxx

Date: [REDACTED]

Page 6

TEMPORARY TOTAL DISABILITY

The claimant clearly has had some brain impairment, which he appears to be recovering from. It is my understanding that actual work loss has been minimal. The claimant is no longer off of work, but he is doing lighter duties. At the present time, the period of temporary total disability in relationship to the stroke was caused by the stroke.

PERMANENT DISABILITY

Follow up is required

SUBJECTIVE COMPLAINTS

The claimant apparently only has minimal residual difficulty relevant to his [REDACTED] stroke or stroke-like episode.

OBJECTIVE FACTORS

The claimant has apparently largely, if not entirely, improved. However, the abnormal studies from [REDACTED] are of note and the slightly abnormal EEG brain wave test at this time is of note as well. Therefore, the objective findings are, at this time, minimal, but still of some concern.

WORK RESTRICTIONS

The claimant has currently been placed on desk duty. Based on the recent history [REDACTED], and the residual physical findings, this seems reasonable, and I agree with it. I do not at this time feel that the claimant could be returned with safety to his full-time job as a [REDACTED]

AMA IMPAIRMENT RATING

Pending work up.

CAUSATION

Re: xxxxxxxx xxxxxxxx

Date: [REDACTED]

Page 7

As I understand the process and the presumption, the claimant does not, at this time, have evidence of heart disease. He describes long hours and a stressful job. His brain vascular problem has not yet been fully diagnosed (although arteriosclerosis - typical type - seems most likely). I will report further in this regard.

APPORTIONMENT

Apportionment correlates with causation. The issue of causation has not yet been fully determined, and therefore, apportionment is best described - currently - as pending work up.

TREATMENT RECOMMENDATIONS

The claimant is on medications for secondary stroke prophylaxis, and I agree with this choice. I have not found any other or newer diagnosis and therefore, at this time, do not have any other treatment recommendations.

RETURN TO WORK

The claimant is returned to work at [REDACTED] - [REDACTED] - [REDACTED]. Whether he will be able to return to the full range of his [REDACTED] duties or not is a question I do not yet have the answer to.

RESEARCH STUDIES SELECTED

Please note that I have reviewed data on ischemic stroke and inflammatory disorders - see appended articles.

The claimant would also benefit from a lumbar puncture for clarification of inflammatory and infectious issues. Please note that although arteriosclerosis of the vessels serving the brain is common and everything else is rare it is a little unusual for somebody of this young age to be presenting with ischemic disease inside the brain (cerebral vessels) without evidence elsewhere.

I certify that I took the complete history from the patient, conducted the examination, reviewed all available medical records, and composed and drafted the conclusions of this report. The conclusions and opinions within this report are solely mine. I declare under penalty of perjury that the information contained in this report and its attachments, if any, is true and correct to the best of my knowledge and belief, except as to information that I have indicated I received from others. As to that information, I declare under penalty of perjury that the information accurately describes the information provided to me and, except as noted herein, that I believe it to be true. In accordance with Labor Code Section 5703(a) (2), there has not been a violation of Labor Code Section 139.3, and the contents of the report are true and correct to the best of my knowledge. This statement is made under penalty of perjury.

Re: xxxxxxxx xxxxxxxx

Date: [REDACTED]

Page 8

Pursuant to 8 Cal. Code Regs. Section 49.2-49.9, I have complied with the requirement for face-to-face time with the patient in this evaluation. If necessary, I have discussed apportionment in the body of this report. If I have assigned disability caused by factors other than the industrial injury, that level of disability constitutes the apportionment. The ratio of nonindustrial disability, if any, to all described disability represents my best medical judgment of the percentage of disability caused by the industrial injury and the percentage of disability caused by other factors, as defined in Labor Code Section 4663 and 4664.

I further declare under penalty of perjury that the name and qualifications of each person who performed any services in connection with the report, including diagnostic studies, other than clerical preparation, are as follows:

Name Qualifications

XXXXXX XXXXXXXX R.NCS.T (Registered Nerve Conduction Studies Technologist)

Respectfully,

Michael M. Bronshvag, M.D.
Diplomate in Neurology, ABP&N
Diplomate in Internal Medicine, ABIM

Date of Report: [REDACTED]
Signed this [REDACTED], in [REDACTED]

RESEARCH PERFORMED

Please refer to refereed - open source articles I have selected relevant to isolated middle cerebral artery disease, and position dependent cerebral ischemia, and internal carotid - external carotid bypass therapy - therapeutic.

ARTICLES CITED AS RESEARCH FOR THE EVALUATION

J Neurosci Rural Pract. 2012 May;3(2):204-6. doi: 10.4103/0976-3147.98250.

Cerebrogenic tachyarrhythmia in acute stroke.

Kumar AP¹, Babu E, Subrahmanyam D.

Author information

Abstract

The electrocardiac abnormalities following acute stroke are frequent and seen in both ischemic and hemorrhagic stroke. The changes seen in electrocardiogram (ECG) consist of repolarization abnormalities such as ST elevation, ST depression, negative T waves, and QT prolongation. Among tachyarrhythmias, atrial fibrillation is the most common and occurrence of focal atrial tachycardia is very rare though any cardiac arrhythmias can follow acute stroke. We report a case of focal atrial tachycardia following acute ischemic stroke in 50-year-old female without structural heart disease, and their mechanisms and clinical implications.

KEYWORDS:

Atrial tachycardia; atrial fibrillation; insula; ischemic stroke; repolarization abnormality

When Your Heart Rhythm Isn't Normal

In this article

- [Causes and Types of Arrhythmias](#)
- [Symptoms of Arrhythmias](#)
- [Diagnosis of Arrhythmias](#)
- [Treatment of Arrhythmias](#)
- [What Is Electrical Cardioversion?](#)
- [What Is a Pacemaker?](#)
- [What Is an Implantable Cardioverter Defibrillator \(ICD\)?](#)
- [What Is Catheter Ablation?](#)
- [Heart Surgery for Arrhythmias](#)

"Arrhythmia" means your heartbeat is irregular. It doesn't necessarily mean your heart is beating too fast or too slow. It just means it's out of its normal rhythm.

It may feel like your heart skipped a beat, added a beat, is "fluttering," or is beating too fast (which doctors call tachycardia) or too slow (called bradycardia). Or, you might not notice anything, since some arrhythmias are "silent."

Arrhythmias can be an emergency, or they may be harmless. If you feel something unusual happening with your heartbeat, call 911 so doctors can find out why it's happening and what you need to do about it.

Causes and Types of of Arrhythmias

You could have an arrhythmia even if your heart is healthy. Or it could happen because you have:

- [Heart disease](#)

- The wrong balance of electrolytes (such as sodium or potassium) in your blood
- Changes in your heart muscle
- Injury from a heart attack
- Healing process after heart surgery

The many types of arrhythmias include:

Premature atrial contractions. These are early extra beats that start in the heart's upper chambers, called the atria. They are harmless and generally don't need treatment.

Premature ventricular contractions (PVCs). These are among the most common arrhythmias. They're the "skipped heartbeat" we all occasionally feel. They can be related to stress or too much caffeine or nicotine. But sometimes, PVCs can be caused by heart disease or electrolyte imbalance. If you have a lot of PVCs, or symptoms linked to them, see a heart doctor (cardiologist).

Atrial fibrillation. This common irregular heart rhythm causes the upper chambers of the heart to contract abnormally.

Atrial flutter. This is an arrhythmia that's usually more organized and regular than atrial fibrillation. It happens most often in people with heart disease and in the first week after heart surgery. It often changes to atrial fibrillation.

Paroxysmal supraventricular tachycardia (PSVT). A rapid heart rate, usually with a regular rhythm, starting from above the heart's lower chambers, or ventricles. PSVT begins and ends suddenly.

Accessory pathway tachycardias. You can get a rapid heart rate because there is an extra pathway between the heart's upper and lower chambers. It's just like if there was an extra road on your way home as well as your usual route, so cars can move around faster. When that happens in your heart, it can cause a fast heart rhythm, which doctors call tachycardia. The impulses that control your heart rhythm travel around the heart very quickly, making it beat unusually fast.

Causes and Types of of Arrhythmias continued...

AV nodal reentrant tachycardia. This is another type of fast heartbeat. It's caused by there being an extra pathway through a part of the heart called the AV node. It can cause heart palpitations, fainting, or heart failure. In some cases, you can stop it simply by breathing in and bearing down. Some drugs can also stop this heart rhythm.

Ventricular tachycardia (V-tach). A rapid heart rhythm starting from the heart's lower chambers. Because the heart is beating too fast, it can't fill up with enough blood. This can be a serious arrhythmia – especially in people with heart disease – and it may be linked to other symptoms.

Ventricular fibrillation. This happens when the heart's lower chambers quiver and can't contract or pump blood to the body. This is a medical emergency that must be treated with CPR and defibrillation as soon as possible.

Long QT syndrome. This may cause potentially dangerous arrhythmias and sudden death. Doctors can treat it with medications or devices called defibrillators.

Bradycardias. These are slow heart rhythms, which may be due to disease in the heart's electrical system. If you experience this, call your doctor.

Sinus node dysfunction. This slow heart rhythm is due to a problem with the heart's sinus node. Some people with this type of arrhythmia need a pacemaker.

Heart block. There is a delay or a complete block of the electrical impulse as it travels from the heart's sinus node to its lower chambers. The heart may beat irregularly and, often, more slowly. In serious cases, you'd get a pacemaker.

Symptoms of Arrhythmias

An arrhythmia can be silent, meaning you don't notice any symptoms. A doctor can find an irregular heartbeat during a physical exam by taking your pulse or through an electrocardiogram (ECG or EKG).

If you do have symptoms, they may include:

- Palpitations (a feeling of skipped heart beats, fluttering or "flip-flops")
- Pounding in your chest
- Dizziness or feeling light-headed
- Fainting
- Shortness of breath
- Chest pain or tightness
- Weakness or fatigue (feeling very tired)

Diagnosis of Arrhythmias

To diagnose an arrhythmia or find its cause, doctors use tests including:

Electrocardiogram – Also called an EKG or ECG, this test records the electrical activity of your heart. You wear small electrode patches on your chest, arms, and legs for the quick, painless test, which you take in your doctor's office.

Holter monitor -- This is a portable EKG that you'll use for 1 to 2 days. You'll have electrodes taped to your skin. It's painless and you can do everything but shower while wearing the electrodes.

Event monitor -- If your symptoms don't happen often, your doctor may suggest you wear one of these, usually for about a month. This is a device that, when you push a button, will record and store your heart's electrical activity for a few minutes. Each time you notice symptoms, you should try to get a reading on the monitor. Your doctor will interpret the results.

Stress test -- There are different kinds of stress tests. The goal is to check how much stress your heart can manage before having a heart rhythm problem or not getting enough blood flow to the heart. For the most common type of stress test, you'll walk on a treadmill or pedal a stationary bike at increasing levels of difficulty while you're getting an EKG and getting your heart rate and blood pressure monitored.

Echocardiogram -- This test uses ultrasound to evaluate heart muscle and heart valves.

Cardiac catheterization -- Your doctor will insert a long, thin tube, called a catheter, into a blood vessel in your arm or leg. She will guide it to your heart with help from a special X-ray machine. Then she'll inject dye through the catheter to help make X-ray videos of your heart's valves, coronary arteries, and chambers.

Electrophysiology study -- This test records your heart's electrical activities and pathways. It can help find out what's causing heart rhythm problems and find the best treatment for you. During the test, your doctor will safely reproduce your abnormal heart rhythm and then may give you different medications to see which controls it best, or to see what procedure or device you need to treat it.

Head-up tilt table test -- Doctors use this test to find out what's causing fainting spells. It measures the difference in heart rate and blood pressure when you're standing up or lying down. You'll get this test in a lab. You'll lie on a stretcher, tilted at different angles while you're getting an EKG and specialists are checking your blood pressure and oxygen level.

Treatment of Arrhythmias

Treatment depends on the type and seriousness of your arrhythmia. Some people with arrhythmias don't need treatment. Others may need medication, making lifestyle changes, and surgery.

Drugs that treat arrhythmias include:

Antiarrhythmic drugs. These drugs control heart rhythm and include beta-blockers and calcium channel blockers.

Anticoagulant or antiplatelet therapy. These drugs lower the risk of blood clots and stroke. These include the blood thinner warfarin (Coumadin) or aspirin. Other blood thinners called apixaban (Eliquis), dabigatran (Pradaxa), edoxaban (Savaysa), and rivaroxaban (Xarelto) have been approved to prevent stroke in people with atrial fibrillation.

Everyone is different. Finding the medicine and dose that works best for you may take some time.

- If you notice that your arrhythmia happens more often with certain activities, stop doing them.
- If you smoke, stop.
- Limit alcohol to no more than one drink a day for women, and two drinks a day for men.
- Limit or stop using caffeine.
- Don't use cough and cold medications that have stimulants. Read the label and ask your doctor or pharmacist what medication would be best for you.

What Is Electrical Cardioversion?

If drugs can't control a persistent irregular heart rhythm (such as atrial fibrillation), you might need cardioversion. For this, doctors, give you a short-acting anesthesia, then deliver an electrical shock to your chest wall to allow the normal rhythm to restart.

What Is a Pacemaker?

This device sends small electrical impulses to the heart muscle to keep a safe heart rate. The pacemaker has a pulse generator (which houses the battery and a tiny computer) and wires that send impulses from the pulse generator to the heart muscle.

What Is an Implantable Cardioverter Defibrillator (ICD)?

Doctors mainly use ICDs to treat ventricular tachycardia and ventricular fibrillation, two life-threatening heart rhythms.

The ICD constantly tracks the heart rhythm. When it detects a very fast, abnormal heart rhythm, it delivers an electric shock to the heart muscle to cause the heart to beat in a normal rhythm again. There are several ways the ICD can be used to restore normal heart rhythm. They include:

- **Anti-tachycardia pacing (ATP).** When the heart beats too fast, you get a series of small electrical impulses to the heart muscle to restore a normal heart rate and rhythm.
- **Cardioversion.** You may get a low-energy shock at the same time as the heart beats to restore normal heart rhythm.
- **Defibrillation.** When the heart is beating dangerously fast or irregularly, the heart muscle gets a higher-energy shock to restore a normal rhythm.
- **Anti-bradycardia pacing.** Many ICDs provide back-up pacing to maintain heart rhythm if it slows too much.

What Is Catheter Ablation?

You can think of this procedure as rewiring to fix an electrical problem within the heart.

The doctor will insert a catheter through the leg. The catheter delivers high-frequency electrical energy to a small area inside the heart that causes the abnormal heart rhythm. This energy "disconnects" the pathway of the abnormal rhythm.

Doctors use ablation to treat most PSVTs, atrial flutter, atrial fibrillation, and some atrial and ventricular tachycardias. Some people also need other procedures.

Heart Surgery for Arrhythmias

The Maze procedure is a type of surgery used to correct atrial fibrillation. During this procedure, the surgeon makes a series, or "maze," of cuts in the heart's upper chambers. The goal is to keep the heart's electrical impulses only on certain pathways. Some people may need a pacemaker afterward.

WebMD Medical Reference

The Demise of EC-IC Bypass Surgery

Seemant Chaturvedi, MD reviewing Powers WJ et al. JAMA 2011 Nov 9.

Extracranial-intracranial bypass plus medical therapy for symptomatic carotid occlusion was no more effective than medical therapy alone at preventing stroke and early mortality in a randomized trial.

During the 1980s, a large trial showed that extracranial-to-intracranial (EC-IC) arterial bypass surgery was ineffective for stroke prevention. A lingering question was whether patients with objective evidence of hemispheric hypoperfusion would benefit from surgery. The Carotid Occlusion Surgery Study (COSS) was undertaken to study patients with symptomatic carotid occlusion and evidence on positron emission tomography of increased oxygen extraction ipsilateral to the occlusion, a marker of hemodynamic cerebral ischemia. Participants were randomized to optimal medical therapy with or without EC-IC surgery. The primary outcome was the composite of stroke or death within 30 days after either surgery or randomization, and ipsilateral stroke within 2 years of randomization.

The study was terminated early for futility, when 195 patients had been randomized. At the time of the study's termination, there was only a 2% chance for surgery to be proven effective if the trial were carried to completion. The primary outcome occurred in 21.0% of the surgical group and 22.7% of the nonsurgical group, a nonsignificant difference. Thirty-day rates of ipsilateral stroke were 14.4% in the surgical group and 2.0% in the nonsurgical group. Graft patency was 98% at 30 days and 96% at last follow-up.

COMMENT

In planning the study, the investigators expected a 40% rate of stroke in the nonsurgical group. The fact that the actual rate was about half that is consistent with a recent study of optimal medical therapy for intracranial stenosis (JW Neurol Sep 20 2011), in which the medically treated group did better than expected.

The current findings reinforce the need for aggressive medical therapy for optimal stroke prevention. Only 71% of the nonsurgical group had an LDL level <100 mg/dL at final follow-up, suggesting that a stroke rate even lower than that observed in these medically treated patients is achievable. This study should also stimulate a new trial to investigate aggressive medical therapy for extracranial carotid stenosis. For EC-IC bypass surgery, the door should be closed, with a padlock this time.

Cerebral bypass surgery

Overview

A cerebral bypass is a surgical procedure performed to restore, or "revascularize," blood flow to the brain. A cerebral bypass is the brain's equivalent of a coronary bypass in the heart. The surgery involves connecting a blood vessel from outside the brain to a vessel inside the brain to reroute blood flow around an artery that is narrowed, blocked, or damaged. The main goal of bypass surgery is to restore blood supply to the brain and prevent strokes.

What is cerebral bypass surgery?

Blood carries nutrients and oxygen to the brain through four main arteries: the right and left carotid arteries and the right and left vertebral arteries. Poor delivery of blood flow reduces the brain's ability to function. Called cerebrovascular insufficiency, a lack of blood supply leads to transient ischemic attacks (TIA), stroke, and ultimately brain cell death. In a cerebral artery bypass, the surgeon reroutes blood flow around a blocked or damaged artery to improve or restore blood flow to an oxygen-deprived (ischemic) area of the brain. A cerebral bypass can be performed in a variety of ways depending on where the blockage has occurred, the underlying condition being treated, and the size of the brain area to be revascularized. In general, there are two types of bypasses:

The first type uses a vessel graft – a length of artery or vein harvested from somewhere else in the body. The graft is connected above and below the blocked artery so that blood flow is rerouted (bypassed) through the graft. Common vessels used as a graft are the saphenous vein in the leg or the radial or ulnar arteries in the arm. A separate incision is required to harvest the graft. Next, one end of the graft is connected to the external carotid artery (ECA) in the neck and then tunneled under the skin in front of the ear to the scalp. A hole is cut in the skull through which the graft is passed and connected to an artery in the brain. This method is typically used when a large (high-flow) artery is affected or needs to be sacrificed to treat a tumor or aneurysm.

The other type does not use a vessel graft but a healthy donor artery that flows in the scalp or face. The donor artery is detached from its normal position on one end, redirected to the inside of the skull, and connected to an artery on the surface of the brain (Fig. 1). The scalp artery now supplies blood to the brain and bypasses the blocked or damaged vessel. This method is typically used when a smaller (low-flow) artery has narrowed and is incapable of delivering enough blood to the brain.

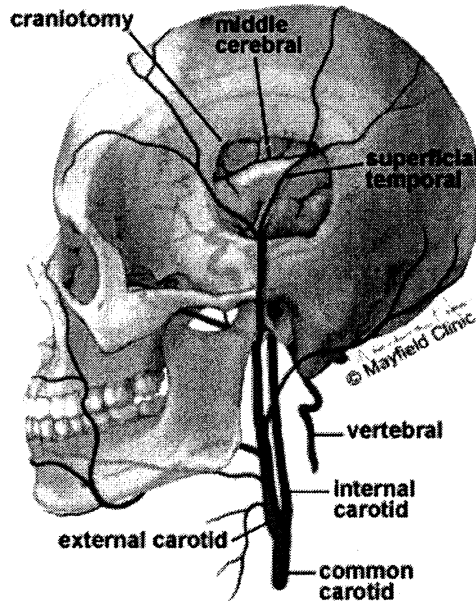

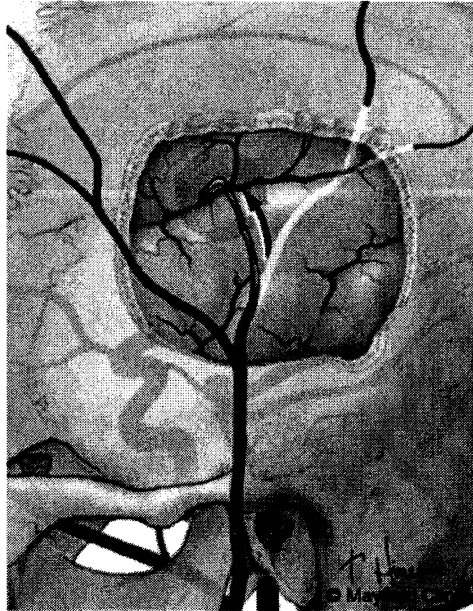


Figure 1. In a cerebral bypass surgery, an artery from outside the skull is connected to an artery inside the skull through a craniotomy. A donor artery, usually the superficial temporal artery (STA), is freed from its normal position on the scalp and connected to the middle cerebral artery (MCA) on the surface of the brain. The most common type of bypass is the STA-MCA (superficial temporal artery to middle cerebral artery) bypass. The superficial temporal artery (STA) normally provides blood to the face and scalp. You can feel the pulse of the STA in front of your ear. The middle cerebral artery (MCA) normally provides blood to the frontal, temporal and parietal lobes of the brain. Blood flow through the MCA is often reduced when narrowing of the internal carotid artery occurs. In an STA-MCA bypass, the STA (donor vessel) is rerouted from the scalp, passed through a hole in the skull, and connected to the MCA (recipient vessel) above the blockage to restore blood flow to the brain. If the STA is too small or unsuitable, another vessel such as the occipital artery may be used.

Both types of bypasses require creating a hole in the skull to pass the vessel graft or scalp donor artery from outside the skull to the cerebral artery inside the skull. Thus, this surgery is also called an extracranial-intracranial bypass (EC-IC bypass).

Who is a candidate?

You may be a candidate for a cerebral bypass if you have:

- an aneurysm, tumor, or atherosclerotic plaque that is not treatable by endovascular or other means
- failure of medication to control TIA symptoms or stroke
- imaging tests (angiogram, CTA, MRA) that show arterial stenosis or occlusion
- cerebral blood flow studies (CT perfusion, PET, SPECT) that show arterial stenosis is causing insufficient blood flow to the brain

Cerebral bypass may be helpful in restoring blood flow and reducing the risk of stroke in conditions such as:

- **Moyamoya disease:** a narrowing of the internal carotid arteries at the base of the brain that can cause multiple strokes or hemorrhages. To compensate for the narrowing arteries, the brain creates collateral blood vessels in an attempt to deliver oxygen-rich blood to deprived areas of the brain. A bypass can restore blood flow to the brain and prevent future strokes.
- **Aneurysm:** a bulge or ballooning of an artery wall. Some giant, fusiform, or dissecting aneurysms cannot be treated with surgical clipping or endovascular coiling. In such cases, the parent artery must be sacrificed and the blood flow bypassed for the aneurysm to be effectively treated.
- **Skull base tumor:** a tumor can grow where the major vessels enter the skull and surround or invade the artery. Removing the tumor may require sacrificing the encased artery and bypassing the blood flow.
- **Carotid artery stenosis or occlusion:** a narrowing or blockage of the carotid artery in the neck caused by atherosclerotic plaque deposits in the vessel wall.
- **Intracranial arterial stenosis:** a narrowing or blockage of an artery inside the skull that supplies blood

Tilt-Table Testing

• Author: James V Talano, MD, MBA; Chief Editor: Karlheinz Peter, MD, PhD [more...](#)

• [Overview](#)

• [Periprocedural Care](#)

• [Technique](#)

• [Medication](#)

• [Background](#)

• [Indications](#)

• [Contraindications](#)

• [Technical Considerations](#)

Updated: Nov 20, 2014

• [Outcomes](#)

• [Show All](#)

[Multimedia Library](#)

[Tables](#)

[References](#)

[Background](#)

The tilt-table test is a simple, noninvasive, and informative test first described in 1986 as a diagnostic tool for patients with syncope of unknown origin.²¹ It is usually performed in hospital electrophysiology departments with the endpoint of reproducing syncope and subsequent appropriate therapy.

The causes of syncope have been divided into 6 major categories, as listed below.²² After a careful history and physical examination, tilt-table testing is particularly helpful in confirmation of the etiology of syncope dysfunction of the autonomic nervous system, encompassing primary or secondary dysautonomias, postural orthostatic tachycardia syndrome (POTS), and vasodepressor or vasovagal syncope. Other venues of investigation, such as a 12-lead electrocardiogram, orthostatic blood pressure readings, Holter/event recording, serum glucose and electrolytes, [echocardiography](#), and psychiatric and/or neurology consultation should be considered prior to tilt-table testing to rule out malignant dysrhythmic, metabolic, cardiac mechanical, or psychological/neurological etiologies of syncope.²³

The 6 major categories of syncopal etiologies ²²

Neurological disorders

• Vertebrobasilar transient ischemic attacks

• [Subclavian steal syndrome](#)

• [Normal pressure hydrocephalus](#)

• Seizure disorders

Metabolic disorders

• Hypoxia

• Hyperventilation

• [Hypoglycemia](#)

Mechanical heart disease

• [Aortic stenosis](#)

• [Mitral stenosis](#)

• Global ischemia

• Aortic dissection

• Pulmonic dissection

• Obstructive cardiomyopathy

• Left atrial myxoma

• Prosthetic valve dysfunction

• Pulmonary embolus

• Pulmonary hypertension

Cardiac arrhythmias/brady arrhythmias/tachyarrhythmias

• Bradycardia/pauses

• Sinus node dysfunction

• AV conduction disease

Psychiatric disorders

• Panic attacks

• Hysteria

Autonomic Nervous System Dysfunction

• Primary and secondary dysautonomias

• Postural orthostatic tachycardia syndrome (POTS)

• Postural orthostatic hypotension

• Vasodepressor or vasovagal syncope

Indications

Consider tilt-table testing in patients with signs or symptoms suggestive of orthostatic hypotension, vasodepressor or vasovagal syncope, postural orthostatic tachycardia, or when other causes of syncope have been eliminated. In general, consider tilt-table testing for patients with the following issues:

• Hypotension (unexplained)

• Tachycardia when standing

• Pallor when upright

• Orthostatic palpitations

• Dizziness (unexplained)

• Lightheadedness

• History of frequent unexplained falls

• History of episodes of fainting or loss of consciousness

The ACC expert consensus document for tilt-table testing including indications was first published in 1996.²⁴ The European Society of Cardiology formed a taskforce to update guidelines for the diagnosis and management of syncope in 2001, which was revised in 2009.²⁵ It includes indications for tilt-table testing with classes of recommendation and levels of evidence (see Table 1).

Table 1. European Society of Cardiology 2009 Indications for Tilt-Table Testing²⁵[\(Open Table in a new window\)](#)

Recommendation	Class	Level
Tilt table is indicated in the case of an unexplained single syncopal episode in high-risk settings (eg, occurrence of, or potential risk of physical injury or with occupational implications) or recurrent episodes in the absence of organic heart disease, after cardiac causes of syncope have been excluded	I	B
Tilt testing is indicated when it is of clinical value to demonstrate susceptibility to reflex syncope to the patient	I	C
Tilt testing should be considered to discriminate between reflex and orthostatic hypotensive syncope	IIa	C
Tilt testing may be considered for differentiating syncope with jerking movement from epilepsy	IIb	C
Tilt testing may be considered for evaluating patients with recurrent unexplained falls	IIb	C
Tilt testing may be indicated for evaluating patients with frequent syncope and psychiatric disease	IIb	C
Tilt testing is not recommended for assessment of treatment	III	B
Isoproterenol tilt testing is contraindicated in patients with ischemic heart disease	III	C

Contraindications

Contraindications to tilt-table testing include the following:²⁵

• Coma

- Feeble patient unable to stand
- Lower extremity fractures
- Severe anemia
- Recent stroke (within seven days)
- Recent myocardial infarction
- Severe proximal cerebral or coronary arterial disease
- Critical mitral or aortic stenosis
- Left ventricular outflow tract obstruction
- Hypotensive shock
- Tachyarrhythmias
- Severe metabolic acidosis
- Electrolyte imbalance
- End-stage renal failure
- Severe heart failure

Technical Considerations

Complication Prevention

Avoid invasive intra-arterial blood pressure monitoring during tilt-table testing because catheterization may provoke a vasovagal reaction. Use a manual sphygmomanometer or digital plethysmography.²³

Outcomes

Generally tilt-table testing is safe, but complications may occur related to decreased perfusion of the heart, including the following:

- Electrocardiographic changes of transient myocardial ischemia with or without angina.
 - Vasospasm with isoproterenol administration.²³
 - Occasionally, cardiac arrhythmias result in termination of the test, such as advanced atrioventricular block (second or third degree), severe bradycardia or pauses, atrial fibrillation, or tachyarrhythmias.
- Complications may also occur related to decreased perfusion of the brain, including the following :
- Seizures from prolonged hypotension (this is a transient phenomenon and not indicative of a seizure disorder)
 - Rarely, transient ischemic attacks or strokes occur.
 - Transient mental confusion can occur.
 - Patients may also experience nonspecific symptoms such as nausea or anxiety.

Tilt-Table Testing

Author: James V Talano, MD, MBA; Chief Editor: Karlheinz Petar, MD, PhD [more...](#)

[Overview](#)

[Periprocedural Care](#)

[Technique](#)

[Medication](#)

Updated: Nov 20, 2014

[Background](#)

[Indications](#)

[Contraindications](#)

[Technical Considerations](#)

[Outcomes](#)

[Show All](#)

[Multimedia Library](#)

[Tables](#)

[References](#)

[Background](#)

The tilt-table test is a simple, noninvasive, and informative test first described in 1986 as a diagnostic tool for patients with syncope of unknown origin.²⁴ It is usually performed in hospital electrophysiology departments with the endpoint of reproducing syncope and subsequent appropriate therapy.

The causes of syncope have been divided into 6 major categories, as listed below.²⁵ After a careful history and physical examination, tilt-table testing is particularly helpful in confirmation of the etiology of syncope dysfunction of the autonomic nervous system, encompassing primary or secondary dysautonomias, postural orthostatic tachycardia syndrome (POTS), and vasodepressor or vasovagal syncope. Other venues of investigation, such as a 12-lead electrocardiogram, orthostatic blood pressure readings, Holter/event recording, serum glucose and electrolytes, echocardiography, and psychiatric and/or neurology consultation should be considered prior to tilt-table testing to rule out malignant dysrhythmic, metabolic, cardiac mechanical, or psychological/neurological etiologies of syncope.²⁶

The 6 major categories of syncopal etiologies ²⁵

Neurological disorders

- Vertebrobasilar transient ischemic attacks
- [Subclavian steal syndrome](#)
- [Normal pressure hydrocephalus](#)
- Seizure disorders

Metabolic disorders

- Hypoxia
- Hyperventilation
- [Hypoglycemia](#)

Mechanical heart disease

- [Aortic stenosis](#)
- [Mitral stenosis](#)
- Global ischemia

- Aortic dissection
- Pulmonic dissection
- Obstructive cardiomyopathy
- Left atrial myxoma
- Prosthetic valve dysfunction
- Pulmonary embolus
- Pulmonary hypertension

Cardiac arrhythmias/brady arrhythmias/tachyarrhythmias

- Bradycardia/pauses
- Sinus node dysfunction
- AV conduction disease

Psychiatric disorders

- Panic attacks
- Hysteria

Autonomic Nervous System Dysfunction

- Primary and secondary dysautonomias
- Postural orthostatic tachycardia syndrome (POTS)
- Postural orthostatic hypotension
- Vasodepressor or vasovagal syncope

Indications

Consider tilt-table testing in patients with signs or symptoms suggestive of orthostatic hypotension, vasodepressor or vasovagal syncope, postural orthostatic tachycardia, or when other causes of syncope have been eliminated. In general, consider tilt-table testing for patients with the following issues:

- Hypotension (unexplained)
- Tachycardia when standing
- Pallor when upright
- Orthostatic palpitations
- Dizziness (unexplained)
- Lightheadedness
- History of frequent unexplained falls
- History of episodes of fainting or loss of consciousness

The ACC expert consensus document for tilt-table testing including indications was first published in 1996.¹⁰ The European Society of Cardiology formed a taskforce to update guidelines for the diagnosis and management of syncope in 2001, which was revised in 2009.¹¹ It includes indications for tilt-table testing with classes of recommendation and levels of evidence (see Table 1).

Table 1. European Society of Cardiology 2009 Indications for Tilt-Table Testing¹¹[\(Open Table in a new window\)](#)

Recommendation	Class	Level
Tilt table is indicated in the case of an unexplained single syncope episode in high-risk settings (eg, occurrence of, or potential risk of physical injury or with occupational implications) or recurrent episodes in the absence of organic heart disease, after cardiac causes of syncope have been excluded	I	B
Tilt testing is indicated when it is of critical value to demonstrate susceptibility to reflex syncope in the patient	II	C
Tilt testing should be considered to differentiate syncope with jerking movements from epilepsy	IIIa	C
Tilt testing may be considered for evaluating patients with frequent syncope and psychiatric disease	IIIb	C
Tilt testing is not recommended for assessment of treatment	III	B
Tilt testing may be indicated for evaluating patients with recurrent unexplained falls	IIIa	C
Tilt testing is contraindicated in patients with ischemic heart disease	III	C

Contraindications

Contraindications to tilt-table testing include the following:¹²

- Coma
- Feeble patient unable to stand
- Lower extremity fractures
- Severe anemia
- Recent stroke (within seven days)
- Recent myocardial infarction
- Severe proximal cerebral or coronary arterial disease
- Critical mitral or aortic stenosis
- Left ventricular outflow tract obstruction
- Hypotensive shock
- Tachyarrhythmias
- Severe metabolic acidosis
- Electrolyte imbalance
- End-stage renal failure
- Severe heart failure

Technical Considerations

Complication Prevention

Avoid invasive intra-arterial blood pressure monitoring during tilt-table testing because catheterization may provoke a vasovagal reaction. Use a manual sphygmomanometer or digital plethysmography.¹³

Outcomes

Generally tilt-table testing is safe, but complications may occur related to decreased perfusion of the heart, including the following:

- Electrocardiographic changes of transient myocardial ischemia with or without angina.
- Vasospasm with isoproterenol administration.¹⁴
- Occasionally, cardiac arrhythmias result in termination of the test, such as advanced atrioventricular block (second or third degree), severe bradycardia or pauses, atrial fibrillation, or tachyarrhythmias.

Complications may also occur related to decreased perfusion of the brain, including the following :

- Seizures from prolonged hypotension (this is a transient phenomenon and not indicative of a seizure disorder)

- Rarely, transient ischemic attacks or strokes occur.
- Transient mental confusion can occur.
- Patients may also experience nonspecific symptoms such as nausea or anxiety.

ARTICLES

Atherosclerotic disease of the middle cerebral artery.

1. J Bogossianovky.
2. H J Barnett.
3. A J Fox.
4. V C Hachinski and
5. W Taylor

Abstract

Three hundred and fifty-two patients with atherosclerotic middle cerebral artery stenosis (MCAS, 53%) or occlusion (MCAO, 47%) have been systematically studied. The study involved all patients entered into the ECIC Bypass Study with isolated MCA disease or a tandem lesion predominating in the MCA ipsilateral to the ischemic events (18 patients with a tandem lesion of greater magnitude in the internal carotid artery were not included). The Asian patients represented 58% of all Asians entered into the ECIC Bypass Study, whereas the white patients represented 18% of all whites and the black patients 34% of all blacks. Isolated TIAs were less frequent in MCAO (12%) than in MCAS (34%). Warning TIAs before a stroke occurred in one third of the cases. Presentation with stroke or isolated TIA was not influenced by sex, age, level of MCA obstruction, collateral circulation nor associated carotid disease. In MCAS, no major difference in presentation was found between severe and moderate stenosis. Pure motor hemiparesis occurred in 1.5% and pure sensory stroke in 2% of the patients with stroke and 30% of the MCA territory infarcts were small and limited to the lenticalcapsular area, confirming that so-called lacunar infarcts may be due to large vessel disease. During follow-up (42 months) of 164 medically-treated patients, further cerebrovascular events (TIA and stroke) occurred in 11.7% of the patients per year. In MCAO the stroke rate was 10.1% per patient-year and the ipsilateral infarct rate was 7.1% per patient-year. In MCAS, the stroke rate was 9.5% per patient-year and the ipsilateral stroke rate was 7.8% per patient-year. (ABSTRACT TRUNCATED AT 250 WORDS)

Neurology. 1985 Jul;35(7):975-82.

Occlusive disease of the middle cerebral artery.

Caplan L, Babikian V, Helgason C, Hier DB, DeWitt D, Patel D, Stein R.

Abstract

We studied 20 patients with severe occlusive disease of the mainstem middle cerebral artery (MCA) or its major division branches, and 25 patients with internal carotid artery (ICA) disease. MCA disease patients were more often black, female, younger, and had fewer TIAs than the ICA disease patients. Neurologic signs in patients with MCA disease evolved progressively during days to weeks, whereas ICA disease patients more often had an acute onset of nonprogressive deficits. CT commonly showed restricted subcortical or wedge-shaped infarcts in MCA disease patients. All MCA disease patients had stroke, but 40% of ICA disease patients had no infarction. MCA lesions usually affected the mainstem MCA or its major superior division. Patients with MCA disease seldom had recurrent ischemia in the same vascular territory as the stroke and had a low incidence of subsequent cardiac death.

PMID:

J Neurol Neurosurg Psychiatry. 2004 May; 75(5): 727-732.

doi: [10.1136/jnnp.2003.022574](https://doi.org/10.1136/jnnp.2003.022574)

PMCID: PMC1763587

Isolated middle cerebral artery disease: clinical and neuroradiological features depending on the pathogenesis

P Lee, S Oh, O Bang, I Joo, and K Huh

Author information ► Copyright and License information ►

This article has been cited by other articles in PMC.

MICHAEL M. BRONSHVAG, M.D.
Diplomate in Neurology, ABP&N
Diplomate in Internal Medicine, ABIM

Supplemental
RPT
SAMPLE #2

XXXXXX XXXXXX, Adjuster
XXXXXX XXXXXX XXXXXXXXXXXXX
XXXX XXX XXXX
XXXXXX, XX XXXXX

XXXXXX XXXXXXXX, Esq.
Law Offices of XXXXXXXXX X. XXXXXXXX
XXXX XXXX XXXXX XXXXXX, XXXXX XXX
XXXXXX XXX, XX XXXXX-XXXX

XXXXXXX X. XXXX, Esq.
XXX XXX XXXXXXXX XX XXXXXXX X XXXX.
XXXX XXXXXXX XXXXXXX, XXXXX XXX
XXXXXX, XX XXXXX

QUALIFIED MEDICAL REEVALUATION

Re: XXXXXXX, XXXXXXX
Dates of Injury: [REDACTED] to [REDACTED]
Employer: XXXXXX XX XXXXXX (XXXXXXXXXXXXXXXXXX)
EAMS #s: XXXXXXXXXXX, Unassigned
Claim #s: XXXXXXX, XXXXXXX

Dear All:

XXXXXXXX XXXXXXX was seen for a Qualified Medical Reevaluation on [REDACTED]
at XXXX XXXXXX XXXXXX XXXXX XXX, XXXXXX, XXXXXXXXXXXX XXXXX.

Under penalty of perjury, this report is submitted pursuant to 8 Cal. Code Regs. Section 9795(b) & (c) as a ML-104-95 Comprehensive Medical Legal Evaluation Involving Extraordinary Circumstances and meets the requirement of four complexity factors. These include:
(5) 6+ hours spent on any combination of three of the complexity factors (1)-(3) which shall count as 3 complexity factors;
(6) Addressing the issue of medical causation, which shall count as one complexity factor

Re: XXXXXXXX XXXXXXXX

Date: [REDACTED]

Page 2

Time spent in direct, face to face contact was 45 minutes. Time spent reviewing records required 240 minutes. Time spent on research was 120 minutes. Time spent preparing the report was 120 minutes. Total time spent on this case was 525 minutes plus EEG.

INTRODUCTION

As you will note, I have seen the claimant previously. I, at this time, turn my attention to the [REDACTED] Joint Panel Qualified Medical Examination Letter - thank you.

As you will note, I had seen the claimant in [REDACTED] and wrote an initial report and then in [REDACTED] supplemental. Mention is made of two dates of injury ([REDACTED] - stroke, and cumulative issue from [REDACTED] through [REDACTED] (stroke, heart trouble, PVC's, headaches, bilateral finger numbness, right wrist pain, upper back pain, lower back pain, bilateral hip pain, bilateral knee pain, ankle pain, GERD, hiatal hernia, bradycardia, and sleep problems).

It is stated that this cumulative trauma claim has been denied. It is stated that the claimant will be evaluated separately for orthopaedic issues.

The claimant tells me that he has not worked since the spring of [REDACTED]. He tells me that he is weak on the left side of his body. He is sensitive to light. He has had palpitations. He sleeps restlessly and has been provided with positive pressure (CPAP), which appeared to help his PVC's.

HISTORY OF PRESENT ILLNESS

The claimant had initially presented for stroke issues with a date of [REDACTED]. He states that his problems included a high-stress work environment, heavy equipment issues, and prolonged work hours.

He notes that a loop recorder for cardiac rhythms was provided and he is not certain as to what it did and did not show. As you will note, when I saw the claimant in [REDACTED], in [REDACTED], I took note of his stroke or stroke-like episode of [REDACTED]. I noted that the claimant had been placed on desk duty, and I personally was not enthusiastic as of [REDACTED] to send him back to his full job as a [REDACTED]. I took note of secondary stroke prophylaxis. I noted that the initial event of [REDACTED] was probably an ischemic stroke-like event. The imaging study demonstrated two right sided brain lesions compatible with ischemic disease - stroke, and no evidence of hemorrhage. I felt the most likely possibility was ischemic disease caused by cardiovascular - cerebrovascular arteriosclerotic disease.

Re: XXXXXXXX XXXXXXXX

Date: [REDACTED]

Page 3

It took note of the fundal - plication in [REDACTED] for treatment of gastroesophageal reflux issues. I had noted that the claimant had clear-cut evidenced of brain parenchymal difficulty. I noted that the MRI of the brain performed without and with contrast in [REDACTED] demonstrated the right temporal and parietal infarctions - no acute abnormalities. I noted that the EKG was borderline abnormal relevant to sinus bradycardia. His homocysteine level (sometimes a stroke indicator) was high - normal and the ANA was normal. I felt that the claimant should be examined by a QME cardiologist to determine to what extent the next step should be taken. My review of this and my talking to the claimant indicates that a loop device had been provided in [REDACTED]. I note that he was provided with CPAP therapy in [REDACTED], which seemed to improve his PVC's (premature ventricular contractions).

CURRENT TREATMENT

The claimant is currently being treated with aspirin and Dexilant, Plavix had been discontinued.

The notes of the claimant's Psychiatric Doctor - XXXXXXXXXX - is noted.

MEDICAL REVIEW OF SYSTEMS

Apart from as noted above, the claimant does not provide a positive history of lung or heart disease, high blood pressure, or diabetes. He denies or is unaware of kidney or liver disease, gastrointestinal problems, weight loss or anemia. I, again, took note of the [REDACTED] fundoplication. The claimant had been treated for pneumonia in [REDACTED]

Accordingly, as I approach the balance of this evaluation, the issues appear to be the event of [REDACTED] which certainly sounds like ischemic brain disease, presumably embolic from the heart or involving middle cerebral artery, plus mention of slow pulse and arrhythmia, plus taking note of CPAP treatment for sleep apnea and noting the fundal plication surgery of [REDACTED]

The medical records state that the actual stroke was in [REDACTED] in ([REDACTED]) [REDACTED] but symptoms apparently stuttered in [REDACTED]. The more recent efforts of attorneys Epperly and Lusk are noted.

JOB DESCRIPTION

As noted previously - [REDACTED] XXXXXXX XXXXXXX between [REDACTED] and [REDACTED] - apparently the last four months at [REDACTED]

SOCIAL HISTORY

Re: XXXXXXXX XXXXXXXX

Date: [REDACTED]

Page 4

The height is [REDACTED]. The weight is [REDACTED] pounds. The claimant is under the care of Dr. XXXXX (primary), cardiologist XXXXX, and neurologist XXXXXXX (it was XXXXXXX).

The family history is positive for heart disease and hypertension. The claimant is allergic to penicillin and Bactroban. He smokes an occasional cigar. He has an occasional drink. He denies drug misuse. He is a lifelong Californian - is married and has college and advanced studies. He is skilled in [REDACTED]. He feels he could do telephonic reports, and he believes he could do full duty as well.

He does not employ crutches, a cane, or a brace. He has a driver's license. He is right-handed. He can walk one to four blocks but gets tired, and can climb a flight of steps but gets tired. He can lift 40 pounds.

In summary, this claimant, who had what sounds like one or two stroke or stroke-like episodes in [REDACTED] [REDACTED], has not fully clarified cardiovascular difficulties, has sleep apnea, whose treatment improves PVC's and has a history of fundoplication, at this time, feels he could return to full duties as a [REDACTED] (?). He adds that the [REDACTED] - [REDACTED] stroke - stroke-like episode occurred when he was on duty. A full box of medical records is reviewed.

RECORDS REVIEW

It is my understanding that the musculoskeletal - orthopaedic - chiropractic challenges are challenges for other doctors. Chiropractic efforts of Dr. XXXXXXXX in [REDACTED] are noted. Stomach difficulties are commented upon. The September [REDACTED] MRI showed the temporal - parietal right-sided lesions. I noted the potential need for a lumbar puncture. Left arm and leg numbness were described in [REDACTED] - (not [REDACTED] BIBA - I guess that means brought in by ambulance). With the [REDACTED] event, right-sided head pain was noted. The [REDACTED] depo of the claimant is noted. The recorded statement is noted. The [REDACTED] esophageal studies are noted. Minimal sliding hiatal hernia was mentioned. Moderate intolerance of air distention of the stomach and duodenum was noted. Gastritis was noted, but Helicobacter was not demonstrated. Hemorrhoid surgery is noted - in [REDACTED]. Efforts of Drs. XXXXXXX and XXXXX in [REDACTED] are noted. It was noted that the pH study showed only minimal degree of gastroesophageal reflux and was poor correlation between symptoms of heartburn and the reflux events. Attorney Lusk took note of the input of Drs. XXXXXXX, XXXXXXX, and XXXXXXXX. Dr. [REDACTED] (American Board of Neurology) had noted that the claimant had a history of a stroke, and some back problems. Hypercoagulable state was mentioned, and the claimant was described to have MTH - FR- gene mutation and hyper - homocystenimea. I reviewed the efforts of Dr. XXXXXXXX and it appears that the exam was normal, but Dr.

Re: XXXXXXXX XXXXXXXX

Date: [REDACTED]

Page 5

XXXXXXXXXX did not provide a conclusionary sentence or paragraph. The [REDACTED] pneumonia hospitalization is noted. The skin efforts of Dr. XXXXXXX are note. Actually, medicine - these symptoms mention that the claimant was evaluated on [REDACTED] for symptoms that had begun with a right-sided headache one and a half weeks prior. The notes describe right MCA lesion (middle cerebral artery).

(Doctor's Comment - the problems are in the distribution of the right middle cerebral artery, but could represent embolus from a more proximal source such as the heart.)

Palpitations and dizziness were noted in [REDACTED]. Holter monitoring study was advised in [REDACTED]. Further data of Drs. XXXXX and XXXXXXX ([REDACTED] is noted. Abdominal ultrasound in [REDACTED] was unremarkable. Treadmill test in [REDACTED] was noted to be negative. Further [REDACTED] and [REDACTED] data are noted. The [REDACTED] surgical procedure takes note of severe refractory gastroesophageal reflux disease and hiatal hernia, and laparoscopic Nissen fundoplication and laparoscopic hiatal hernia repair. The [REDACTED] data describe the arrhythmias at the time of hospitalization for the stroke symptoms. The bubble echo of [REDACTED] took note of a family history for coronary artery disease. Neurological deficits had remitted. The rhythm strips demonstrate rare PVC's. Gout was mentioned. The claimant had difficulties with Plavix. The MR A angiogram demonstrated right middle cerebral disease. Left-sided foot drop was mentioned. Mild left atrial enlargement was mentioned. It was felt that the claimant had normal factor to prothrombin genetics. A C6-7 7-T polymorphism at the MTHFR general as felt not to be pertinent. The need for transesophageal echocardiogram was mentioned. The PEE was ultimately done on the [REDACTED] - normal.

In summary, these records document actual or potential irregular heartbeat dating back perhaps [REDACTED] years. His gastroesophageal studies and treatments are noted. Apparently, ultimately, the endoscopic data were minimally abnormal at worst and did not correlate well with his symptoms. Cardiac workup including loop studies has been noted. The genetic evaluation apparently demonstrated only rather minimal abnormalities. The most pertinent problem relevant to the claimant's brain was a somewhat unusual finding, namely isolated middle cerebral artery arteriosclerosis or similar derangement.

As noted - see research below - this is somewhat unusual, but does happen.

PHYSICAL EXAMINATION

At this point, I turn my attention to the physical examination.

Re: XXXXXXXX XXXXXXXX

Date: [REDACTED]

Page 6

My physical examination demonstrates a blood pressure of 151/99 (slightly elevated) with a pulse of 65 (relatively normal) - no arrhythmia palpated. No cognitive memory or language deficits are noted at this time. The claimant did not demonstrate overt psychological - psychiatric difficulties. Vision and hearing are grossly normal. Eyes, funduscopic exam, and cranial nerves are normal. ENT exam is normal. Neck shows no abnormality of trachea, veins, or thyroid. Lungs, heart, and pulses are normal. Abdominal and skin examinations are normal.

The musculoskeletal examination does not demonstrate any derangements or rheumatoid findings. The neurological examination - currently - demonstrates no gross or overt abnormal or lateralized findings. Tone, stance, and speech are normal, and the tendon reflexes are 1+. I did not document any overt neurocognitive deficits.

I now do an EEG with the help of technologist XXXXXXXX.

The basic waking rhythm is a combination of 9 Hz. alpha and low voltage fast activity. This is a normal basic-background rhythm. Drowsiness and sleep are not obtained. No abnormal waves, asymmetries or paroxysmal changes are seen.

This is a normal EEG.

DIAGNOSTIC IMPRESSION

1. Episode, [REDACTED] of right-sided brain lesions (two separate lesions) - with occlusive disease of right middle cerebral artery.

(Although everybody talks about middle cerebral artery disease, usually this middle cerebral artery problem is usually instead caused by either a carotid occlusion or an embolus from the heart. However, this claimant is the exception that proves the rule.)

2. Sleep apnea symptoms - CPAP treatment.
3. Irregularity of heartbeat - not fully defined.
4. Gastroesophageal disorder - status post fundus plication - most recent endoscopic findings apparently relatively normal.

INITIAL DISCUSSION

Re: XXXXXXXX XXXXXXXX

Date: [REDACTED]

Page 7

This claimant has occlusive disease of the right middle cerebral artery. His somewhat stuttering course over a week - two weeks in [REDACTED] - [REDACTED] matches up with that somewhat unusual anatomic - pathologic finding.

To what extent this correlates with irregular heartbeat is a puzzle. There are some articles (see below) of arrhythmia caused by temporal lobe lesions. His EEG was normal today.

TEMPORARY TOTAL DISABILITY

This claimant had the onset of stroke in [REDACTED] - [REDACTED], worked on at [REDACTED] for four months, but not since. The claimant wants to go back to work. At this point, he remains TTD.

PERMANENT DISABILITY

The claimant is probably MMI relevant to the two strokes on the right side of the brain. However, it is not entirely clear to what extent further treatment is required relevant to his persisting partial occlusion of the right middle cerebral artery - see discussion below.

SUBJECTIVE COMPLAINTS

Gastroesophageal symptoms - see discussion above.

No current stroke-like or seizure-like symptoms. No overt neurological deficits or neurocognitive deficits. The claimant specifically denied neuropsychological - neuropsychiatric issues. He did complain of pain in neck, shoulders, back, and knees.

OBJECTIVE FACTORS

Borderline high blood pressure. The pulse was normal today. Neurological examination was normal today.

AMA IMPAIRMENT RATING

Neurologically speaking, this claimant does not currently have a neurologically proven hemiparetic deficit that is ratable. The issue of his partial vascular occlusive disease of the right middle cerebral artery is not fully clarified - yet.

CAUSATION

Re: XXXXXXXX XXXXXXXX

Date: [REDACTED]

Page 8

Relevant to this claimant's occlusive right middle cerebral artery disease, the claimant describes a stressful environment. I did not do a psychiatric examination of the claimant. I think it would be essentially impossible to prove that occupational causation was not present (presumption). Causation is occupational.

APPORTIONMENT

At the present time, I identify no basis for apportionment.

FUTURE MEDICAL CARE

I have no specific recommendations relevant to medications. It is not clear to me whether some sort of an endoscopic approach to the middle cerebral artery or - alternately - external carotid - internal carotid bypass is a reasonable thought in this young man.

RETURN TO WORK

This claimant feels he can return to work. He has no fixed neurological deficits. It is not - yet - clear to me to what extent aggressive efforts on his part would trigger recurrent and worsened cerebral ischemia (that is why I am suggesting a tilt table EEG study).

STUDIES RECEIVED

Big stack of medical records - four hours.

STUDIES PERFORMED

EEG.

STUDIES REQUESTED

I need an up-to-date cardiological evaluation of this claimant with the latest loop data. It is possible that this claimant's right middle cerebral artery disease is position-dependent and I hope that a copy of this report is provided to Dr. XXXXXX. It is my thinking that a tilt table - EEG study might provide useful information relevant to cerebral ischemia and also relevant to arrhythmia (see discussion below). His basic EEG today was WNL.

On written approval from the carrier, we will schedule these diagnostic tests as possible.

Re: XXXXXXXX XXXXXXXX

Date: [REDACTED]

Page 9

RESEARCH PERFORMED

Please refer to refereed - open source articles I have selected relevant to isolated middle cerebral artery disease, and position dependent cerebral ischemia, and internal carotid - external carotid bypass therapy - therapeutic.

FURTHER COMMENT

The most pertinent abnormality is narrowing of the right middle cerebral artery. To what extent this can be approached endoscopically or by bypass (and whether this should be done) is a pertinent question. The claimant's week and a half of symptoms in [REDACTED] - [REDACTED] suggest a waxing and waning course with an area of brain experiencing variable ischemia.

If questions remain or arise that I can answer at this time, kindly write me back and I will respond immediately. Please note that the recent literature on syncope emphasizes tilt table testing.

If questions remain or arise that I can answer at this time - kindly write me back and I will respond immediately. Please note that a crucial issue is whether this claimant can or cannot return to work. I request the privilege of seeing the claimant back again in two - four months, at which time I will provide standard ratable language relevant to this issue, which is going to be about two years old when I see the claimant back again.

I certify that I took the complete history from the claimant, conducted the examination, reviewed all available medical records, and composed and drafted the conclusions of this report. The conclusions and opinions within this report are solely mine. I declare under penalty of perjury that the information contained in this report and its attachments, if any, is true and correct to the best of my knowledge and belief, except as to information that I have indicated I received from others. As to that information, I declare under penalty of perjury that the information accurately describes the information provided to me and, except as noted herein, that I believe it to be true. In accordance with Labor Code Section 5703(a) (2), there has not been a violation of Labor Code Section 139.3, and the contents of the report are true and correct to the best of my knowledge. This statement is made under penalty of perjury.

Pursuant to 8 Cal. Code Regs. Section 49.2-49.9, I have complied with the requirement for face-to-face time with the client in this evaluation. If necessary, I have discussed apportionment in the body of this report. If I have assigned disability caused by factors other than the industrial injury, that level of disability constitutes the apportionment.

Re: XXXXXXXX XXXXXXXX

Date: [REDACTED]

Page 10

The ratio of nonindustrial disability, if any, to all described disability represents my best medical judgment of the percentage of disability caused by the industrial injury and the percentage of disability caused by other factors, as defined in Labor Code Sections 4663 and 4664.

Respectfully,

Michael M. Bronshvag, M.D.
Diplomate in Neurology, ABP&N
Diplomate in Internal Medicine, ABIM

Date of Report: [REDACTED]
Signed this [REDACTED] day of [REDACTED], [REDACTED]

P.S. Copy to treating neurologist XXXXXXX - XXXXXXX, XX.

September 23, 2016

TO: Each Member
Board of Retirement

FROM: Ricki Contreras, Division Manager
Disability Retirement Services



FOR: October 5, 2016 Board of Retirement Meeting

SUBJECT: Application Processing Time Snapshot Reports

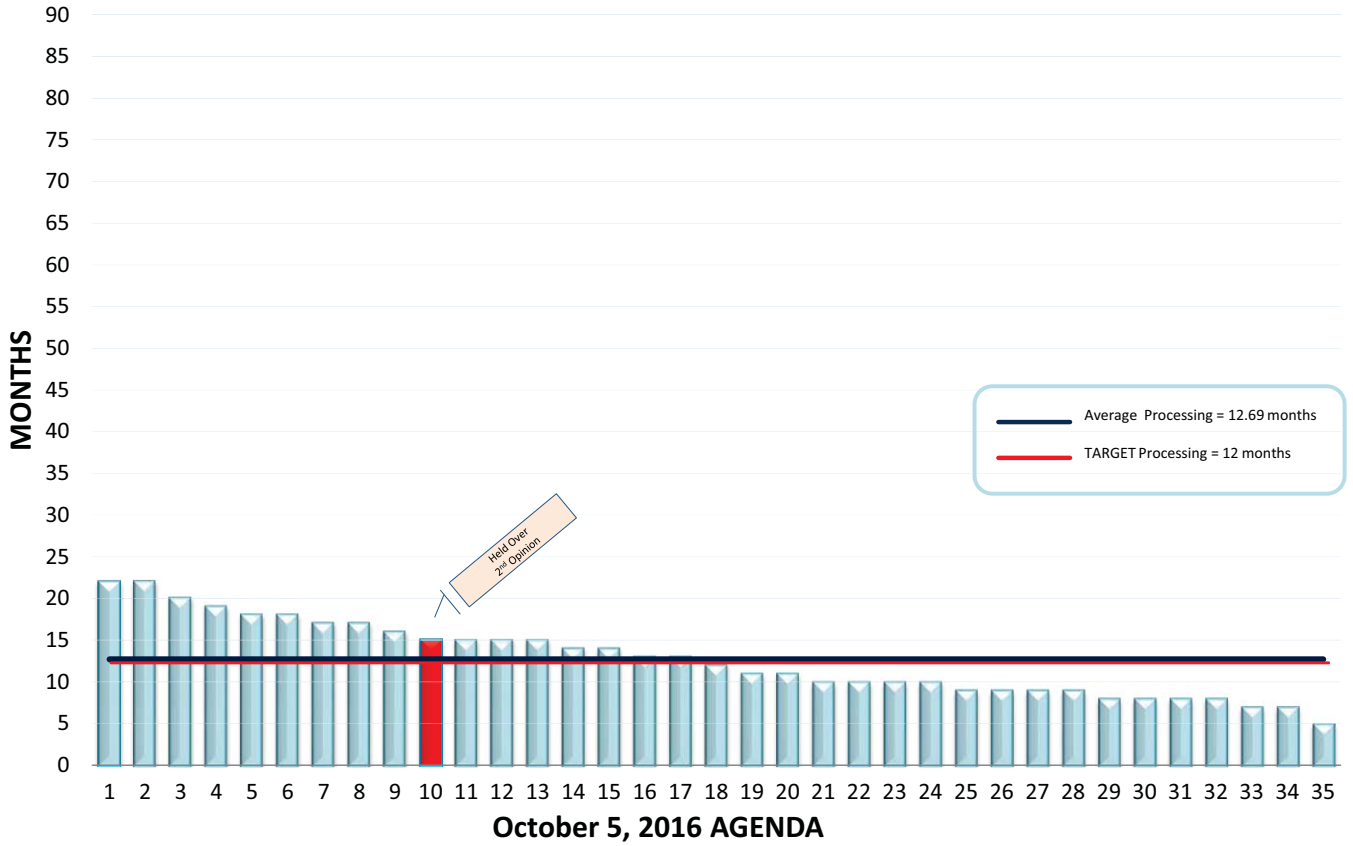
At the February 4, 2015 meeting, the Disability Procedures & Services Committee voted to add two additional snapshot reports addressing application processing times and pending applications by elapsed time since application date. These reports will now be provided on a monthly basis along with the current snapshot that provides a look at application processing time before and after procedural changes were made to the disability application process. The Board adopted proposed changes on July 12, 2012.

Note: All applications submitted prior to July 12, 2012 have been processed.

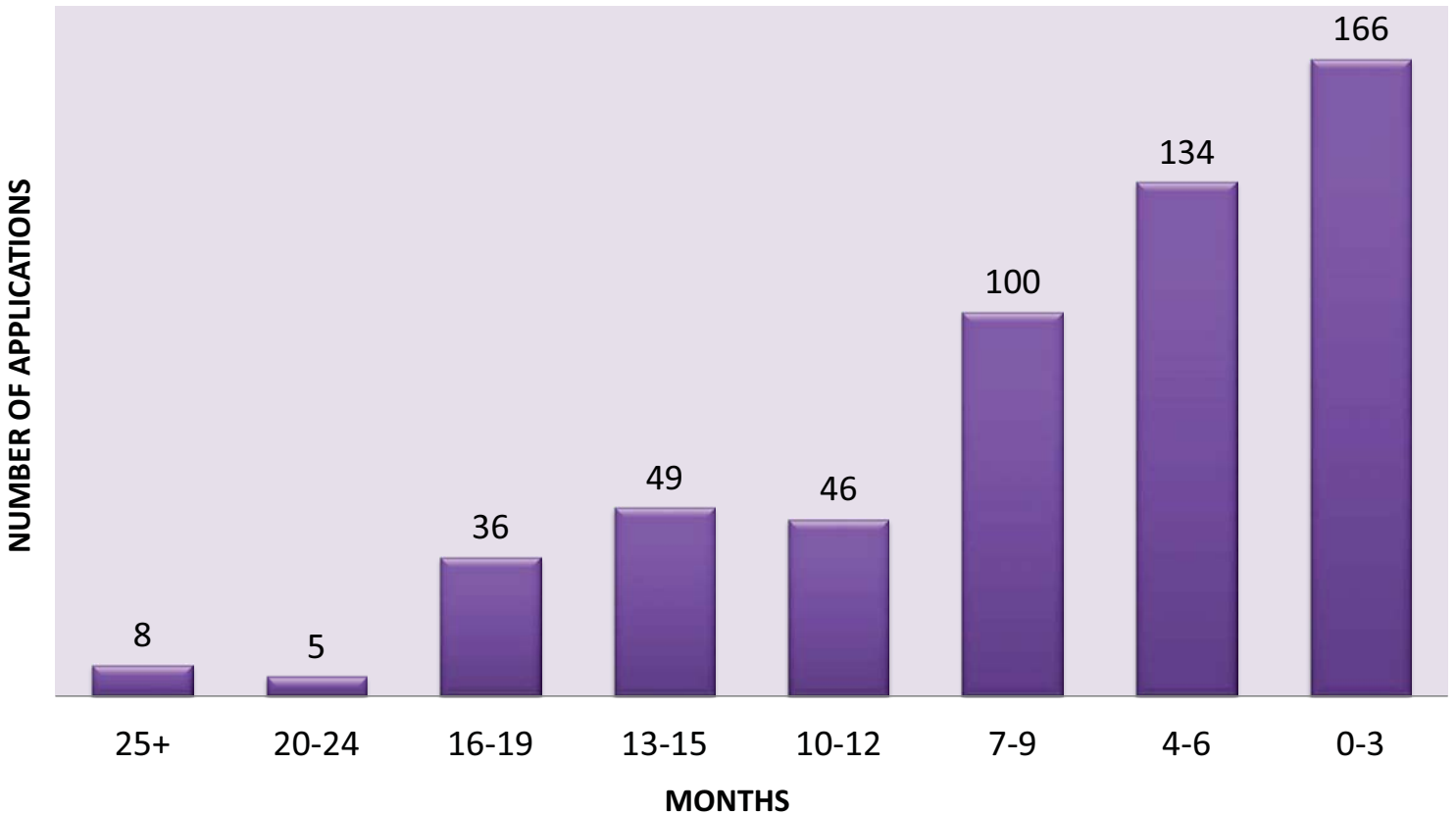
The following chart shows the total processing time from receipt of the application to the first Board action for all cases on the October 5, 2016 Disability Retirement Applications Agenda.

Consent & Non-Consent Calendar	
Number of Applications	34
Average Processing Time (in Months)	12.85
Revised/Held Over Calendar	
Number of Applications	1
Average Processing Time (in Months)	Case 1 15
Total Average Processing Time for Revised/Held Over Calendar	15.00

ACTUAL vs. AVERAGE PROCESSING TIME



TIME ELAPSED FOR PENDING APPLICATIONS





Documents not attached are exempt from disclosure under the California Public Records Act and other legal authority.

**For further information, contact:
LACERA
Attention: Public Records Act Requests
300 N. Lake Ave., Suite 620
Pasadena, CA 91101**



Documents not attached are exempt from disclosure under the California Public Records Act and other legal authority.

**For further information, contact:
LACERA
Attention: Public Records Act Requests
300 N. Lake Ave., Suite 620
Pasadena, CA 91101**



Documents not attached are exempt from disclosure under the California Public Records Act and other legal authority.

**For further information, contact:
LACERA
Attention: Public Records Act Requests
300 N. Lake Ave., Suite 620
Pasadena, CA 91101**



Documents not attached are exempt from disclosure under the California Public Records Act and other legal authority.

**For further information, contact:
LACERA
Attention: Public Records Act Requests
300 N. Lake Ave., Suite 620
Pasadena, CA 91101**



Documents not attached are exempt from disclosure under the California Public Records Act and other legal authority.

**For further information, contact:
LACERA
Attention: Public Records Act Requests
300 N. Lake Ave., Suite 620
Pasadena, CA 91101**