

# LIVE VIRTUAL BOARD MEETING



TO VIEW VIA WEB



TO PROVIDE PUBLIC COMMENT

You may submit a request to speak during Public Comment or provide a written comment by emailing [PublicComment@lacera.com](mailto:PublicComment@lacera.com). If you are requesting to speak, please include your contact information, agenda item, and meeting date in your request.

**Attention:** Public comment requests must be submitted via email to [PublicComment@lacera.com](mailto:PublicComment@lacera.com) no later than 5:00 p.m. the day before the scheduled meeting.

LOS ANGELES COUNTY EMPLOYEES RETIREMENT ASSOCIATION  
300 N. LAKE AVENUE, SUITE 650, PASADENA, CA

# AGENDA

## A REGULAR MEETING OF THE BOARD OF RETIREMENT

### LOS ANGELES COUNTY EMPLOYEES RETIREMENT ASSOCIATION

300 N. LAKE AVENUE, SUITE 810, PASADENA, CA

9:00 A.M., THURSDAY, OCTOBER 15, 2020

This meeting will be conducted by the Board of Retirement by teleconference under the Governor's Executive Order No. N-29-20.

Any person may view the meeting online at  
[https://members.lacera.com/lmpublic/live\\_stream.xhtml](https://members.lacera.com/lmpublic/live_stream.xhtml)

*The Board may take action on any item on the agenda,  
and agenda items may be taken out of order.*

- I. CALL TO ORDER
- II. APPROVAL OF MINUTES
  - A. Approval of the Minutes of the Regular Meeting of September 10, 2020
- III. PUBLIC COMMENT

(\*You may submit written public comments by email to [PublicComment@lacera.com](mailto:PublicComment@lacera.com). Please include the agenda number and meeting date in your correspondence. Correspondence will be made part of the official record of the meeting. Please submit your written public comments or documentation as soon as possible and up to the close of the meeting.

You may also request to address the Boards. A request to speak must be submitted via email to [PublicComment@lacera.com](mailto:PublicComment@lacera.com) no later than 5:00 p.m. the day before the scheduled meeting. Please include your contact information, agenda item, and meeting date so that we may contact you with information and instructions as to how to access the Board meeting as a speaker.)
- IV. CHIEF EXECUTIVE OFFICER UPDATE  
(For Information Purposes Only)
- V. DISABILITY RETIREMENT APPLICATIONS ON CONSENT CALENDAR

VI. CONSENT ITEMS

- A. Recommendation as submitted by Ricki Contreras, Division Manager, Disability Retirement Services: That the Board grant the appeal and request for an administrative hearing for applicant Zaheer A. Uraizee.  
(Memo dated October 1, 2020)

VII. NON-CONSENT ITEMS

- A. Recommendation as submitted by J.P. Harris, Chair, Disability Procedures and Services Committee: That the Committee approve Martin Schlusberg, M.D., Esq. – Board Certified Pulmonologist to the LACERA Panel of Physicians for the purpose of examining disability retirement applicants.  
(Memo dated October 5, 2020)

VIII. REPORTS

- A. For Information Only as submitted by Ricki Contreras, Division Manager, Disability Retirement Services, regarding the Application Processing Time Snapshot Reports. (Memo dated October 5, 2020)

IX. ITEMS FOR STAFF REVIEW

- X. GOOD OF THE ORDER  
(For information purposes only)

XI. DISABILITY RETIREMENT CASES TO BE HELD IN CLOSED SESSION

- A. Applications for Disability
- B. Disability Retirement Appeals

XII. ADJOURNMENT

*Documents subject to public disclosure that relate to an agenda item for an open session of the Board of Retirement that are distributed to members of the Board of Retirement less than 72 hours prior to the meeting will be available for public inspection at the time they are distributed to a majority of the Board of Retirement Members at LACERA's offices at 300 N. Lake Avenue, Suite 820, Pasadena, CA 91101, during normal business hours of 9:00 a.m. to 5:00 p.m. Monday through Friday.*

*\*Requests for reasonable modification or accommodation of the telephone public access and Public Comments procedures stated in this agenda from individuals with disabilities, consistent with the Americans with Disabilities Act of 1990, may call the Board Offices at (626) 564-6000, Ext. 4401/4402 from 8:30 a.m. to 5:00 p.m. Monday through Friday or email [PublicComment@lacera.com](mailto:PublicComment@lacera.com), but no later than 48 hours prior to the time the meeting is to commence.*

MINUTES OF THE REGULAR MEETING OF THE BOARD OF RETIREMENT  
LOS ANGELES COUNTY EMPLOYEES RETIREMENT ASSOCIATION

300 N. LAKE AVENUE, SUITE 810, PASADENA, CA

9:00 A.M., THURSDAY, SEPTEMBER 10, 2020

This meeting was conducted by the Board of Retirement by teleconference under the Governor's Executive Order No. N-29-20.

PRESENT: Herman Santos, Chair

Vivian H. Gray, Vice Chair

Gina Zapanta, Secretary (Joined the meeting at 9:04 a.m.)

JP Harris (Alternate Retired)

Shawn R. Kehoe

Keith Knox

Wayne Moore

Ronald Okum

William Pryor (Alternate Safety) (Joined the meeting at 9:04 a.m.)

Thomas Walsh

ABSENT: Les Robbins

STAFF ADVISORS AND PARTICIPANTS

Santos H. Kreimann, Chief Executive Officer

John Popowich, Assistant Executive Officer

Dr. Vito Campese, Medical Advisor

Steven P. Rice, Chief Counsel

STAFF ADVISORS AND PARTICIPANTS (Continued)

Francis J. Boyd, Senior Staff Counsel

Vincent Lim, Disability Litigation Manager

Tamara Caldwell, Disability Retirement Specialist Supervisor

Hernan Barrientos, Disability Retirement Specialist Supervisor

Kerri Wilson, Disability Retirement Specialist Supervisor

Ricardo Salinas, Disability Retirement Specialist Supervisor

Amabelle Delin, Disability Retirement Specialist

I. CALL TO ORDER

The meeting was called to order by Mr. Santos at 9:00 a.m. in the Board Room of Gateway Plaza.

II. APPROVAL OF MINUTES

A. Approval of the Minutes of the Regular Meeting of August 13, 2020

Ms. Gray made a motion, Mr. Kehoe seconded, to approve the meeting minutes of August 13, 2020. The motion passed (roll call) with Messrs. Knox, Okum, Harris, Walsh, Moore, Kehoe, Santos, and Ms. Gray voting yes

III. PUBLIC COMMENT (Mr. Pryor and Ms. Zapanta joined the meeting at 9:04 a.m.)

There were no requests from the public to speak.

IV. CHIEF EXECUTIVE OFFICER UPDATE

(For Information Purposes Only)

Mr. Kreimann shared that the election has been concluded and congratulated Messrs.

IV. CHIEF EXECUTIVE OFFICER UPDATE (Continued)

Robbins, Santos, Harris, Kelly, and Green. In addition, he shared an update to the Disaster Recovery efforts and Business Continuity Plan. Lastly, he provided an update to the Member Service Center.

V. DISABILITY RETIREMENT APPLICATIONS ON CONSENT CALENDAR

Safety Law Enforcement  
Service-Connected Disability Applications

On a motion by Mr. Kehoe, seconded by Mr. Okum, the Board of Retirement approved a service-connected disability retirement for the following named employees who were found to be disabled for the performance of their duties and have met the burden of proof. The motion passed (roll call) with Messrs. Knox, Walsh, Okum, Moore, Harris, Kehoe, Santos, Ms. Gray and Ms. Zapanta voting yes.

technical difficulties.

<u>APPLICATION NO.</u>	<u>NAME</u>
303D	FRANKIE J. LOBATO
304D	JOHN J. SANCHEZ
305D*	ROBERT M. FARKAS, JR.
306D	MICHAEL S. THOMPSON
307D	IAN M. STADE
308D	STEVEN R. PULLEY
309D	ENRICO L. DINAPOLI, JR.

\*Granted SCD – Employer Cannot Accommodate

V. DISABILITY RETIREMENT APPLICATIONS ON CONSENT CALENDAR

Safety Law Enforcement (Continued)  
Service-Connected Disability Applications

310D*	ANTHONY M. HAYNES
311D	WILLIAM E. COTTER
312D	PEDRO M. CACHEIRO
313D	MALIA A. ZENOR
314D**	SCOTT R. GIBSON
315D	KAREN L. WONG
316D*	MICHAEL E. THATCHER

Safety Fire, Lifeguards  
Service-Connected Disability Applications

On a motion by Mr. Pryor, seconded by Mr. Okum, the Board of Retirement made a motion to approve a service-connected disability retirement for the following named employees who were found to be disabled for the performance of their duties and have met the burden of proof. The motion passed (roll call) with Messrs. Knox, Okum, Walsh, Moore, Harris, Pryor, Santos, Ms. Gray and Ms. Zapanta voting yes.

<u>APPLICATION NO.</u>	<u>NAME</u>
1270B	STEVEN T. EGGER
1271B	ERIC C. REYNOLDS
1272B	EVA C. MAUCK

\*Granted SCD – Employer Cannot Accommodate

\*\*Granted SCD – Retroactive Since the Employer Cannot Accommodate



V. DISABILITY RETIREMENT APPLICATIONS ON CONSENT CALENDAR

Safety Fire, Lifeguards (Continued)  
Service-Connected Disability Applications

<u>APPLICATION NO.</u>	<u>NAME</u>
1273B	HENRY T. WALLER, III
1274B	JEFF G. HASKELL
1275B	GREGORY M. WATERS

General Members  
Service-Connected Disability Applications

On a motion by Ms. Gray, seconded by Mr. Okum, the Board of Retirement made a motion to approve a service-connected disability retirement for the following named employees who were found to be disabled for the performance of their duties and have met the burden of proof. The motion passed (roll call) with Messrs. Knox, Okum, Walsh, Moore, Harris, Kehoe, Santos, Ms. Gray and Ms. Zapanta voting yes.

<u>APPLICATION NO.</u>	<u>NAME</u>
2117C*	FRANKIE L. KNOX
2118C	RUTH FRAUSTO
2119C**	JOSEFA M. MENDOZA DE SANDOVAL
2120C	CYNTHIA R. GEMAEHLICH
2121C**	OUSAMA L. NIMRI
2122C*	VICTORIA D. MANGOLD

\*Granted SCD – Retroactive

\*\*Granted SCD – Employer Cannot Accommodate

V. DISABILITY RETIREMENT APPLICATIONS ON CONSENT CALENDAR

General Members (Continued)  
Service-Connected Disability Applications

<u>APPLICATION NO.</u>	<u>NAME</u>
2123C*	KATHLEEN HARSHAW
2124C*	JOAN S. LOCKWOOD
2125C**	MARIA L. RAMIREZ

VI. CONSENT ITEMS

Mr. Knox made a motion, Mr. Kehoe seconded, to approve the following Consent Items. The motion passed (roll call) with Messrs. Knox, Okum, Walsh, Moore, Harris, Kehoe, Santos, Ms. Gray and Ms. Zapanta voting yes.

- A. Recommendation as submitted by Ricki Contreras, Division Manager, Disability Retirement Services: That the Board grant the appeal and request for an administrative hearing for applicant Philip D. Solano. (Memo dated August 28, 2020)
- B. Recommendation as submitted by Ricki Contreras, Division Manager, Disability Retirement Services: That the Board dismiss with prejudice David J. Borthwick's Application for Correction appeal for an earlier effective date. (Memo dated August 25, 2020)

VII. EXCLUDED CONSENT ITEMS

There were no items excluded.

\*Granted SCD Retroactive – Employer Cannot Accommodate  
\*\*Granted SCD - Employer Cannot Accommodate

VIII. REPORTS

- A. For Information Only as submitted by Ricki Contreras, Division Manager, Disability Retirement Services, regarding the Application Processing Time Snapshot Reports. (Memo dated August 28, 2020)

Ms. Caldwell was present to answer questions from the Board. This item was received and filed.

IX. ITEMS FOR STAFF REVIEW

There were no items to report.

- X. GOOD OF THE ORDER  
(For information purposes only)

There were no items during Good of the Order.

XI. DISABILITY RETIREMENT CASES TO BE HELD IN CLOSED SESSION

- A. Applications for Disability

APPLICATION NO. & NAME

BOARD ACTION

5148B – JAMES G. ROSS, JR.

Mr. Kehoe made a motion, Ms. Gray seconded, to grant a service-connected disability retirement pursuant to Government Code Section 31720. The makers of the motion, amended the motion to refer back to staff for additional information. The motion passed (roll call) with Messrs. Knox, Kehoe, Okum, Walsh, Moore, Harris, Santos, Ms. Gray and Ms. Zapanta voting yes.

5149B – TERESA R. GARRETT

Mr. Kehoe made a motion, Mr. Okum seconded, to grant a service-connected disability retirement retroactive based on the medical advisor's opinion. The motion passed (roll call) with Messrs. Knox, Kehoe, Okum, Walsh, Moore,

XI. DISABILITY RETIREMENT CASES TO BE HELD IN CLOSED SESSION

A. Applications for Disability (Continued)

APPLICATION NO. & NAME

BOARD ACTION

Harris, Santos, Ms. Gray and Ms. Zapanta voting yes.

5138B – PORTLAND B. HOLMES

Ms. Gray made a motion, Mr. Harris seconded, to grant a service-connected disability retirement retroactive pursuant to Government Code Sections 31720 and 31724. The motion passed (roll call) with Messrs. Knox, Kehoe, Okum, Walsh, Moore, Harris, Santos, Ms. Gray and Ms. Zapanta voting yes.

5139B – JOHN T. CAFFREY

Mr. Kehoe made a motion, Mr. Harris seconded, to grant a service-connected disability retirement pursuant to Government Code Sections 31720 since the employer cannot accommodate. The motion passed (roll call) with Messrs. Knox, Kehoe, Okum, Walsh, Moore, Harris, Santos, Ms. Gray and Ms. Zapanta voting yes.

B. Disability Retirement Appeals

PHYLLIS K. HOLLOWAY (DEC'D) -

James M. Malkin for the Applicant  
Allison E. Barrett for the Respondent

Mr. Kehoe made a motion, Mr. Okum seconded, to deny a service connected disability retirement.

Mr. Moore made a substitute motion, Mr. Kehoe seconded, to grant a service connected disability. The motion failed (roll call) with Messrs. Knox, Okum, Harris, Santos, and Ms.

XI. DISABILITY RETIREMENT CASES TO BE HELD IN CLOSED SESSION

B. Disability Retirement Appeals (Continued)

Zapanta voting no; and Kehoe, Walsh, Moore and Ms. Gray voting yes.

The original motion to deny a service connected disability passed (roll call) with Messrs. Knox, Kehoe, Okum, Walsh, Harris, Santos, Ms. Zapanta voting yes; and Messrs. Kehoe, Moore, and Ms. Gray voting no.

JENNIFER T. WEBB - Thomas J. Wicke for the Applicant  
Jason E. Waller for the Respondent

Mr. Kehoe made a motion, Mr. Harris seconded, to grant a service connected disability retirement. The motion passed (roll call) with Messrs. Knox, Kehoe, Walsh, Moore, Harris, Santos, Ms. Gray and Ms. Zapanta voting yes.

ERIK DEGRATE – Steven M. Barry for the Applicant  
Eugenia W. Der for the Respondent

Ms. Gray made a motion, Mr. Knox seconded, to grant a service connected disability retirement. The motion passed (roll call) with Messrs. Knox, Kehoe, Walsh, Moore, Harris, Santos, Ms. Gray and Ms. Zapanta voting yes.

C. Staff Recommendations

1. Recommendation as submitted by Jason Waller, Senior Staff Counsel: That the Board (1) Find that James M. August is permanently incapacitated from the performance of duty as a Fire Fighter, 2) that his permanent incapacity is nonservice-connected, and 3) that the limitation set forth in Government Code section 31726.5(b)(2) for the intemperate use of alcohol is **NOT** applicable in this case.  
(Memo dated August 19, 2020)

XI. DISABILITY RETIREMENT CASES TO BE HELD IN CLOSED SESSION

C. Staff Recommendations (Continued)

Mr. Pryor made a motion Mr. Harris seconded, to approve staff's recommendation. The motion passed (roll call) with Messrs. Knox, Pryor, Walsh, Okum, Moore, Harris, Santos, Ms. Gray and Ms. Zapanta voting yes.

XII. ADJOURNMENT

There being no further business to come before the Board, the meeting was adjourned at 10:25 a.m.

---

GINA ZAPANTA, SECRETARY

---

HERMAN SANTOS, CHAIR



---

**Documents not attached are exempt from disclosure under the California Public Records Act and other legal authority.**

**For further information, contact:  
LACERA  
Attention: Public Records Act Requests  
300 N. Lake Ave., Suite 620  
Pasadena, CA 91101**



October 1, 2020

TO: Each Trustee  
Board of Retirement

FROM: Ricki Contreras, Division Manager  
Disability Retirement Services

SUBJECT: **APPEAL FOR THE BOARD OF RETIREMENT'S MEETING  
OF OCTBER 15, 2020**

**IT IS RECOMMENDED** that the Board of Retirement grant the appeal and request for administrative hearing received from the following applicant, and direct the Disability Retirement Services Manager to refer this case to a referee:

5144B    Zaheer A. Uraizee            In Pro Per                    Grant NSCD

RC:kw  
Memo.New  
Appeals.docx





October 5, 2020

TO: Each Trustee  
Board of Retirement

FROM: Disability Procedures & Services Committee  
JP Harris, Chair  
Herman B. Santos, Vice Chair  
Ronald A. Okum  
Gina Zapanta  
William Pryor, Alternate

FOR: October 15, 2020 Board of Retirement Meeting

SUBJECT: **CONSIDER APPLICATION FOR LACERA PANEL OF EXAMINING PHYSICIAN(S)**

On September 10, 2020, the Disability Procedures & Services Committee reviewed the attached application for the LACERA Panel of Examining Physicians.

The application package was provided to the Committee; however, due to a lack of a quorum, the Committee directed staff to submit to the Board of Retirement for approval to the LACERA panel.

**IT IS THEREFORE RECOMMENDED THAT** the Board approve the following physician to the LACERA Panel of Physicians for the purpose of examining disability retirement applicants.

**MARTIN SCHLUSSELBERG, M.D., ESQ. - Board Certified Pulmonologist**


Attachments

JPH:RC/mb



August 28, 2020

TO: Disability Procedures & Services Committee  
JP Harris, Chair  
Herman B. Santos, Vice Chair  
Ronald A. Okum  
Gina Zapanta  
William Pryor, Alternate

FROM: Ricki Contreras, Manager   
Disability Retirement Services

FOR: September 10, 2020, Disability Procedures and Services Committee Meeting

SUBJECT: **CONSIDER APPLICATION OF MARTIN SCHLUSSELBERG, M.D., ESQ., AS A LACERA PANEL PHYSICIAN**

On August 6, 2020, staff interviewed Dr. Martin Schlussselberg staff, a physician seeking appointment to the LACERA Panel of Examining Physicians.

Attached for your review and consideration are:

- Staff's Interview Summary and Recommendation
- Panel Physician Application
- Curriculum Vitae
- Sample Report(s)

**IT IS THEREFORE RECOMMENDED THAT THE COMMITTEE** accept the staff recommendation to submit the application of Martin Schlussselberg, M.D., Esq. to the Board of Retirement for approval to the LACERA Panel of Examining Physicians.

Attachments

JJ:RC:mb

NOTED AND REVIEWED:




JJ Popowich, Assistant Executive Officer



August 28, 2020

**TO:** Ricki Contreras, Manager  
Disability Retirement Services

**FROM:** Tamara L. Caldwell, DRS Supervisor   
Disability Retirement Services

**FOR:** September 10, 2020 Disability Procedures & Services Committee

**SUBJECT:** Recommendation for Pulmonologist Applying for LACERA's Panel of Examining Physicians

### **RECOMMENDATION**

Based on our efforts to provide a diverse panel of examining physicians in several geographic locations throughout Los Angeles and surrounding counties, staff recommends the Application of Martin Schlusberg M.D., Esq., be presented to the Board of Retirement for approval to the LACERA Panel of Examining Physicians.

### **BACKGROUND**

The Disability Retirement Services Division engaged National Disability Evaluations (NDE) to discuss potential candidates for the LACERA Panel of Examining Physicians. NDE provides timely high-quality disability evaluations and reports to government entities and private insurance carriers throughout the United States. Their network includes experienced local physicians/experts across a wide range of medical specialties. NDE's local professional presence enhances quality of service and improves workflow in the independent medical review process.

Dr. Martin Schlusberg holds American Board of Internal Medicine certification in internal medicine, pulmonary medicine, and critical care and received a Bachelor's Degree (B.A.) from Franklin & Marshall College and a second BA and medical degree from John Hopkins University in 1981. Dr. Schlusberg completed his internship at Parkland Memorial Hospital in 1982 and his residency at John Hopkins Bayview Medical Center in 1984. He been in private practice since 1997 to present and serves as Assistant Clinical Professor of Medicine at University of California, Riverside, since 2019.

Dr. Schlusberg has 5 years of experience performing medical legal evaluations and seven months conducting disability evaluations.

Staff reviewed the new LACERA Panel Physician Guidelines with the physician's management team, which included a lengthy discussion regarding the Rules in Evaluating Applicants, Disability Retirement Law Standards, and a thorough explanation of what is expected when preparing Panel Physician's written report for the Board of Retirement. Staff also discussed report submission timeframes, fee schedule and billing procedures, additional diagnostic testing request requirements, and advised of the requirement of maintaining a valid medical license, Board Certification, and insurance coverage. Staff also advised that all physicians must immediately report any lapses, suspensions or revocation of medical license, Board Certification, or insurance coverage, or be subject to immediate suspension or termination from LACERA Panel of Examining Physicians.

NDE will be responsible in making sure that Dr. Schlusberg adheres to the rules set forth in the Guidelines and all other requirements as discussed. NDE was informed that a Quality Control Questionnaire is sent to each applicant regarding their visit, which affords the applicant an opportunity to provide feedback concerning their experience during the medical appointment.

**IT IS THEREFORE RECOMMENDED THAT** the Application of Martin Schlusberg M.D., Esq., be presented to the Board of Retirement for approval to the LACERA Panel of Examining Physicians.

#### Attachments

RC:tlc

**Martin Schlusberg, M.D., Esq.**  
**Office Location Details**

Location	ADA Parking	ADA Restrooms	Lobby/Waiting Room Seating	Patients Per Day	Average Wait Time	Evaluation Time
6969 Indiana Avenue Riverside, CA 92506	Yes	Yes	1-4	5-10	5-15 Minutes	1 Hour

- 1. Rick Albert will be LACERA's point of contact for scheduling appointments and addressing issues and complaints.  
Contact: 310-392-0831 and ralbert@ndeval.com



<b>GENERAL INFORMATION</b>		Date
Please attach a list of any additional locations.		8/25/2020
Physician Name: <b>MARTIN SCHLUSSELBERG</b>	Group Name: <b>FIRST MEDICAL EXPERTS</b>	
Primary Address: <b>6869 INDIANA AVENUE, RIVERSIDE, CA 92506</b> APPOINTMENT ADDRESS		
Primary Contact: <b>RICK ALBERT</b>	Title: <b>PRESIDENT</b>	
Telephone: <b>(310) 593-4920 ext. 1</b>	Email: <b>rick@firstmedicalexperts.com</b>	
Fax: <b>(310) 392-0831</b>		
Secondary Address: <b>1516 S. BUNDY DRIVE, SUITE 307, LOS ANGELES, CA 90025</b> RECORDS/MAILING ADDRESS		
Telephone: Click or tap here to enter text.	Email: Click or tap here to enter text.	
Fax: Click or tap here to enter text.		

**PHYSICIAN BACKGROUND**


Field of Specialty: <b>PULMONARY MEDICINE</b>	Subspecialty: <b>INTERNAL MEDICINE</b>
Board Certification <input checked="" type="checkbox"/> Yes <input type="checkbox"/> No	Board Certification <input checked="" type="checkbox"/> Yes <input type="checkbox"/> No
License # <b>C 41554</b>	
Expiration Date: <b>4/30/2022</b>	
Has your license been suspended in the last 3 years? <input type="checkbox"/> Yes <input checked="" type="checkbox"/> No	
Has there been any disciplinary actions filed against you in the last 3 year? <input type="checkbox"/> Yes <input checked="" type="checkbox"/> No	

**EXPERIENCE AND CURRENT PRACTICE**  
Indicate the number of years of experience that you have in each category and the time spent performing each activity.

Type	Number of Years	Current Practice	Time Spent (%)
AME	0	Treatment	92
IME	0	Evaluations	8
QME	0	Research	0
Workers' Compensation Evaluations	0	Teaching	0
Disability Evaluations	7 mos		100 %
Med-Legal Reports	5 yrs		

Performing Medical Evaluations for Public Organizations	<input type="checkbox"/> Yes <input checked="" type="checkbox"/> No
Performing Medical Evaluations for Private Organizations	<input type="checkbox"/> Yes <input checked="" type="checkbox"/> No
Please Names of Organizations:	
Estimated Time from Appointment to Examination: <input type="checkbox"/> 2 weeks <input checked="" type="checkbox"/> 3-4 Weeks <input type="checkbox"/> Over a month	Able to Submit a Final Report and Invoice in 30 days: <input checked="" type="checkbox"/> Yes <input type="checkbox"/> No
<b>LACERA FEE SCHEDULE</b>	
Initial Examination/Report	\$ 1,500 – 1,800 flat rate (depending on specialty)
Review of Records	\$ 350.00 per inch
Supplemental Report	\$ 350.00 per hour
<b>Other Fees</b>	
Administrative Hearing Preparation	\$ 350.00 per hour
Depositions and Expert Testimony	\$ 350.00 per hour
<b>Cancellation Policy and Fees</b> Please indicate your cancellation policy and any applicable fees.	
What is you Cancellation Policy? (Attach policy, if applicable) <b>Cancellation must take place 6 business days prior to the appointment. \$500 no show fee.</b>	
Cancelled Exams:	Fee: \$ <b>500</b>
Cancelled Hearing:	Fee: \$ <b>500</b>

Name of person completing this form:

Print Name: MICHAEL ELIASON	Title: ASSISTANT
Physician Signature: 	Date: 8/25/2020

Please provide the following allow with the application:

- Curriculum Vitae
- Attach 2 Sample "Redacted" Medical Reports
- Copy of Medical License
- Copy of Board Certification(s)
- Certificate of Insurance

<b>FOR OFFICE USE ONLY</b> Physician Interview and Sight Inspection Schedule	
Interview Date: Interview Time:	Interviewer: All documents received: <input type="checkbox"/> Yes <input type="checkbox"/> No

Address: 6869 Indiana Avenue  
Riverside, CA 92506  
(951) 683-9999

## BOARD CERTIFICATION

American Board of Internal Medicine	Internal Medicine
American Board of Internal Medicine	Pulmonary Medicine
American Board of Internal Medicine	Critical Care

## EDUCATION

1974-1976	Franklin & Marshall College Chemistry, Mathematics	B.A.
1978	Johns Hopkins University 5 year M.D./B.A. program	B.A.
1977-1981	The Johns Hopkins University	M.D.

## POST-GRADUATE TRAINING &amp; PROFESSIONAL ACTIVITIES

1981-1982	Parkland Memorial Hospital	Internship
1982-1984	Johns Hopkins Bayview Medical Center	Residency
1982-1984	Johns Hopkins Hospital Internal Medicine	Postgraduate Fellowship
1984-1988	UCSD Medical Center Pulmonary	Postgraduate Fellowship
1988-1989	UCSD Medical Center Pulmonary Division	Instructor
1989-1991	Private Practice	Pulmonary Medicine
1991-1997	VA Outpatient Clinic, Los Angeles	Pulmonary Specialist
1997-	Private Practice	Pulmonary Medicine
2019-	Univ. Cal. Riverside	Asst Clin Prof of Medicine

## PROFESSIONAL ORGANIZATIONS

American Thoracic Society  
American College of Chest Physicians (Fellow)  
Past Member, Board of Directors, Make a Wish Foundation Orange County

## PUBLICATIONS

Chronic Thromboembolic Occlusion in the Adult Can Mimic Pulmonary Artery Agenesis. *Kenneth Moser, M.D., F.C.C.P; Linda Olson, M.D., F.C.C.P; Martin Schlusberg, M.D.; Pat Daily, M.D.; Walter Dembitsky, M.D., F.C.C.P. Chest 1989; 95; 503-508*



**Martin Schlusberg, MD**  
**6869 Indiana Ave**  
**Riverside, CA 92506**

Applicant Name           XXXXXX  
Soc Sec No.  
Employer                   County  
Occupation                ██████████

*County client*

**DISABILITY INDEPENDENT MEDICAL EVALUATION**

I have been asked to provide an independent medical evaluation on XXXXX and provide an opinion as to whether the applicant is permanently incapacitated, and if so, whether the applicant's employment substantially caused or aggravated his incapacity. I have reviewed the provided records, examined Mr. XXXXX for a telemedicine IME and have a written this report. Also note that under retirement law, incapacity means that this applicant is substantially unable to perform his usual duties and reasonable accommodations are not possible.

**IDENTIFICATION:**

Mr. XXXXX XXXXX began working in the YYYYYY County ██████████ Department in December 1987. He worked at the YYYYYY County jail until 1991. In 1991 he worked in the patrol division. and in 1999 he became a narcotics officer where he worked undercover. In 2001, he was promoted to sergeant. From 2002 to 2003, he worked at the courthouse. From 2003 to 2016, he worked in the security services division. On ██████████ he was demoted from ████████████████████. Mr. XXXXX has been off work since March 2016. His service-connected disability retirement application was filed on ██████████ listing severe air-flow obstruction, breathing problems with moderate exertion, frequent lung infections, pain in the lower left hip, headaches, fatigue, loss of concentration and high-frequency hearing loss. His application states he resigned on ██████████.

**ABSTRACT:**

1.     **Is the member currently incapacitated? Yes**
2.     **Is the member continuously incapacitated? Yes**
3.     **If so, date continuous incapacity commenced? ██████████**
4.     **Is the member permanently incapacitated? Yes**
5.     **If so, is the incapacity service connected? Yes**
6.     **Can the member return to his occupation with treatment? No**

**RECOMMENDATION:**

Based in my review the records/documents and my examination of Mr. XXXXX, I would recommend that a service-connected disability retirement be granted.

## **PRESENT ILLNESS:**

Mr. XXXXX joined the ██████████ in 1987. At that time, he was athletic and had mild, intermittent asthma. He was able to run 5 miles in less than 45 minutes.

In December 1987, he became a YYYYYY ██████████. At that time, he had no limitations on his activities. He played football and basketball. From January 1987 to March 1988, he worked in the YYYYYY County jail. He states this was a smoking facility where there was no ventilation system. There was also no air-conditioning. He states that he had to make ice runs to remain cool. During this time he describes a facility that was dusty, filled with smoke, and was exposed to many inmates with cough and sneeze. It was at this time that he started to develop his illness. He had a green discharge from his nose and greenish sputum. He had to use the inhaler more often and started to be placed on antibiotics nebulizer treatments by his physician.

In the spring of 1988, he worked at the ██████████. He was there for two months and again was in a facility that had no ventilation, was dusty, and congested. He had periods where he felt better but also had exacerbations of his illness during this two-month period.

From 1991 to 1997, he worked in the ██████████ division. He had calls for service. During this time and part of his work, he was under a great deal of stress. He states that he had to enter buildings where there was smoke from tobacco, marijuana, and fumes from methamphetamine production. He states that on several occasions, he was coughed on or spat on by arrested individuals. His illness progressed and he was sicker with difficulty breathing wheezing. He needed to use inhalers constantly and was also receiving antibiotic and prednisone treatments.

In 1999, he became a ██████████ where he worked undercover. He again had exposure to methamphetamine labs and chemical fumes. This was again a very stressful job which exacerbated his asthma. As part of his work, he would have to search homes and was exposed to toxic inhalation of substances. He had no protective gear but states that on many occasions he had to call in a HAZMAT team to handle the chemicals that he found.

From 2002 to 2003, he worked at the courthouse with 50-200 inmates. Again, there was no ventilation. His asthma grew much worse and he required IV antibiotics and prednisone on several occasions.

According to his medical records, in 2002, he became exposed to nuclear wastes at ██████████ without protective gear or warning.

He then came under the care of Dr. ██████████ regarding his asthmatic condition. At that time, he was diagnosed as having aspirin-exacerbated respiratory disease, formerly known as Samter's triad, which is a chronic condition defined by asthma, sinus inflammation and recurring nasal polyps.

Aspirin desensitization therapy was attempted without success.

From this point on, Mr. XXXXX was treated with numerous agents including inhaled steroids, antibiotics, and antifungal agents. Mr. XXXXX was seen concurrently by an ear, nose and throat specialist for the otolaryngology manifestations of his illness.

Mr. XXXXX has frequent exacerbations of his illness which have worsened in severity over time.

From 2003 to 2016, he worked in the security services division. He reports that the patrol car issued to him had mold. He states that he reported this to County maintenance. He was told the car has no cabin filter. No action was taken to repair the car or fix the problem. He stayed in the same vehicle for eight years and during that time his asthma worsened.

From 2006 to 2012, he worked at [REDACTED] in YYYYYY. According to Mr. XXXXX there was water dripping into the building and there was mold on the walls.

In 2013, pulmonary function studies at that time showed an FEV1 which was 43% of predicted with 30% improvement after bronchodilator therapy.

In 2014 he smoked one cigar every two months for that year. He has not smoked since that time.

In 2016, he worked in the jail and patrol divisions. At that time, his health was poor, and on [REDACTED], he took a leave of absence for one and a half years.

On [REDACTED], Mr. XXXXX was diagnosed with chronic sinusitis and steroid-dependent asthma.

On [REDACTED], he received his first Nucala injection. Nucala, or mepolizumab, is an interleukin-5 antagonist monoclonal antibody treatment for severe eosinophilic asthma. According to the records, Mr. XXXXX has had some success with this treatment and attributes this to the new medication as well as being away from his work environment.

His current medications included antibiotics, Nucala, Trilegy, Zileutin and Pro-air. With this regimen he has been able to decrease prednisone dose.

Mr. XXXXX continues to be symptomatic, and via telemedicine, I was able to observe and do a forced vital capacity maneuver where he had a prolonged expiratory phase with wheezing.

Due to Mr. XXXXX's current condition, he would also be at increased risk if exposed to coronavirus.

His medical records also discuss nasal polyps, chronic sinusitis, hearing loss, and otolaryngology surgeries.

### **WORK STATUS**

Currently, Mr. XXXXX is retired. He was employed as a [REDACTED] by the YYYYYY County [REDACTED] for 30+ years.

### **PAST SURGICAL HISTORY**

[REDACTED] – functional endoscopic sinus surgery and biopsy

### **PAST MEDICAL HISTORY**

h/o MVA

Multiple traumas in the course of his sheriff's work

### **HOME MEDICATIONS**

Nucala injections  
Trilegy  
Zileutin  
Pro-air  
Prednisone  
Antibiotics during acute exacerbations

### **ALLERGIES**

None noted

### **REVIEW OF SYSTEMS**

A 10-point review of systems for internal medicine was conducted. Relative positives and negatives are noted in the body of this report.

### **PHYSICAL EXAMINATION**

The evaluation was conducted via a telemedicine connection; therefore, physical examination findings are limited. I asked Mr. XXXXX to do a forced vital maneuver, and did note that he had a prolonged expiratory phase and audible wheezing.

The customary physical examination was not possible due to the fact that this is a telemedicine visit during a pandemic.

### **DIAGNOSTIC IMPRESSION:**

Severe persistent asthma, eosinophilic subtype  
Nasal Polyposis  
Hearing Loss

### **DISCUSSION:**

Mr. XXXXX had a diagnosis of mild intermittent asthma prior to becoming a YYYYYY [REDACTED]. Prior to his employment and early on in his employment, he had no limitations in his exercise tolerance. He was able to play football and basketball and was able to run 5 miles in less than 45 minutes.

His asthma worsened in 1987 when he worked in a facility that had no restrictions on smoking, no ventilation system and no air-conditioning. From 1991 to 1999, he worked as a [REDACTED] and had very high stress levels handling calls. On [REDACTED], he was exposed to smoke from a diesel tanker truck. From 1999 to 2001, he became a [REDACTED] and was exposed to chemicals and methamphetamine labs. During this time, he had four surgeries for nasal polyp removal. Bilateral myringotomy and tubes were also performed. In 2002, he became exposed to nuclear waste at the [REDACTED] without protective gear or warning.

In 2002, Mr. XXXXX was followed by an allergist, and an otolaryngologist and pulmonologist. He was treated with antibiotics and prednisone. Aspirin desensitization therapy was tried without success.

On [REDACTED], pulmonary function tests showed an FEV1 of 43%.

In 2016, Mr. XXXXX was treated for pneumonia. He had frequent exacerbations of his asthma. He failed to improve despite multiple medical regimens. According to the medical records, he was still wheezing and had tachycardia and hypertension.

Because of his failure to respond to conventional medications, he was started on Nucala. At this time he received anti-allergy therapy, inhalers, steroid irrigation, and monthly Nucala injections. He was also kept off work to his due to his ongoing respiratory problems. The applicant was reported to improve with these interventions and on [REDACTED] was reported as having a normal spirometry.

Based on his improvement away from work, it was recommended that he not return to work involving [REDACTED] duties including sustained physical confrontations with combative subjects, running with safety gear, ascending upwards quickly; pushing, pulling, lifting, carrying moderate to heavy objects for a sustained amount of time, and prolonged exposure to stress, anxiety, air pollutants, chemical irritants, fungi, bacteria, and viruses. On [REDACTED] his asthma symptoms were continuing to improve.

#### **SUMMARY OF MEDICAL RECORDS:**

Mr. XXXXX has a long history of asthma dating back to 1986, prior to his employment with YYYYYY [REDACTED]. He claimed to have sustained substantial inhalational aggravation due to being exposed to allergens, irritants, fumes and toxic respiratory substances while doing his job. From 1987 to 1991, he worked at a jail building and was exposed to secondhand smoke from inmates, bacteria, molds, dust, and viruses as well as patients with lung disease. From 1991 to 1999, he worked as a [REDACTED], [REDACTED], high impact team and problem-oriented [REDACTED].

On [REDACTED], he was exposed to smoke from diesel tanker truck fumes. Moreover, he had very high stress levels trying to handle calls. From 1999 to 2001, he became a [REDACTED] and was exposed to chemicals at methamphetamine labs. In this period of time, he had 4 surgeries for nasal polyp removal. Bilateral myringotomy and tubes were also performed. In 2002, he became exposed to nuclear waste at [REDACTED] without protective gear or warning.

On [REDACTED], Mr. XXXXX came under the care of Dr. [REDACTED] regarding his asthma and allergic rhinitis/chronic sinusitis, and nasal polyps. During this time, Mr. XXXXX also started seeing Dr. [REDACTED], primary, for his ear infections. He had chronic pansinusitis and otorrhea which were treated with IV antibiotic therapy, irrigations, and topical antibiotics.

On [REDACTED], Mr. XXXXX was found to have chronic bilateral mastoiditis primarily due to his severe chronic allergic disease by Dr. [REDACTED]. Dr. [REDACTED] was against a mastoid surgery at that time. Mr. XXXXX was also treated for his orthopedic injuries.

By [REDACTED], his sinusitis was under good control with allergy management. However, on [REDACTED], he experienced exacerbation of his asthma and was seen by Dr. [REDACTED]. Dr. [REDACTED] prescribed prednisone. Amoxicillin was also prescribed for the sinusitis. Zflo was later added since this was helpful in the past.

On [REDACTED], Mr. XXXXX returned to Dr. [REDACTED] with respect to his respiratory symptoms for which he was given antibiotics and prednisone. Aspirin desensitization was then tried without success in controlling his Samter's triad. On [REDACTED], he was diagnosed with asthma/chronic obstructive pulmonary disease (COPD).

On [REDACTED], Dr. [REDACTED] noted that Mr. XXXXX had recurrent nasal sinus polyp and gave him a referral to an ENT specialist. His lower airflow obstruction remained present on [REDACTED]. His spirometry also showed 43% FEV1 with 30% reversibility. On [REDACTED], he had a course of inhaled steroids, antibiotic, and antifungal which improved his anosmia. Dr. [REDACTED] thereafter recommended a second round of the combination nebulized treatment.

A CT scan of the facial sinuses were obtained on [REDACTED], showing moderate to severe residual pansinus disease with air-fluid levels in the left sphenoid sinus, moderate to severe mucosal thickening in the nasal cavity causing obstruction of the nasal passageways around the superior and residual middle turbinates, and evidence of old left posterior inferior cerebellar artery infarction. Because of this, he continued using all of his inhalers for his allergy and asthma. On [REDACTED], he was given a treatment of prednisone and Augmentin for his allergic rhinitis.

On [REDACTED], he was reevaluated regarding his uncontrolled asthma by Dr. [REDACTED], at which time a spirometry was done, revealing severe airway obstruction with low vital capacity. For this reason, he basically continued to require inhaled therapy for his asthma and also used a rescue inhaler when he had increased symptoms. In addition, he continued to be treated for his chronic ear infections. His asthma was doing a little better on [REDACTED], but he was still referred to see Dr. [REDACTED] for further evaluation and management of his condition.

Dr. [REDACTED] saw him on [REDACTED] for evaluation of his left ear pain. During this visit, he was diagnosed with serous otitis media, eustachian tube dysfunction, polyps of nasal cavity, chronic rhinitis, and asthma extrinsic. Dr. [REDACTED] put him on Ciprodex drops and oral prednisone. An updated CT scan of the sinus was performed on [REDACTED], demonstrating bilateral pansinus mucosal disease with recurrent sinusitis. Since he showed improvement with Ciprodex drops and oral prednisone, they were continued. For the recurrent polyposis, Mr. XXXXX began a clinical trial with Nasonex on [REDACTED] with no improvement. Chest x-rays were taken on [REDACTED] due to his complaint of difficulty breathing. This study showed mild peribronchial thickening which could be seen with reactive airway disease or other etiologies. He was therefore put on budesonide for his nasal congestion on [REDACTED]. An allergy testing was deferred on [REDACTED] due to having an asthma exacerbation. Because of his worsening condition, he was started on Spiriva Resimat in addition to Alvesco. Furthermore, he was treated with an antibiotic sulfamethoxazole for an ear infection. A repeat spirometry was done on [REDACTED], showing moderately severe obstruction with low vital capacity.

He remained symptomatic without much improvement despite using multiple medications. He had tried many inhaled therapy combinations without relief of his symptoms; thus, he was given a Kenalog shot and was taken off work on [REDACTED]. The injection had slightly improved his breathing; however,

he was still wheezing and had elevated heart rate and high blood pressure. Nucala injection was therefore suggested.

On [REDACTED], Dr. [REDACTED] also suggested a revision ethmoidectomy to remove the polyps. On [REDACTED], Mr. XXXXX indicated that he felt better in general and being out of the workplace had apparently helped. He believed the exposure to all of the bacteria and viruses at work with stress was a major factor in his illness. His pulmonary function test performed on [REDACTED] did show an obstructive process with bronchodilator reversibility.

On [REDACTED], he finally underwent a functional endoscopic sinus surgery and biopsy specimens were consistent with benign sinonasal tissue and bone with chronic inflammation. He had a satisfactory course following surgery. However, he was put on Bactrim for the *Achromobacter* and *S. aureus* found on the ear and sinus cultures. His sinuses and ears responded well to Bactrim. On [REDACTED], Dr. [REDACTED] indicated that Mr. XXXXX had sinusitis and steroid-dependent asthma. Dr. [REDACTED] believed that his frequent need for steroids and permanent lung scarring had been exacerbated by his frequent work exposure to the margins of society and stressful work.

On [REDACTED], he received his first Nucala injection for his persistent asthma. He was also ordered to stay off work until such time as his severe asthma was deemed controlled. He had a sputum culture which showed *H. influenzae* on [REDACTED], which was treated with antibiotics. On [REDACTED], he returned for his monthly Nucala injection. In addition, he restarted his aspirin desensitization on [REDACTED]. The next day, he was noted to have severe persistent asthma which was exacerbated by his pneumonia.

Mr. XXXXX was evaluated by Dr. [REDACTED] on [REDACTED], at which time he was not yet deemed P&S. Dr. [REDACTED] felt that Mr. XXXXX's asthma had likely been worsened by his employment, and while there would certainly be apportionment to nonindustrial causes because of his pre-existing condition as well as occasional sporadic smoking of cigars, there appeared to be a significant industrial component. In order to better assess impairment, a pulmonary function test was ordered. He continued to receive anti-allergy therapy, inhalers, steroid irrigation, and monthly Nucala injection. His repeat sputum culture on [REDACTED], still showed *H. influenzae*.

On [REDACTED], Dr. [REDACTED] placed Mr. XXXXX on a course of azithromycin due to his chronic bronchitis. Mr. XXXXX was kept off work due to his ongoing respiratory symptoms and improvement while on aggressive medical therapy and away from work environment. On [REDACTED], his spirometry only showed mild airway obstruction. The paranasal sinus polyposis was declared as under control on [REDACTED]. His Nucala injection was helpful, although it did cause headaches and fatigue. Overall, he had made significant progress, so Dr. [REDACTED] decided to continue his Nucala injection on [REDACTED].

Mr. XXXXX came back to Dr. [REDACTED] on [REDACTED] concerning his neurosensory hearing loss and serous otitis media. Dr. [REDACTED] encouraged Mr. XXXXX to continue seeing Dr. [REDACTED] to have his ears examined and cleaned. Mr. XXXXX was considered P&S from the standpoint of the neurosensory hearing loss.

For his ongoing respiratory symptoms, he remained on maximal therapy with combined multi-drug inhaled treatment. With his sputum production, a month-long course of azithromycin combined with samples of Daliresp was initiated on [REDACTED]. His acute bronchitic symptoms later resolved. While on Nucala, he noted an improvement in his asthma. He apparently had a normal spirometry on [REDACTED]. On [REDACTED], he reported that he felt better off work with less stress and environmental exposures.

When seen on [REDACTED], Dr. [REDACTED] noted Mr. XXXXX should be precluded from doing activities that exacerbated or triggered his asthma with regards to his law enforcement duties, including sustained physical confrontations with combative subjects, running with safety gear, ascending upwards quickly, pushing, pulling, lifting, carrying moderate to heavy objects for a sustained amount of time, and prolonged exposures to stress, anxiety, air pollutants, chemical irritants, fungi bacteria and viruses. Dr. [REDACTED] issued a report on [REDACTED], stating Mr. XXXXX could no longer continue to work in his current job based on his known inhalational/respiratory sensitivities and vulnerability. Dr. [REDACTED] also concluded that Mr. XXXXX's job aggravated his condition.

On [REDACTED], Mr. XXXXX had an audiometric evaluation in which Dr. [REDACTED] suggested that he be fitted with hearing aids. He continued to do well with respect to his respiratory symptoms.

On [REDACTED], Dr. [REDACTED] advised continuing nasal steroids to decrease recurrence of nasal polyps. Mr. XXXXX was also instructed to stay on prescribed inhalers and Nucala. Trelegy Ellipta was started as well and this significantly improved his asthma control.

On [REDACTED], he reported he was able to hear and understand conversation better with his hearing aids. On [REDACTED], his asthma symptoms continued to improve.

On [REDACTED], Dr. [REDACTED] advised against returning to work as this would cause progression of his hearing loss, and indicated that Mr. XXXXX must also wear his hearing aids.

On [REDACTED], Dr. [REDACTED] examined Mr. XXXXX for his annual audiologic evaluation, at which time he was counseled on wearing hearing aids full time and strategies for tinnitus management with hearing aids. Annual audiologic evaluation, hearing aid evaluation, and bi-annual hearing aid check/clean with electroacoustic analysis were recommended as well.

### **MMMMM REPORT QUESTIONS:**

1) *Is the member physically and/or mentally incapacitated from substantially performing the usual duties of his job, with or without accommodation, due to the claimed injury(ies) or disease(s)? Please consider the following: "Disability" has been defined as the "substantial inability of the member to perform his usual duties." Inability to perform some of the duties of a position does not render one disabled.*

Yes. I find within a reasonable medical probability that Mr. XXXXX is physically incapacitated from performing the usual duties of his job. He is unable to perform sustained physical confrontations with combative subjects, running with safety gear, ascending upwards quickly; pushing, pulling, lifting, or carrying moderate to heavy objects for a sustained amount of time.

The working conditions (which include exposure to smoke, fumes, mold, and secondhand smoke in buildings that are not ventilated and/or unsanitary) are responsible for converting his initial mild asthma and to severe asthma requiring specialized treatment. If he is to be further exposed, he runs the risk of further worsening his condition.

2) *Is the incapacity permanent? What is the expected duration of limitation described above with or without treatment?*



I find within a reasonable medical probability that the incapacity is permanent, as there can be no accommodations or treatment offered to which would reverse his underlying pulmonary condition, allowing him to resume the duties of his job as a [REDACTED].

3) *(If applicable) Is the incapacity service-connected? If so, please explain the mechanism of injury that is a link between the employment and the incapacity. Please consider the following: Members seeking service-connected disability retirement must produce a preponderance of substantial evidence of a real and measurable work contribution to the claimed injury(ies) or disease(s).*

I find within a reasonable medical probability that there is a real and measurable work contribution to Mr. XXXXX's incapacity. Mr. XXXXX was exposed to elements at his workplace which caused him to have severe asthma. He was put in an enclosed environment where there was secondhand smoke without any ventilation system. He was exposed to nuclear waste without protective gear. He was exposed to marijuana and fumes from methamphetamine labs. The stress involved in his patrol and [REDACTED] duties also contributed to his asthmatic illness. The working conditions of the job are responsible for converting his initial mild asthma and to severe asthma requiring specialized treatment.

4) *Is the member able to perform other job duties based on restrictions imposed by his claimed injury(ies) or disease(s)?*

No. The physical requirements of [REDACTED] as detailed in the job description state "Positions in this class require the incumbent to possess sufficient physical ability to perform the full scope and functions of the job, including the ability to climb barriers, jump obstacles, and perform strenuous physical activities and control resisting subjects with a minimum of force necessary to effect an arrest."

5) *Is the member able to perform other work in YYYYYY County Service?*

Mr. XXXXX would be able to perform clerical work in a sanitary environment.

6) *Is there any evidence that the member's claimed injury(ies) or disease(s) resulted from the member's intemperate use of alcohol or drugs or willful misconduct?*

No. I have not seen any evidence that the members disease resulted from intemperate use of alcohol or drugs or willful misconduct.

7) *(If applicable) If the application date is more than four (4) months after the discontinuation of service date, was the member continuously physically and/or mentally incapacitated for the performance of his usual job duties from the discontinuation of service date to the application date? If so, on what date would you consider him to be permanently incapacitated? Please consider the following: Timeliness of application rules require that when a member applies for disability retirement beyond four (4) months after leaving service, an additional burden of proof is placed on the member to prove through the medical evidence that he was continuously physically and/or mentally incapacitated to substantially perform his duties from the discontinuation of service to the application date.*

I find within a reasonable medical probability that the member was continuously physically incapacitated in the performance of his duties from the date of his discontinued service to the time of the application date.

8) *Has the member received appropriate treatment for the stated illness/injury? Staying within your specialty, is additional medical or other treatment needed?*

Yes, Mr. XXXXX has received appropriate evaluations and treatment, including evaluation for his allergic rhinitis, nasal polyps, and respiratory condition. It is my opinion that, at this time, no additional treatment is indicated apart from his current treatment regimen.

From a medical standpoint, Mr. XXXXX should receive annual examinations to ensure that he is receiving appropriate treatment and that there is no worsening of his condition.

### **MEDICAL RECORDS REVIEW**

Application for Disability Retirement - Mr. XXXXX XXXXX - [REDACTED].

Medical Report - [REDACTED], M.D. - [REDACTED] Page 1552. The patient was having some nasal bleeding. This had since stopped. He was not experiencing postnasal discharge at this time. His ears were blocked bilaterally quite severely. Assessment: No chronic Pseudomonas rhinosinusitis with otitis media. Glue ear and glue-like secretions of the sinuses remained. Dr. [REDACTED] was having trouble diagnosing it. On the topical tobramycin, the patient was actually keeping things under control from a rhinosinusitis point of view. He was recommended to continue with tobramycin topically, and Humibid would be added for secretion management of the middle ear.

Medical Report - [REDACTED], M.D. - [REDACTED] Page 1279. The patient was seen in follow-up of his chronic pansinusitis and otorrhea. He continued on tobramycin inhalation. He had not used topical drops for some time. Yesterday, his ear did start to open up a bit simultaneously. He has not had bilateral ventilation for about a year. He wanted a second opinion at this point, which Dr. [REDACTED] supported. The patient has had 6 weeks of IV antibiotic therapy, sinus surgery twice, and multiple sets of tympanostomy tubes. He was currently undergoing immunotherapy and had been compliant with irrigations and topical antibiotics.

Progress Note - [REDACTED], M.D. - [REDACTED] Pages 2203-2205. The patient complained of chronic ear infections. He was seen for evaluation of his otorrhea usually on the left and occasionally on the right. He had been experiencing this for the past 4 months and it was associated with full sensation in the ear, nasal congestion on both sides, and loss of smell. In the past, this was treated with prednisolone, tympanostomy, and sinus surgery to remove polyps. He had bilateral myringotomy and tubes (BMT) in 11/2001. His current medications were Flonase and prednisone. He had inhalant allergies. Allergy skin test was done in 10/2002. Allergy shots were still being taken. The shots were started in 01/2003. He has a history of sinus infections, asthma, and reflux. He had 4 surgeries for nasal polyps in 1999 and 2001. Assessment: Chronic bilateral mastoiditis, primarily due to severe chronic allergic disease. The patient's primary pathology was with severe allergic disease. Anything that Dr. [REDACTED] could do, including long-term prednisone, would be beneficial. Dr. [REDACTED] did not feel there was a role for mastoidectomy, at least at this point, because this would not improve the patient's eustachian tube function or allergy conditions, the 2 primary etiologies. Dr. [REDACTED] did explain to the patient that there were some patients who would have such intractable middle ear disease that they ultimately would end up having mastoid surgery after years and years of problems. At this point, it was a relative trade-off, whether he was better off with or without the tubes. With chronic mucoid otorrhea

his ear canal skin was becoming a little macerated and a case could be made for removing the tubes simply to let the canal skin rest. Dr. [REDACTED] told the patient that most of the time if the tubes were removed, the middle ear effusion would resume and his symptoms of otorrhea would be replaced by hearing loss and pressure. If this occurred and was problematic, then either a hearing aid or reinsertion of the tubes could be considered. Dr. [REDACTED] did not think there were any easy solutions for this difficult problem.

Medical Report - [REDACTED], M.D. - [REDACTED] Page 114. The patient required a medical leave of absence from [REDACTED] to [REDACTED] and then he could return to work.

Revised Job Description for a [REDACTED] - County of YYYYYYY - [REDACTED] Pages 66-69. The work of a [REDACTED] involved performing law enforcement duties to protect life and property and to preserve law and order. It also entailed working various shifts to provide 24-7 coverage; working in a detention facility and be in direct contact with inmates; be potentially exposed to hazardous materials including bodily fluids; working in hot or cold conditions for extended periods of time; and wearing and maintaining a designated [REDACTED] Department uniform; including department-issued safety equipment such as a duty/gun belt, ballistic vest, and respirator.

Progress Note - [REDACTED], M.D. - [REDACTED] Pages 536-537. The patient felt the tubes came out and it felt blocked. He also complained of mild cough, sore throat, and nasal congestion. Assessment: 1. Chronic serous otitis media. 2. Screening lipid disorders. The plan was to refer him to an ENT specialist and refill his prednisone. Laboratory studies were also ordered for screening for screening lipid disorders.

Progress Note - [REDACTED], M.D. - [REDACTED] Pages 537-538. The patient had feelings of his ears being plugged again. He was status post bilateral myringotomy and tubes. He has a long history of eustachian tube dysfunction secondary to chronic sinusitis. The last culture was positive for clindamycin inducible resistant Staphylococcus. He was to have an 8-week follow-up in 10/2011. Allergy notes were reviewed with need for new asthma medications. Recently his ears have had some drainage. He was unsure if tubes were present. Assessment: Otorrhea. Tympanometry and ciprofloxacin-dexamethasone were ordered. He was to follow up in 14 days to see if right tube granulation had resolved and tube was visible. His sinusitis was under good control with excellent compliance with allergy management. He had some element of chronic disease secondary to polyp triad.

Progress Note - [REDACTED], M.D. - [REDACTED] Page 538. The patient was seen to follow up his chronic suppurative otitis media, sinusitis, and asthma. His ear on the left felt full and had less drainage than usual. The patient was advised to soak ear for 3 days prior to the next appointment and Dr. [REDACTED] would try to debride tube and save it. The patient was also instructed to do saline irrigations nasally and be sure to use all allergy medications.

Progress Note - [REDACTED], M.D. - [REDACTED] Page 539. The patient's tubes were occluded last visit and he had been soaking with Ciprodex. His left ear tube was removed to visualize possible middle ear foreign body and extract that as well. Replacing of tube was also done. Ultrasil collar button tube was then inserted and Ciprodex was applied. This would be rechecked with audiogram in 3 months. He was told to continue with allergy and sinus medications.

Progress Note - [REDACTED], M.D. - [REDACTED] Pages 541-543. The patient presented with headache, facial pressure, and discolored nasal discharge for 3 days. He also had cough, wheezing, and dyspnea. His condition was gradually worsening. His sinusitis comorbidities included allergic rhinitis, nasal and/or sinus polyps, asthma, and history of recurrent sinusitis. Assessment/Plan: 1. Asthma intrinsic with acute exacerbation. Prednisone was dispensed. 2. Acute sinusitis. Amoxicillin was prescribed. Symptomatic treatment with fluids, vapor, and analgesics were indicated.

Progress Note - [REDACTED], M.D. - [REDACTED] Pages 543-544. The patient had sleeping problems. He was snoring and tired. He was worried about apnea and would wake up, feeling like he was choking, and had mild draining in ear. He recently had sinusitis. He responded to antibiotics and prednisone. He would like to get a suction machine for his ears. Assessment/Plan: 1. Sleep disturbance. His history and physical examination were consistent with probable obstructive sleep apnea. He was given a referral to sleep disorder specialist and was to follow up post polysomnogram. 2. Otorrhea. All manner of medical therapy had failed to control his otitis media, so Dr. [REDACTED] would treat his recurrent exacerbations with drops and suction machine if needed. This helped the patient in the past, but it broke, and he had new insurance. Ciprofloxacin would also be provided. 3. Chronic sinusitis. The patient was advised to take Zylflo since in the past he seemed to do much better with regards to his sinuses and ears when he was taking this.

Medical Report - [REDACTED], M.D. - [REDACTED] Pages 1354, 1233. The patient was seen in consultation. The patient had not been seen by Dr. [REDACTED] in nearly 1 year. The patient complained of more chest congestion and some wheezing. His ACT score was 17. His lung function was relatively stable with an FEV1 of 55%. Assessment: 1. Asthma. 2. Chronic sinusitis. He was trying Dulera. Advair would be held off, while Zylflo, Nasonex, aspirin, Prilosec were continued. Singulair would possibly be added back as well once it became generic. He would have albuterol and prednisone as needed.

Progress Note - [REDACTED], M.D. - [REDACTED] Page 544. The patient had worked hard to lose weight and noted that his snoring had ceased. He had no need for antacids and now his BP had decreased. The plan was to start him on Ciprodex and continue with healthy lifestyle changes.

Progress Note - [REDACTED], M.D. - [REDACTED] Pages 544-546. The patient complained of headache, facial pressure and discolored nasal discharge for 3 weeks. He also had cough and ear drainage. His symptoms were gradually worsening. Assessment/Plan: 1. Acute sinusitis. 2. Chronic suppurative otitis media. 3. Asthma. 4. Need for prophylactic vaccination and inoculation against influenza. Doxycycline hyclate was prescribed. Influenza vaccination was also provided.

Progress Note - [REDACTED], M.D. - [REDACTED] Pages 546-548. The patient had been having cough/congestion/sore throat for the past 3 days. He also had some shortness of breath. He has a history of asthma and was on Advair and albuterol nebulizer. He felt like he was wheezing now also. He had some hemoptysis in the last couple days with harsh coughing at times. He just had similar symptoms a month ago which were treated with antibiotics and prednisone. Assessment/Plan: 1. Acute bronchitis. 2. Asthma. Prednisone and doxycycline hyclate were refilled.

Medical Report - [REDACTED], M.D. - [REDACTED] Page 1506. The patient was having coughing, wheezing, shortness of breath and chest tightness despite using Advair, Zylflo, Flonase nasal spray and aspirin. He had needed prednisone for the last 4 days as he had increased symptoms over the weekend. His ACT score at this time was 9. Assessment: 1. Asthma. 2. Allergic rhinitis/chronic sinusitis. 3.

Aspirin triad/Samter's triad. Dr. [REDACTED] would like the patient to have new laboratory studies. Dr. [REDACTED] was considering the patient for a research protocol as his aspirin desensitization did not appear to be controlling his asthma. In the office at this time, the patient had well over 30% reversibility.

Laboratory Report - [REDACTED] - [REDACTED] Pages 666-671. Total IgE and total CH50 complement were high, while 25-hydroxy vitamin D was low.

Medical Note - [REDACTED] Center - [REDACTED] Pages 1645, 1449. The patient presented with chest congestion and wheezing. For his asthma and chronic sinusitis, prednisone, doxycycline, Advair, and Zflo were dispensed. Vitamin D3 2000 IU was also prescribed.

Medical Note - [REDACTED] Center - [REDACTED] Pages 1292, 1309. The patient was seen regarding his asthma and he was asking for refills of his medications. His ACT score was 8. He was diagnosed with asthma/chronic obstructive pulmonary disease (COPD) and GERD. ENT consultation was recommended to get a second opinion. He was being referred to a gastroenterologist as well. His Advair, Zflo, and Nasonex were also provided.

Progress Note - [REDACTED], M.D. - [REDACTED] Pages 549-550. The patient was here for a neck issue. He was punched in the neck and was grabbed around the neck and clavicles on [REDACTED]. It hurt him to bend his neck. His voice was raspier and he had a sore throat. His lower back was also sore as he was dragged about 60 feet. He would like a referral to a gastroenterologist for his GERD. Protonix helped some, but his pain remained. He needed an ENT specialist referral. His allergist suggested a surgeon that worked with recalcitrant cases. Assessment/Plan: 1. Traumatic ecchymosis of neck – no evidence of fracture. Ice application and gentle stretching were suggested. 2. Persistent esophageal reflux. He was given a referral to a gastroenterologist. 3. Recurrent nasal sinus polyp. He was provided a referral to an ENT specialist. 4. Special screening examination for other specified viral disease. Baby Boomer age. Hepatitis C antibody would be checked.

Medical Report - [REDACTED], M.D. - [REDACTED] Page 1461, 1579. The patient was seen in consultation. His lower airflow obstruction remained present. His spirometry showed 43% FEV1 with 30% reversibility. His compliance to medication had not been pristine. He would use Advair, Zflo, Nasonex and aspirin. Dr. [REDACTED] had asked the patient to discuss with Dr. [REDACTED] seeing Dr. [REDACTED] in regards to whether surgical options were available through [REDACTED] for his chronic polypoid sinusitis and anosmia. Another alternative would be Dr. [REDACTED] in [REDACTED], who specialized in frontal and sphenoid disease.

Progress Note - [REDACTED], M.D. - [REDACTED] Page 554. The patient has had persistent nasal congestion, difficulty hearing, and ear drainage. He had a course of inhaled steroids, antibiotic, and antifungal nebulized which improved sense of smell. He had a refill, but had not taken it. He has had aspirin desensitization. He would like a referral to Dr. [REDACTED] as recommended by his allergist. Dr. [REDACTED] recommended the patient do the second round of the combination nebulized treatment and obtain an updated CT scan. Dr. [REDACTED] was concerned about an out-of-plan referral for the patient primarily because he had clear evidence of Samter's triad which could not be cured, but needed medical management and rare surgical intervention. Dr. [REDACTED] wanted to repeat the round of medical therapy, reassess the CT and then tailor the patient's therapy.

CT Scan of the Facial Sinuses without Contrast - [REDACTED], M.D. - [REDACTED] Pages 705-706. There were moderate left and mild to moderate right frontal sinus mucosal thickening without air fluid levels.

Suggestion of prior ethmoidectomies bilaterally. Severe opacification of the anterior and posterior ethmoid sinuses, bilaterally. Moderate to severe right greater than left maxillary sinus mucoperiosteal thickening without air-fluid levels. Status post bilateral uncinectomies and middle medial antrectomies. There was also suggestion of partial middle turbinectomies. Severe mucoperiosteal thickening within the sphenoid sinuses, with air-fluid level in the left sphenoid sinus. Suggestion of partial middle turbinectomies, bilaterally. There was moderate to severe mucosal thickening involving the residual middle and superior turbinates, with obstruction of the superior nasal passageways bilaterally, although there was some residual airway around the inferior turbinates. Mildly deviated nasal septum bilaterally with mild left-sided nasal spur. Moderate left paramedian inferior cerebellar encephalomalacia suggestive of prior left posterior inferior cerebellar artery infarction. Impression: 1. Status post bilateral uncinectomies, middle meatal antrectomies, partial middle turbinectomies, and ethmoidectomies. 2. Moderate to severe residual pansinus disease as above, with air-fluid levels in the left sphenoid sinus raising the possibility for an acute on chronic process. This should be correlated clinically. 3. Moderate to severe mucosal thickening in the nasal cavity causing obstruction of the nasal passageways around the superior and residual middle turbinates. 4. Evidence of old left posterior inferior cerebellar artery infarction.

Progress Note - [REDACTED], M.D. - [REDACTED] Page 555. The patient had not yet taken the last round of inhaled combination of antibiotic and antifungal prescribed by Dr. [REDACTED]. The patient had persistent mild otorrhea and persistent congestion. He has a history of likely Samter's triad. He had aspirin desensitization. An ear culture was obtained and he would be treated based on the report. His sinus films were reviewed together. The patient might need ethmoid revision, but Dr. [REDACTED] would like to see him complete medical therapy as a full complete cure, but this was not possible for him with the polyposis.

Laboratory Report - [REDACTED] - [REDACTED] Pages 672-673. The ear culture with smear was abnormal for having *Pseudomonas aeruginosa* and mixed gram-positive flora. *P. aeruginosa* was intermediately susceptible to ciprofloxacin and gentamicin, while it was resistant to levofloxacin.

Progress Note - [REDACTED], M.D. - [REDACTED] Page 555. The patient had not completed the combination inhalational antibiotic. He has not had the vitamin D level rechecked. His ear culture had *Pseudomonas* which was not sensitive to ciprofloxacin/levofloxacin. He was noted to be taking Tobradex. Assessment: Vitamin D deficiency. This was more prevalent in patients with sinusitis. His vitamin D level would be rechecked with supplement. He was ordered to complete inhalational antibiotic prednisone course. He felt better at coastal environment and was now considering relocation at retirement. Surgery would not be curative at this time. He would be rechecked after completion of medical therapy to assess his residual symptoms.

Laboratory Report - [REDACTED] - [REDACTED] Page 673. The 25-hydroxy vitamin D test was within normal limits.

Progress Note - [REDACTED], M.D. - [REDACTED] Pages 556-557. The patient was using all of his inhalers for his allergy and asthma. He complained of thick green phlegm and had drainage from the right ear. He had otitis media with drainage. He was also suspected to have sinus drainage. Augmentin was therefore prescribed. For his allergic rhinitis, he was given a new referral to an allergist and was provided prednisone.

Progress Note - [REDACTED], M.D. - [REDACTED] Pages 2206-2209. The patient was seen to follow up on his asthma. He was a Samter's triad patient and underwent aspirin desensitization by Dr. [REDACTED]. The patient just finished treatment of prednisone and Augmentin that was prescribed by Dr. [REDACTED] after having congestion and difficulty breathing. At this time, the patient was feeling better, but he still had chest tightness. He has had allergy testing 5 years ago with positive results for molds. He was taking Advair, Zflo, Nasonex and aspirin. He had a CT scan of his sinuses by Dr. [REDACTED]. He has had polyp surgery 4 times since 1984. Assessment: 1. Asthma. 2. Chronic sinusitis. 3. Allergic rhinitis due to other allergen. 4. Upper respiratory infection, adverse effect of correct medicine properly administered. He had aspirin desensitization and is currently on aspirin therapy. Examination showed polyps in the nasal passages, bilaterally. Both tubes were in place, but were currently draining. He was to continue Ciprodex drops given by Dr. [REDACTED]. His ACT score was 16. His asthma control test with a score below 20 indicated incompletely controlled asthma. Based on this, Dr. [REDACTED] reviewed environmental control and discussed continuation of controller medications, management of comorbidities, and self-evaluation of symptoms. A spirometry was performed at this time which revealed airway obstruction, but the results were one of his better outcomes. Dr. [REDACTED] correlated this to the patient recently completing a course of prednisone. Alvesco and Advair were refilled. Prednisone was also given as a rescue in case his symptoms flare. The patient could use Xopenex for a rescue inhaler.

Spirometry Report - [REDACTED] - [REDACTED] Page 1520. Interpretation: Severe airway obstruction with low vital capacity.

Progress Note - [REDACTED], M.D. - [REDACTED] Pages 2210-2211. The patient was prescribed Alvesco, Advair, Nasonex, and Xopenex HFA.

Progress Note - [REDACTED], M.D. - [REDACTED] Pages 2212-2215. The patient returned for a follow-up of his asthma. Since his last visit in 04/2014, he stated that his asthma was not controlled. He still continued to have nasal congestion, chest congestion, and recurrent headaches. He continued on Advair, Alvesco, Xopenex, and Zflo. Nasal irrigation with hypertonic saline was indicated. His ACT score at this time was a 7. The patient was recommended to schedule an appointment to see Dr. [REDACTED] for chronic sinusitis. At this time, Advair would be refilled. The patient would also be started on tobramycin with betamethasone nasal irrigation and a higher dose of prednisone for the next 7 days. He would continue using Xopenex HFA as needed. He stated that his last CT sinus scan was ordered in 01/2014. He was given samples of Advair, Alvesco, Ventolin and a naso touch sinus irrigator.

Progress Note - [REDACTED], M.D. - [REDACTED] Pages 2216-2217. Alvesco was refilled.

Progress Note - [REDACTED], M.D. - [REDACTED] Pages 2220-2223. The patient returned due to his asthma that caused him to wheeze. He also had chest tightness and shortness of breath. Since the last visit, his symptoms seemed to be unchanged. At his last visit, he was given oral prednisone which helped, but he noted that it was more effective in past times as it was this time. His tobramycin in the rinses only gave him temporary relief. His CT scan done in 01/2014 revealed nasal polyps. Dr. [REDACTED] was on the fence as to whether or not the patient needed surgical intervention or if this could still be treated with medical management. The patient was using Advair, Alvesco, Zflo and Xopenex HFA as his rescue inhaler. His ACT score was 9. His lung sounds were diminished at the bases. He was therefore suggested to take the referral for a second opinion to [REDACTED] per Dr. [REDACTED]'s recommendation. The patient noted that the time that he had a combination of three medications via the nasal atomizer from ASL worked the best for him.

Medical Report - [REDACTED], M.D. - [REDACTED] Page 1515. The patient had been a patient of Dr. [REDACTED]'s practice for over 8 years. The patient has a history of severe asthma, chronic sinusitis, aspirin allergy, and acid reflux, among other medical problems. He was actively undergoing intensive medical and surgical treatment for these problems. His asthma and sinusitis had been particularly difficult to treat of late. He required regular and inhaled therapy for his asthma and also used a rescue inhaler when he had increased symptoms. When he had an infection, exposure to airway irritants and severe stress, he was quite prone to coughing, wheezing, shortness of breath, chest tightness and other symptoms such as agitation, confusion and depressed symptoms. He needed regular access to all of his medications in addition to at times requiring urgent or immediate medical attention for breakthrough symptoms.

Progress Note - [REDACTED], M.D. - [REDACTED] Pages 561-564. The patient presented with difficulty breathing and left ear pain. He ran out of albuterol and was in the red zone for asthma. He had been experiencing this for 3-4 weeks and it was getting worse at this time. He was taking his asthma medications compliantly. He was on Singulair before, but it was tapered off because he was under such good control. He was not on it now. He was feeling really out of breath. His left ear was blocked. He had ear tubes and his left ear was draining clear fluid. His respiratory rate was 20. His oxygen saturation readings were 93% at 1554 hours, 94% at 1600 hours, and 96% at 1655 hours. Assessment/Plan: 1. Asthma exacerbation. He was prescribed albuterol, methylprednisolone, and montelukast sodium. He was advised to follow up with his primary doctor if his asthma symptoms were more than twice weekly in the future. 2. Left ear drainage, likely allergic drainage. Prednisone should help with this.

Progress Note - [REDACTED], M.D. - [REDACTED] Pages 2230-2231. Xopenex was refilled.

Progress Note - [REDACTED], M.D. - [REDACTED] Pages 2234-2238. The patient felt that his asthma was doing a little better. He was currently on Advair and Alvesco. He would like a refill on his medications for Advair and Zflo. He had been taking Zflo along with Singulair. He had not gone to get a second opinion with UCSF per Dr. [REDACTED]'s recommendation for an ENT second opinion on his nasal polyps. Dr. [REDACTED] was his previous ENT. The patient was still having issues with his breathing through his nose as he felt the polyps might be growing. Assessment: 1. Asthma extrinsic. 2. Allergic rhinitis due to pollen. 3. Polyp(s) of nasal cavity. 4. Esophageal reflux. ACT score at this time was 19. He was instructed to rinse his mouth/brush teeth after all inhaled medications. It was discussed in detail the need for regular oral/inhaled therapy to prevent symptoms, decrease inflammation, and protect against airway narrowing. Dr. [REDACTED] talked about staying with either Zflo or Singulair although not to be on both of the medications at the same time. The patient would like to stay with Zflo and he would stop taking Singulair. He stated that he would like to try a new inhaler that was comparable to Alvesco. Dr. [REDACTED] stated that the patient could try a sample of Aerospan. Samples of Qnasl and Aerospan, as well as a prescription, were sent to his pharmacy. He would be sent to [REDACTED] for bloodwork. The patient would also be referred for consultation with Dr. [REDACTED] for further evaluation and management of his condition as Dr. [REDACTED], who was originally recommended, did not take the patient's insurance, and the patient was interested in seeking a second opinion with an ENT who was practicing locally.

Progress Note - [REDACTED], R.N. - [REDACTED] Pages 2239-2240. The patient called the prescription line and left a message asking for a prescription for Qnasl spray to his mail-order pharmacy.



Laboratory Report - [REDACTED] - [REDACTED] Pages 674-676. CBC showed low relative lymphocyte count. Comprehensive metabolic panel revealed increased glucose. The 25-hydroxy vitamin D was low.

Progress Note - [REDACTED], R.N. - [REDACTED] Pages 2241-2242. A message was left for the patient to inform him that his labs collected on [REDACTED] showed vitamin D deficiency. Because of this, he was prescribed Vitamin D3 2000 IU.

Progress Note - [REDACTED], P.A. - [REDACTED] Pages 565-566. The patient had left ear pain for 2 months. He had tubes in ears due to having chronic ear infections. These tubes were placed 3 years ago. He had some ear drainage in the last 2 days. There was also pressure in the left ear and behind the ear. It felt blocked and painful for 2 months. He also had nasal drainage and congestion. For the left mastoiditis and left ear pain, he was prescribed amoxicillin.

Progress Note - [REDACTED], M.D. - [REDACTED] Pages 567-568. The patient has a long history of left ear suppurative otitis and was seen for recurrent infection again. Refill of Augmentin was requested and referral to alternative ENT specialist for consultation was requested. He claimed to have chronic discharge from the left ear. He also had left submandibular lymphadenitis and pain. His hearing was unchanged. For the chronic suppurative otitis media, he was given a referral to an ENT specialist and was instructed to continue his antibiotics for now.

Progress Note - [REDACTED], M.D. - [REDACTED] Pages 2245-2248. The patient was seen for evaluation of his left ear pain. This was associated with tinnitus in the left ear. Assessment: 1. Serous otitis media. 2. Eustachian tube dysfunction. 3. Polyp(s) of nasal cavity. 4. Chronic rhinitis. 5. Asthma extrinsic. He stated that for 3 months he had felt pressure and blockage in his left ear. He went to Urgent Care 2 weeks ago and was put on amoxicillin and told to see an ENT specialist. The patient has had multiple sinus surgeries for recurrent polyps and was being treated by Dr. [REDACTED] for allergies. Generalized rhinitis symptoms were present. The patient was prescribed Ciprodex and would follow up with Dr. [REDACTED] in 3 weeks. A CT scan of the sinuses was also ordered. He would be a good candidate for the sinus study that Dr. [REDACTED] was currently involved in.

CT Scan of the Facial Sinuses without Contrast - [REDACTED], M.D. - [REDACTED] Pages 708-709. Impression: Sinonasal polyposis had progressed when compared to the previous examination. Despite functional sinus surgery, there was complete opacification of the ethmoid air cells with near complete opacification of the remaining paranasal sinuses. There was also substantial compromise of the nasal passages. No associated air-fluid levels. The nasoastral windows were narrowed, but patent bilaterally. Posterior drainage pathways were opacified.

Progress Note - [REDACTED], M.D. - [REDACTED] Pages 2251-2255. The patient was seen for his bilateral ear pressure and chronic sinusitis. He has a long-standing history of Samter's triad with chronic sinusitis and nasal polyposis and had previously undergone sinus surgery 4 times, most recently with Dr. [REDACTED] 3 years ago. Additionally, the patient had long-standing chronic otitis media and previously underwent bilateral myringotomy with tube placement at least 3 times, most recently again about 3 years ago. He had chronically draining ears bilaterally. He did undergo aspirin desensitization with Dr. [REDACTED] 2 years ago and was on a maintenance full-strength aspirin. The patient continued to follow up with Dr. [REDACTED]. No additional sensitivities had been identified. Binocular microscopy and nasal endoscopy were performed at this time. Physical and binocular microscopy revealed PE tubes in place bilaterally with purulent debris which was suctioned out. The left ear drainage was sent for culture.

Nasal endoscopic examination also showed polyps in the middle meatus, bilaterally. Mucous was debrided, bilaterally. Dr. [REDACTED] reviewed the patient's recent CT sinus which showed bilateral pansinus mucosal disease with recurrent sinusitis. The patient was to continue with Ciprodex drops and Dr. [REDACTED] would call the patient with culture results. Given his history, Dr. [REDACTED] might never get his ear to stop draining. His recurrent polyposis was discussed and Dr. [REDACTED] suggested the patient to consider the RESOLVE II clinical trial instead of additional surgery. The patient was started on oral prednisone. As part of Dr. [REDACTED]'s treatment plan, he was prescribing prednisone which was a systemic corticosteroid.

Laboratory Report - [REDACTED] - [REDACTED] Page 676. The left ear culture with smear was abnormal for having Pseudomonas aeruginosa. P. aeruginosa was intermediately susceptible to cefepime and gentamicin.

Progress Note - [REDACTED], M.D. - [REDACTED] Pages 2258-2261. The patient was doing much better since being on Ciprodex drops and oral prednisone. Physical and binocular microscopy revealed PE tubes in place bilaterally with no discharge. Nasal endoscopic examination revealed polyps in the middle meatus bilaterally, improved since his last visit. Treatment options were discussed for his chronic sinusitis with nasal polyposis including continued medical management, revision surgery, or participating in the RESOLVE II trial investigating a mometasone eluting sinus stent. He was interested in the latter and a study screen was performed at this time. He would discontinue the ear drops and Dr. [REDACTED] would monitor for drainage. RESOLVE II screening was performed at this time. The patient was also counseled to increase activity and eat a low-fat, high-fiber diet, including fruits and vegetables.

Progress Note - [REDACTED], M.D. - [REDACTED] Pages 2262-2263. The patient presented for the RESOLVE clinical trial visit.

Progress Note - [REDACTED], R.N. - [REDACTED] Pages 2264-2265. The patient came in at this time for refills of his Zylfo and Advair. He could only have 1 refill and needed to set up a follow-up appointment.

Progress Note - [REDACTED], M.D. - [REDACTED] Pages 2266-2267. The patient presented for the RESOLVE II clinical trial visit. Advair was also refilled.

Progress Note - [REDACTED], M.D. - [REDACTED] Pages 2270-2271. Floxin otic was prescribed due to the patient's chronic otorrhea. This visit was part of RESOLVE II clinical trial.

Progress Note - [REDACTED], M.D. - [REDACTED] Pages 571-574. The patient had bilateral ear pain and it felt plugged for 2 weeks. He also had cough and difficulty breathing. At baseline, he always had coughing. He was compliant with his asthma/allergy meds. It had become worse in the past 2 weeks. This started with nose congestion and chest congestion. He had trouble sleeping, because of coughing and feeling out of breath. He was using his albuterol often and got only temporary relief. He had ear tubes and they were draining, but the pain was still present. He had been sucking lots of liquid out of ears. His respiratory rate was 20. His oxygen saturation was 96%. X-rays were ordered because of his difficulty breathing. Amoxicillin was dispensed for his bilateral otitis media, while prednisone was indicated for his asthma exacerbation. He declined breathing treatment in this office at this time. He was advised to continue all his asthma and allergy medications including albuterol.

X-rays of the Chest - [REDACTED], M.D. - [REDACTED] Pages 709-710. Mild peribronchial thickening predominately within the right superhilar region though and it was similar to appearance that was present within the bilateral infrahilar regions as well. The hemidiaphragms were slightly flattened. Impression: No focal consolidation or large effusion. Peribronchial thickening as described which could be seen with reactive airway disease or other etiologies. Recommended clinical correlation and follow-up to evaluate for interval improvement/resolution.

Progress Note - [REDACTED], M.D. - [REDACTED] Pages 2272-2273. Pulmicort was prescribed.

Progress Note - [REDACTED], M.D. - [REDACTED] Pages 574-575. The patient's right ear was full and draining. He would get increase in nasal cases and chronic post nasal drip. He had a hard time with seeing any cure for his problem. He had Samter's triad and had not completed inhalational steroid antibiotic course. Vitamin D was pending. He had Propel which helped. His endoscopy revealed max ostium open bilaterally, mucosa with mild generalized edema, but not exudate. His right ear was draining and PE tubes were patent. Polypoid degeneration of middle turbinate and nasal vault. Assessment/Plan: Vitamin D supplementation and completion of budesonide irrigation were indicated. He has a history of lack of follow-up after treatment. He had a difficult genetic problem and he needed a close follow-up after any given treatment to assess efficacy and determine further course of action.

Laboratory Report - [REDACTED] - [REDACTED] Pages 677-678. The ear culture with smear was abnormal for having Staphylococcus aureus and Achromobacter denitrificans. S. aureus was sensitive to all antibiotics. A. denitrificans was intermediately susceptible to levofloxacin and tobramycin, while it was resistant to cefepime, ceftriaxone, ciprofloxacin, and gentamicin.

Progress Note - [REDACTED], M.D. - [REDACTED] Pages 2274-2278. The patient complained of chest congestion, chest tightness, shortness of breath, productive cough with green mucus, ear drainage, hearing loss, loss of smell, tinnitus, and right-sided facial pressure. Three weeks ago, he finished antibiotics and prednisone due to chest congestion, chest tightness, and wheezing. He normally had respiratory complications every 2 months. He, however, was not interested in restarting on Xolair injections at this time. He was seen on [REDACTED] by Dr. [REDACTED], his ENT doctor, and was informed he had bacterial infection in his right ear, so culture was taken at that time. He was prescribed an antibiotic, which he started last night. He tried Aerospan and Dulera in the past with no improvement and went back to Advair; however, he was complaining of throat irritation and a filmy sensation on his tongue since starting this medication. He last used his rescue inhaler yesterday. He underwent a clinical trial of Nasonex with no improvement. He was now on budesonide for his nasal congestion. He was advised to continue using budesonide nasal spray, Zyflo, Alvesco, Advair, aspirin, Prilosec, vitamin D3 2000 and Xopenex HFA. He was also recommended to follow up with his PCP to have an evaluation with an ophthalmologist due to his prolonged steroid use. Dr. [REDACTED] would follow up with the patient in 1 month and planned to do allergy testing at that time as it had been several years since his last allergy test. The patient was advised to remain antihistamine-free prior to that test for 5-7 days.

Progress Note - [REDACTED], M.D. - [REDACTED] Pages 2279-2281. Zyflo was refilled.

Progress Note - [REDACTED], M.D. - [REDACTED] Pages 2283-2288. The patient presented for re-evaluation of allergies and possible allergy testing. He noted that he had been doing the same since his last encounter with the office. He was treated an antibiotic for the discolored ear drainage. He was unable to remember what antibiotic he was prescribed. He reported a bloody discharge from the right ear. He had an appointment with Dr. [REDACTED] next week. The patient was previously allergy tested 8

years ago and was positive to molds. He stated his symptoms were year-round. He also noted he had been on 5 courses of prednisone in the last 12 months. His ACT score was 10; thus, allergy testing was deferred due to having an asthma exacerbation. He should continue his normal medication regimen and start Spiriva Respimat in addition to Alvesco. He was instructed to rinse his mouth/brush teeth after all inhaled medications. If his new medication regimen did not help alleviate his asthma symptoms, he might be a candidate for Nucala treatment or bronchial thermoplasty.

Progress Note - [REDACTED], M.D. - [REDACTED] Pages 575-576. The patient was feeling better in general. He had some increase in sinus and ear pressure when the meds wore off. He felt well after the triple med sinus nebulizer regimen. His right ear was draining. Assessment: 1. Samter's triad. 2. Chronic sinusitis. 3. Chronic otitis media. He was to use Pulmicort and Qnasl. Bactrim OS was also indicated. He might need a revision surgery. He was having maximum medical therapy for asthma and allergies.

Progress Note - [REDACTED], M.D. - [REDACTED] Pages 2289-2294. The patient's asthma was currently stable and he would continue his current medications. He was currently being treated with an antibiotic, sulfamethoxazole, for an ear infection. Dr. [REDACTED] talked with the patient about bronchial thermoplasty and explained the procedure in depth. The patient was concerned about whether his insurance would pay for it, but he also stated that he was retiring in 1 year and would be submitting paperwork due to having symptoms due to his work environment. He was informed that he was breathing at about 53% for his age. His ACT score was 13. He was recommended to continue using Advair HFA, Alvesco, Xopenex HFA, Zyflo CR, Qnasl, omeprazole, aspirin, hydrocodone, cyclobenzaprine, and naproxen. He also had Xopenex Solution for a nebulizer. In addition, he was provided a sample of Aerospan which he could use until he got his Alvesco. Laboratory studies were ordered as well.

Spirometry Report - [REDACTED] - [REDACTED] Page 1260. Interpretation: Moderately severe obstruction with low vital capacity.

Laboratory Report - [REDACTED] - [REDACTED] Pages 678-681. The allergen panel revealed abnormal IgE levels for olive tree, P. notatum, and A. fumigatus. The total IgE was high, while 25-hydroxy vitamin D was low.

Progress Note - [REDACTED], M.D. - [REDACTED] Pages 2295-2300. The patient's symptoms were still present with not much of any improvement. He had been on more than 4 prednisone courses without improvement. His symptoms were persistent despite multiple medications, and he had tried and failed several ICS/LABA combinations without any change in his condition. Laboratory studies were recently completed as well. His ACT score was 13. The patient was interested in reviewing with Dr. [REDACTED] whether he would be a candidate for Workers' Compensation as his symptoms were refractory to his current treatments. Kenalog injection was administered at this time. He was informed that bronchodilators could increase blood pressure levels. Due to severity of his symptoms, he would be provided an off-work note until he completed the bronchial thermoplasty surgery. In the meantime, he was to stop using Advair and start Breo in its place. He was also to continue using Xopenex solution via nebulizer, Zyflo CR, Alvesco, and Vitamin D 5000IUs.

Progress Note - [REDACTED], R.N. - [REDACTED] Pages 2304-2306. Off-work note would be held off until the patient was seen for a follow-up appointment with Dr. [REDACTED]. The patient was told to start

Nucala first and then he would be referred for bronchial thermoplasty. He would be on Nucala for 3 months first. He was also to continue with his current medications.

Medical Report - [REDACTED], M.D. - [REDACTED] Page 904. The patient's asthma had been getting worse and less controlled as of the last couple of years. He has had to be on several rounds of prednisone. He had tried many inhaled therapy combinations without relief of his symptoms. He was now being referred to pulmonology for bronchial thermoplasty. He had tried Spiriva, Pulmicort, Dulera, Qvar, Advair HFA and Advair Diskus. None of these in combination had worked for asthma control. He had also been on Xolair injections. He had an adverse reaction of dizziness and had to stop Xolair. He was now being considered for Nucala injections. His current treatment was Advair and Alvesco. This was keeping his asthma more controlled than any other combinations of medications.

Progress Note - [REDACTED], M.D. - [REDACTED] Pages 2311-2316. The patient was seen for a plan-of-care evaluation. He was administered a Kenalog shot at last visit which had slightly improved his breathing; however, he was still wheezing and had elevated heart rate and high BP. He had looked over his past medical records and had noticed an increasing of his blood pressure consistently over the last few years. He was unable to work or exercise without having to stop due to his breathing and pounding heart. He worked as a [REDACTED] and he stated that his job was very physically demanding and these symptoms made this difficult. He noted that his past treatments of prednisone and steroids were more beneficial than they had been recently. He had noticed a marked decrease in their effectiveness. His ACT score was 11. Assessment: 1. Severe persistent asthma with acute exacerbation. 2. Other allergic rhinitis. 3. Chronic pansinusitis. 4. Polyp of nasal cavity. It was discussed that Nucala might be a more effective form of treatment than the previously tried Xolair; thus, he was prescribed Nucala. The patient signed consent for Dr. [REDACTED] to re-request his previous records from Capital Allergy as Dr. [REDACTED] did not receive his complete chart after the previous request. Nucala should be started and consistent for 3-6 months; after that time, Dr. [REDACTED] was recommending the first of 3 treatments of a bronchial thermoplasty. In the interim, the patient should continue his current medications as prescribed with the ability to choose between Breo or Advair as previously prescribed. He was advised to obtain the necessary paperwork from his work in order to begin his Workers' Compensation process.

Progress Note - [REDACTED], M.D. - [REDACTED] Pages 576-577. The patient was seen regarding his Samter's triad, chronic sinusitis, and chronic otitis media. He felt better after the antibiotic. He was tired all of the time and was not refreshed after sleep. He was taking all of the medications prescribed. He was wondering whether all of the work exposure to dirty environments and infections had contributed to his chronic disease. He was very worried about the 50% lung capacity recently diagnosed. A revision ethmoidectomy was recommended. Propel stents were also indicated along with Bactrim and sleep study. He would need an image-guidance system given the atrophic bilateral lamina papyracea. He was very interested in establishing the connection between his work jail exposure and upper respiratory disease. Initially, he worked in a smoky environment without ventilation.

Progress Note - [REDACTED], M.D. - [REDACTED] Pages 2317-2319. Prescription for Alvesco was approved through [REDACTED]. The prescription was sent to the pharmacy.

Workers' Compensation Claim Form - [REDACTED] Page 149. Mr. XXXXX claimed to have sustained a cumulative trauma injury through [REDACTED] during the course of his employment. He developed hearing loss, acid reflux, hypertension/cardiovascular issues (presumptive), and lung issues/asthma. He also had injuries to the neck, back, and hips.

Application for Adjudication of Claim - [REDACTED] Pages 154-158. Mr. XXXXX allegedly sustained a cumulative trauma injury from [REDACTED] through [REDACTED], while employed as a [REDACTED] with the County of YYYYYY [REDACTED] Department. He developed hearing loss, acid reflux, hypertension/cardiovascular issues (presumptive), and lung issues/asthma. He also had injuries to the neck, back, and hips.

Progress Note - [REDACTED], M.D. - [REDACTED] Pages 2328-2333. Dr. [REDACTED] had previously requested the patient's medical records from [REDACTED]; however, he did not receive all of his records. There were no changes in his condition since his last visit. His ACT score was 13. He continued his current medications consisting of Advair, Alvesco, Qnasl, Prevacid, and Xopenex. The patient had recently seen Dr. [REDACTED] and she was recommending sinus surgery to remove polyps. The patient would be sent for a full pulmonary function test at [REDACTED] Health for further evaluation of his lung functions. Dr. [REDACTED] had not been able to improve his breathing via inhaled medications. Dr. [REDACTED] was still working with the insurance company for authorization. The patient should continue to follow up with Dr. [REDACTED]. If Dr. [REDACTED] was recommending surgery, Dr. [REDACTED] felt the patient should move forward. His current medications would also be continued.

CT Scan of the Sinus Stealth Protocol - [REDACTED], M.D. - [REDACTED] Pages 2369-2370. Impression: 1. Function endoscopic sinus surgery. 2. Sinonasal polyposis and chronic pansinusitis. 3. Mastoiditis and otitis media.

Progress Note - [REDACTED], M.D. - [REDACTED] Pages 1711-1714. [REDACTED] denied the request for Nucala and indicated that it had to be submitted through the medical side of the patient's benefits.

Progress Note - [REDACTED], M.D. - [REDACTED] Pages 1719-1721. Dr. [REDACTED] received a call from Andrea at [REDACTED] stating they could not service the patient through his pharmacy side and she called [REDACTED] to try to expedite the process on the medical side. Unfortunately, she was told that since the patient was not self-injecting, that Nucala would have to be a buy-and-bill under his medical benefits.

Progress Note - [REDACTED], M.D. - [REDACTED] Pages 1722-1725. Dr. [REDACTED] called [REDACTED] to check status of Nucala and spoke to Natalia who said they did not receive the first prior authorization that was faxed on [REDACTED]; therefore, it was requested that the original prior authorization request be faxed.

Progress Note - [REDACTED], M.D. - [REDACTED] Pages 1726-1729. Spiriva Respimat was prescribed.

Progress Note - [REDACTED], M.D. - [REDACTED] Pages 584-585. The patient was seen for a preoperative evaluation and treatment discussion. He had chronic sinusitis, polyposis, and otorrhea. He indicated that he felt better in general and being out of the workplace helped. He believed the exposure to all of the bacteria and viruses at work with stress was a major factor in his illness. There was potential improvement in his situation by clearing the polypoid degeneration left ethmoid and improving access to the frontal sinuses and right ethmoid. He had some high-risk factors with origin of the middle turbinate in the fovea and extremely narrow diameter to the lamina papyracea. It might not be possible to pass a balloon or curette. Examination of the middle meatus to make sure it was in appropriate contact with the infundibulum would be undertaken. After the patient left the office, Dr. [REDACTED]

confirmed whether the patient was on aspirin as there was a chart entry he had gone through desensitization. This could be a problem going forward with the surgery.

Progress Note - [REDACTED], M.D. - [REDACTED] Pages 1730-1732. Qnasl was refilled.

Medical Report - [REDACTED], M.D. - [REDACTED] Page 1517. Regarding the planned endoscopic sinus surgery, the patient should stop the aspirin in the perioperative phase. The timing of stopping 7 days prior was appropriate. Once he had stopped his aspirin for more than 48 hours, he needed to be considered no longer in the desensitized state to aspirin. He would need to have a repeat aspirin desensitization performed in the postoperative phase and should not start it orally on his own without medical advice and supervision. As his surgery was scheduled for [REDACTED], it would be appropriate for him to be scheduled for consultation in the office on or around [REDACTED] to discuss reinstatement and re-desensitization for his aspirin. He should continue his other regular medications including Advair, Alvesco, Qnasl, Prevacid, Zylflo CR, and Xopenex HFA as needed.

Progress Note - [REDACTED], M.D. - [REDACTED] Pages 1736-1739. Dr. [REDACTED] called [REDACTED] to check status of Nucala and they said it was approved. Dr. [REDACTED] was advised to use OptumRX for the delivery.

Correspondence - [REDACTED], L.C.S.W. - [REDACTED] Page 100. The patient would need to be off for 4 months until [REDACTED]. He would continue treatment with his medical doctors.

Progress Note - [REDACTED], M.D. - [REDACTED] Pages 1745-1747. A copy of the patient's authorization approval for Nucala was faxed.

Pulmonary Function Test - [REDACTED], M.D. - [REDACTED] Page 1355, 2367-2368. Impression: The patient did have mild obstructive process, which had significant bronchodilator response. Unsure if the patient had smoked or not, but for sure he did have significant asthma; however, after the postbronchodilator response, the patient did not correct to normal; therefore, there was some reversibility, but did not reverse all the way; therefore, most likely had been airway remodeling causing more of a chronic obstructive pulmonary disease process. The patient's lung volumes were essentially normal, but essential with air trapping. The patient's diffusion capacity was normal. He did have significant asthma.

Medical Report - [REDACTED], M.D. - [REDACTED] Page 1601. Dr. [REDACTED] had been following the patient for his history of severe hyperplastic chronic rhinosinusitis, otitis media with effusion, severe persistent asthma, gastroesophageal reflux, and aspirin sensitivity along with nasal polyps. Dr. [REDACTED] had been following the patient since 2007. The patient had come to more than 30 medical appointments, had repeated spirometry, CAT scans, sinus surgery, environmental allergy testing, immune deficiency workup, and required hospitalization for aspirin desensitization. Dr. [REDACTED] recently found out that the patient had been unable to fulfill his work duty. Dr. [REDACTED] would be happy to forward all documentation of his severe refractory medical condition. The patient also stated that he has had significant exposure to infectious and toxic agents within his work environment.

Progress Note - [REDACTED], M.D. - [REDACTED] Pages 1751-1756. The patient was sent to [REDACTED] for a full pulmonary function testing (PFT) and the results were discussed with him at this time. At the last visit, Nucala was in the works and pending insurance authorization. The patient noted that there had been no changes in his symptoms. He was ordered to continue his current medications and was

scheduled for sinus surgery with Dr. [REDACTED] on [REDACTED]. Dr. [REDACTED] felt this was a good option that would help reduce his nasal symptoms. The patient was told to stop aspirin 7 days prior to surgery.

Notice Regarding Denial of Workers' Compensation Benefit - Ms. [REDACTED], Workers' Compensation Claims Examiner - [REDACTED] Pages 190-192. After careful consideration, Workers' Compensation Office was denying liability for Mr. XXXXX's claim with a date of injury of [REDACTED]. Workers' Compensation benefits were being provisionally denied because they had not received all of Mr. XXXXX's prior medical records yet. Mr. XXXXX would not be attending a medical/legal evaluation prior to the decision date of [REDACTED], nor would his deposition be completed by the decision date of [REDACTED]; therefore, Workers' Compensation Office had not yet been able to complete discovery within the 90-day period. Upon receipt of your prior medical records, deposition testimony and medical/legal report(s), Workers' Compensation Office would reconsider their denial.

Progress Note - [REDACTED], M.D. - [REDACTED] Pages 1793-1795. Dr. [REDACTED] spoke with Dr. [REDACTED] regarding the patient's upcoming functional endoscopic sinus surgery. Dr. [REDACTED] had questions whether Dr. [REDACTED] felt that the patient was stable from a respiratory standpoint. It was explained to Dr. [REDACTED] that the patient's pulmonary function testing performed on [REDACTED] did show an obstructive process with bronchodilator reversibility. Dr. [REDACTED] felt that the patient was optimized as far as medication at this time, that his compliance was actually improved, that he had been off work for nearly 10 weeks, and in that timeframe the patient stated he had not taken any oral corticosteroids. The patient would be able to be off the aspirin for 10 days in the perioperative period and he would require re-desensitization, but this could be done in the office and not needed to be done in the hospital during the acute phase. The importance of leukotriene therapy and compliance with the other medications were also discussed. Finally, Dr. [REDACTED] explained to Dr. [REDACTED] that in many patients with aspirin-exacerbated respiratory disease, they would occasionally require oral corticosteroids in the preoperative phase. Dr. [REDACTED] indicated that he was willing to help the patient should he have symptoms before his surgery.

Progress Note - [REDACTED], M.D. - [REDACTED] Pages 1777-1780. Susan from [REDACTED] called stating they needed a prescription for Nucala faxed over; thus, Dr. [REDACTED] wrote a prescription for Nucala as it was not found under their medication portal.

Progress Note - [REDACTED], M.D. - [REDACTED] Pages 1781-1788. Qnasl was prescribed.

Progress Note - [REDACTED], M.D. - [REDACTED] Pages 585-588. The patient was scheduled for surgery for his sinus disease and was seen for a preoperative consultation for consultation clearance. His oxygen saturation was 92% and he had a normal electrocardiogram. Assessment and Plan: There was a low probability of adverse event during this surgery from a cardiovascular standpoint; thus, he could proceed with surgery.

Otolaryngology Preoperative Evaluation - [REDACTED], M.D. - [REDACTED] Pages 588-590. The patient had chronic sinusitis and asthma. He had obstruction of the right frontal sinus and left with ethmoid obstruction. He had complex asthmatic disease. He was compliant with his medications. He would be going off of his aspirin desensitization program for the surgery. Nucala was just approved, but it was not yet started. Assessment: Chronic sinusitis with frontal sinus ostia opacification. Dr. [REDACTED] would try to establish patency. This was difficult secondary to tight anatomy with the middle turbinate. An image guidance was needed. The patient understood that Dr. [REDACTED] might not be able to solve the chronic otorrhea, but would change out the ear tubes. The patient was to use his albuterol with a



nebulizer the morning of surgery and to keep up all of his pulmonary medications and then he would hold Diovan in the morning of surgery.

Laboratory Report - [REDACTED] - [REDACTED] Pages 686-690. Anaerobic and aerobic culture from the surgical site was positive for *S. aureus*. *S. aureus* was sensitive to ciprofloxacin, clindamycin, doxycycline, erythromycin, gentamicin, levofloxacin, oxacillin, rifampin, tetracycline, tigecycline, trimethoprim/sulfamethoxazole, and vancomycin. Fungus culture from the nasal did not show any fungus isolated in 4 weeks. No Acid-Fast Bacilli (AFB) was seen on concentrated smear and no AFB was isolated in 7 weeks on the culture. The ear culture with smear was abnormal for having *Staphylococcus aureus* and *Achromobacter denitrificans*. *S. aureus* was sensitive to all antibiotics. *A. denitrificans* was intermediately susceptible to levofloxacin and tobramycin, while it was resistant to ceftriaxone, ciprofloxacin, and gentamicin.

Surgical Pathology Report - [REDACTED], M.D. - [REDACTED] Page 700. The patient underwent bilateral endoscopic total ethmoidectomy and frontal sinus endoscopy and bilateral endoscopic maxillary antrostomy. Diagnosis: Right and left sinus contents, removal – Benign sinonasal tissue and bone with chronic inflammation. This was negative for a significant eosinophilic inflammatory component.

Progress Note - [REDACTED], M.D. - [REDACTED] Pages 1807-1809. The patient was called regarding his Nucala and that he would need to remain in the office for 2 hours after his first three injections and then remain for 30 minutes after. He also needed to bring his EpiPen to his appointments. He did not have a current EpiPen, so he was given one.

Progress Note - [REDACTED], M.D. - [REDACTED] Pages 590-591. The patient was postoperative day #2 of functional endoscopic sinus surgery. His ear tube was change. He had underlying severe asthma and chronic sinusitis. He also has a history of steroid-dependent asthma. At this time, his lungs were not good. He had not yet taken prednisone or other medications at this time. He noted that his lungs were better, but with the stress anticipating the surgery, he got really tight. Assessment/Plan: Chronic sinusitis and steroid-dependent asthma were noted. His need for steroids increased with stress. This was a known medical condition in patients who have been on recurrent steroids. His condition deteriorated at times of medical or other stress. He had an underlying respiratory condition which was susceptible to exacerbations with exposure to any upper respiratory infection. His frequent need for steroids and permanent lung scarring had been exacerbated by his frequent work exposure to the margins of society and stressful work. It was likely that if he had had an occupation without the exposure for all of those years, he would not be in as dire a condition as he was now. Although his work exposures were not the sole source of his problem, they certainly had affected his long-term outcome with his disease. For his current steroid need associated with surgery, he would take the dose prescribed. He would take his daily asthma and allergy medications. He would continue to irrigate. Culture with *Staph aureus* in ear and sinus and others were pending on gram stain and awaiting final sensitivities.

Progress Note - [REDACTED], M.D. - [REDACTED] Pages 592-593. The patient felt well. His ears were opened up. He had spontaneous dislodge of right propel with the irrigation. He had not restarted the aspirin. Regarding the chronic sinusitis, *Achromobacter* and *Staphylococcus aureus* were on the culture. Since the propel was out on the right, he would need to maintain oral prednisone for a few more days. He also needed to restart the aspirin therapy which might require desensitization protocol. He was advised to talk with Dr. [REDACTED] at this time as this was typically most effective if done within 4

weeks of surgery. The plan was to prescribe sulfamethoxazole-trimethoprim and prednisone. Saline irrigation would also be continued.

Progress Note - [REDACTED], M.D. - [REDACTED] Pages 593-594. The patient had some temporary improvement in his sense of smell. His ears were ventilating on and off as well. He had a satisfactory course, post functional endoscopic sinus surgery. He was to communicate with Dr. [REDACTED] regarding restarting aspirin desensitization. He was also to complete Bactrim for Staphylococcus aureus and Achromobacter.

Progress Note - [REDACTED], M.D. - [REDACTED] Pages 1814-1819. The patient was to follow up on his asthma and starting his first Nucala injection. The patient had a sinus polyps removal with Dr. [REDACTED] on [REDACTED]. He had felt a little relief after surgery. He noticed less ear pressure. Although, he still struggled with intermittent loss of smell. He was monitored for 2 hours after his injection. He was instructed to continue the same medication regimen. It was also discussed that Dr. [REDACTED] would be consulted on how the patient was to proceed with resuming aspirin daily as he had been off the medication since prior to his sinus surgery. The patient was advised to remain off work until such time as his severe asthma was deemed controlled with less complaint of difficulty breathing. It was also discussed that the patient might need an extension for his disability and time off work until a determination could be made with his response to the Nucala injections.

Progress Note - [REDACTED], M.D. - [REDACTED] Pages 594-595. The patient's ears and sinuses were better. His sense of smell improved, but he had increased chest cough which seemed to be coming from the chest only. Endoscopy showed some lateralization of the middle turbinate on the left (propel had early extrusion). After standard topical anesthesia with 4% xylocaine and 25% neosynephrine, suction tip was used to break synechiae. Assessment/Plan: Cough. Sputum sample were taken for respiratory culture with smear. He has a history suggestive of primary pulmonary infection rather than sequelae of chronic sinusitis. He had been on Bactrim for the Achromobacter and S. Aureus found on the ear and sinus cultures. His sinuses and ears were responding very nicely. Sputum culture would be done to rule out other opportunistic infection. If he developed early return of ear or sinus drainage, he was to restart the Bactrim for the Achromobacter/Staphylococcus.

Laboratory Report - [REDACTED] - [REDACTED] Pages 690-691. A respiratory culture with smear from expectorated sputum revealed Haemophilus influenzae.

Progress Note - [REDACTED], M.D. - [REDACTED] Pages 1824-1826. The patient was called regarding plan for re-starting aspirin. He was informed that Dr. [REDACTED] recommended desensitization to aspirin. The clinical coordinator would contact the patient to schedule a specialty test for him at the end of 09/2016 or 10/2016. The patient also inquired about obtaining Nucala at the same visit as his aspirin desensitization and was informed that Dr. [REDACTED] would need to be consulted to determine whether it was fine to proceed with both on the same day.

Progress Note - [REDACTED], M.D. - [REDACTED] Pages 595-597. The patient was here for follow-up of labs and sputum productivity. He has had recent sinus surgery, ear tubes, and he has a long history of chronic asthma with some lung damage. He recently had a sputum culture which showed H. flu in nearly pure culture. He was referred back by the ENT specialist for treatment. He has had some chronic otorrhea and had been on Ciprodex. This had worked very well, but he was out and did not have his appointment with Dr. [REDACTED] until tomorrow. His oxygen saturation was 97%.  
Assessment/Plan: 1. Pneumonia due to Haemophilus influenzae. He was clinically not significantly ill.

He had a chest x-ray ordered which he would do at this time. Amoxicillin was also prescribed. 2. Chronic tubotympanic suppurative otitis media of both ears. Ciprodex was ordered. He needs a refill pending his appointment with Dr. [REDACTED].

X-rays of the Chest - [REDACTED], M.D. - [REDACTED] Pages 2362-2363. Impression: Increased interstitial markings in the right upper lung, more prominent from prior might be secondary to underlying infectious/inflammatory process.

Progress Note - [REDACTED], M.D. - [REDACTED] Page 597. The patient had completed Bactrim orally. His ears felt open and his sinuses were without so much pressure. His sense of smell decreased compared to best post-op day and drainage decreased. He has a long-standing chronic cough and he was being treated for Haemophilus influenzae on culture.

Progress Note - [REDACTED], M.D. - [REDACTED] Pages 1833-1840. The patient returned for a Nucala injection. His dose was 100mg every 4 weeks. He stated that his injections were going well. He stated that his asthma was not currently controlled.

Progress Note - [REDACTED], M.D. - [REDACTED] Pages 1844-1846. On [REDACTED], the patient was prescribed Singulair to start prior to his aspirin desensitization which was originally scheduled for [REDACTED]. At this time, he was called to see if he could move his aspirin desensitization to [REDACTED], which he agreed to do. He also confirmed that he started Singulair and was currently taking it.

Progress Note - [REDACTED], M.D. - [REDACTED] Pages 1847-1852. The patient returned for an aspirin desensitization. He had started Singulair and continued to be on Advair, Alvesco, Qnasl, and Xopenex. He indicated that he felt good at this time and was ready to move forward with desensitization. Spirometry was performed for baseline lung functions prior to starting aspirin desensitization. His oxygen saturation was initially 98% and remained in that level even after receiving the four doses for aspirin desensitization. He also did not show any clinical evidence of reaction. He was released afterwards, passing today's desensitization and was given a prescription for albuterol. Dr. [REDACTED] dictated a medical letter for the patient to be off work while he continued to be treated.

Spirometry Report - [REDACTED] - [REDACTED] Page 1572. Interpretation: Moderate airway obstruction with low vital capacity.

Medical Report - [REDACTED], M.D. - [REDACTED] Page 1018. The patient had been in the care of Dr. [REDACTED] for his severe persistent asthma with frequent symptoms and high health care utilization. The patient was undergoing active therapy to treat his asthma, sinusitis, nasal polyps and other health-related conditions. At present time, he should be off standard work due to his impaired respiratory function.

Progress Note - [REDACTED], M.D. - [REDACTED] Pages 598-599. The patient was seen for a follow of his pneumonia. He had H. influenza pneumonia and was treated with antibiotics that was sensitive to it. He had responded well to it, but he might not be completely resolved. He also had severe persistent asthma which was exacerbated by his pneumonia. His oxygen saturation was 93%. The plan was to prescribe Amoxicillin and albuterol. A respiratory culture with smear was also requested.

Laboratory Report - [REDACTED] - [REDACTED] Pages 691-692. A respiratory culture with smear from expectorated sputum revealed Stenotrophomonas maltophilia.

Qualified Medical Evaluation Report - [REDACTED], M.D. - [REDACTED] Pages 254-276. The patient had been employed as a [REDACTED] by the County of YYYYYY [REDACTED]. He began working there in 12/1987 and was still employed, but was now off on sick leave. He had asthma before his employment, but it had worsened over the past 6 to 8 years. He also had undergone evaluation of coronary disease with stress test. He had never undergone placement of a coronary stent. In 03/2016, he saw his pulmonary doctor and was told that he had scarred lungs. He was currently on inhalers and breathing better. He had been treated with amoxicillin for the past 3 weeks. He was hospitalized for asthma exacerbation 10 years ago. He had been on prednisone 15 to 20 times over the past several years. He also had nasal polypectomy several times. He stated that he began to develop asthma at age 20. He stated that he smoked cigars sporadically. He also smoked marijuana before he was hired in the [REDACTED] Office. Review of systems was pertinent for dyspnea with minimal exertion and paroxysmal nocturnal dyspnea. He had previous claims for his low back and his left hip. He also had claims for five separate car accidents in which three had airbag deployment. Moreover, he had claims for hearing loss and for difficulty with his sense of smell. On examination, his respiratory rate was 12. According to his medical records, he was diagnosed with asthma around 1986 and he had been taking asthma medication since then. Impression: 1. Severe asthma with numerous exacerbations over the years. This was a preexisting condition that he had at age 20 before he joined the [REDACTED] Department. He had nonetheless had recurrent and multiple exacerbations over the past 15 years with the first report of having asthma being in 05/2001 and beginning to require medical attention in 05/2002. 2. Hypertension, maintained on valsartan. 3. History of multiple sinus surgeries for removal of polyps. 4. Gastroesophageal reflux disease. 5. Chronic neck, back, and hip pain. 6. Sleep disorder, possibly a derivative industrial injury. 7. Hearing loss, reported. 8. Sexual dysfunction, possibly a derivative industrial injury. 9. Depression, possibly a derivative industrial injury. He has had recurrent and worsening episodes of asthma, chronic sinusitis, and nasal polyps necessitating sinus surgery, and reported worsening lung function test. In addition, he had multiple orthopedic injuries related to industrial causes. He also had hypertension which was likely nonindustrial, and sleep disorder, sexual dysfunction, and gastroesophageal reflux disease which were possibly derivative industrial injuries. He had not yet reached MMI status, so causation, impairment, and apportionment were deferred. His orthopedic injuries would be addressed by an orthopedic QME, while his depression would be addressed by a psychiatric QME. Although he had not yet reached MMI, his asthma, which predated his employment, had likely been worsened by his employment with reported exposure to cigarette smoke at the jail center, chemicals at methamphetamine labs that he has had to encounter in the course of his employment, patients with lung disease and reportedly TB, as well as nuclear waste at [REDACTED]. While there would certainly be apportionment to nonindustrial causes because of his pre-existing condition as well as occasional sporadic smoking of cigars, there appeared to be a significant industrial component. In order to better assess impairment, he would need to have more recent pulmonary function tests, and if there were none recent, then he needed to undergo repeat pulmonary function testing. Dr. [REDACTED] would defer impairment of his sleep disorder, sexual dysfunction, and gastroesophageal reflux disease in a supplemental report.

Progress Note - [REDACTED], M.D. - 11/01/16 Pages 1865-1869. The patient returned for his Nucala injection. He indicated that his injections were going well with no complications or reactions; however, he had severe persistent asthma with acute exacerbation. He stated that his asthma was not currently controlled and never was, for that matter. His current medications were Advair, Alvesco, Qnasl, and Xopenex HFA.

Progress Note - [REDACTED], M.D. - [REDACTED] Pages 604-605. The patient noted that he felt well in general. His ears were open, but his sense of smell was poor and his lungs were still not cleared. He was concerned about his persistent pneumonia/chronic bronchitis. Assessment/Plan: 1. Chronic cough. Dr. [REDACTED] might not be able to get a clear culture with the chronic lung disease. A respiratory culture with smear would be done in the future. 2. Nasal polyps would be rechecked in 4 weeks. In the meantime, he was to continue his anti-allergy therapy. Azithromycin was prescribed. 3. Minimal otorrhea. He needed steroid irrigation for the early poly recurrence noted on endoscopy at this time. Budesone was therefore indicated. 4. Chronic sinusitis.

Progress Note - [REDACTED], M.D. - [REDACTED] Pages 1878-1881. The patient was back for his Nucala injection. He stated that the Nucala injections were going well without any complications. He was also kept on his current medications.

Progress Note - [REDACTED], M.D. - [REDACTED] Pages 1882-1888. Xopenex HFA inhaler was refilled.

Progress Note - [REDACTED], M.D. - [REDACTED] Pages 1889-1893. The patient was seen to receive his Nucala injection. He stated that these injections were going well without any complications. There had been no changes to his current medication regimen as well.

Laboratory Report - [REDACTED] - [REDACTED] Page 692. A respiratory culture with smear from expectorated sputum revealed Haemophilus influenzae.

Medical Report - [REDACTED], M.D. - [REDACTED] Page 1075. The patient was recommended to remain off work.

Progress Note - [REDACTED], M.D. - [REDACTED] Pages 1907-1911. The patient came back for his Nucala injection. He was doing well on it and has not had any reactions from it. He noted he was having less chest tightness and not coughing up as much mucus from his lungs. He was ordered to continue his current medication regimen including Advair, Alvesco, Qnasl, Xopenex, Zyflo, and Spiriva.

Progress Note - [REDACTED], M.D. - [REDACTED] Pages 2336-2338. The patient's chronic cough was better on the antibiotic. His left ear was full and a small amount of drainage was suctioned. Retained PE tube was noted. He had mild polypoid degeneration of the roof of the nasal vault. Mild exudate was noted. Head positioning was emphasized with irrigation. This might improve some of the polypoid degeneration.

Progress Note - [REDACTED], M.D. - [REDACTED] Pages 1916-1921. The patient returned for his Nucala injection. He reported he had been having a productive cough with sputum, chest tightness, and shortness of breath for the past 2 weeks. He also mentioned that since he started Nucala, he had not been taking prednisone as often. The plan was to keep him on his current medication regimen except now Levaquin was added.

Medical Report - [REDACTED], M.D. - [REDACTED] Pages 2357-2361. The patient was on disability due to his asthma and smoke exposure from secondhand smoking. He has had a long history of asthma that had generally been controlled on his current regimen of inhalers which included Advair, albuterol nebulized solution, Alvesco, budesonide, Spiriva and Zyflo. He was able to exercise with his current regimen of medication in the past year; however, he had recurrent episodes of acute bronchitis with the most recent one with cultures positive for Haemophilus. He stated that when he was on antibiotics, his

symptoms improved and then quickly re-exacerbated. Currently, he continued to be productive of sputum. A recent chest x-ray did not reveal a pulmonary infiltrate. At this time, his respiratory rate was 16 and his oxygen saturation was 96% on room air at rest. Assessment/Plan: 1. Asthma. 2. Chronic bronchitis. He had persistent asthma on maximal controller agents. Despite this, he was continuing to function. He had chronic sputum production with press cultures positive from Haemophilus influenzae. He was recommended to commit to a prolonged course of antibiotics that could break the cycle of recurrent infections. He would be placed on azithromycin for the next 30 days. Dr. [REDACTED] would not make any changes to the patient's current asthma management.

Progress Note - [REDACTED], M.D. - [REDACTED] Pages 1930-1936. The patient continued to have a cough with sputum, chest tightness, and shortness of breath. He noticed since starting Nucala he had not been prescribed a course of prednisone in a year; however, he did experience mild headaches after receiving his injection. His Advair was also causing white patchy splotches on his tongue. He was working out at a gym 5 days a week and lost 13 pounds since 01/2017. He would use his albuterol inhaler prior to working out. He wanted to receive his Nucala injection at this time which was accommodated. The patient was recommended to continue his daily exercise regimen and was provided a letter for his employer with extended leave of absence. He was to continue his Nucala every 4 weeks as it had been beneficial. He was also to continue his Advair, Alvesco, Spiriva, Zyflo, Qnasl, azithromycin, and Xopenex. Furthermore, the patient had brought the disability retirement paperwork, so Dr. [REDACTED] could review them.

Medical Report - [REDACTED], M.D. - [REDACTED] Page 1113. The patient was recommended to remain off work due to his persistent respiratory symptoms and improvement while on aggressive medical therapy and away from the work environment.

Spirometry Report - [REDACTED] - [REDACTED] Page 1573. Interpretation: Mild airway obstruction.

Medical Report - [REDACTED], M.D. - [REDACTED] Pages 2354-2356. The patient was here for evaluation of his severe persistent asthma. On his last visit, he was placed on a month of azithromycin. Overall, he was much improved although he still had persistent wheezing despite maximal therapy. He was, however, exercising now and able to function better than he had prior to his evaluation. His respiratory rate was 16 and his oxygen saturation was 97% on room air at rest. He had severe persistent asthma. Even after a month of azithromycin, he still had an end-expiratory wheeze bilaterally. He remained on Alvesco, Advair, Spiriva, and Xopenex. The key would be after azithromycin was discontinued the CPAP exacerbates. Dr. [REDACTED] told the patient to contact him if this should happen.

Progress Note - [REDACTED], M.D. - [REDACTED] Pages 1959-1961. Alvesco was refilled.

Progress Note - [REDACTED], M.D. - [REDACTED] Pages 1962-1966. The patient presented for his Nucala injection. He was coming in every 4 weeks for injections and received 100 mg each time. He reported that his injections were going well and reported no complications.

Progress Note - [REDACTED], M.D. - [REDACTED] Pages 1980-1982. Zyflo CR was refilled.

Agreed Medical Evaluation Report - [REDACTED], D.D.S. - [REDACTED] Pages 290-380. In 04/1998, the patient developed chest pain. It hurt to take a deep breath and it was getting worse. He was recommended icing and Naprosyn. Later on, he developed sinusitis and otorrhea for which he was

given antibiotics. Next he developed asthma. He had cough, wheeze and difficulty breathing. He was treated with prednisone. He eventually developed obstructive pulmonary disease and experienced continued chest pain. He continued with chronic sinusitis and was scheduled for surgery. On [REDACTED], a bilateral myringotomy was performed. On [REDACTED], the patient visited Dr. [REDACTED], his dentist. The doctor performed some dental treatment. He worked on tooth #30 and placed a crown together with composite fillings on teeth 3, 15, a crown on #19 on [REDACTED]. On [REDACTED], Dr. [REDACTED] cemented a crown on tooth #13. On [REDACTED], Dr. [REDACTED] performed a composite filling on #20, and #28 as well as a crown on tooth #5. He also provided a root canal on tooth #14. On [REDACTED], the patient decided to get out of work because he was having several medical problems in relation to his job, particularly his asthma problem. The situation was very stressful at work since he was performing the work of two people. He testified in his deposition that he would grind his teeth due to the stress he had. He visited 2 dentists for his bruxism. Dr. [REDACTED] recommended a mouthpiece for teeth grinding. The patient thought the splint was working. At present, he complained of jaw pain, popping noises, and headaches. Impression: 1. Synovitis of the temporomandibular joints. 2. Masticatory myalgia. 3. Localized osteoarthritis of the temporomandibular joints. 4. Fracture of teeth. There was no temporary total disability from the TMJ injuries. The patient was P&S as of this time. His bruxism-related TMJ problem was chronic and not likely to change in the near future. He has obtained MMI status. However, his constant clenching and grinding habit had caused damage to several of his teeth and a provision for treatment needed to be established to repair those teeth. From a dental perspective, there would be no work restrictions when he returned to work. Regarding causation, it was concluded that the TMJ pathology was directly related to the overloading of the TM joints by his constant teeth grinding in relationship to the stressful job he had performed during 29 years. Dr. [REDACTED] apportioned 100% to the industrial cumulative trauma. The patient was found to have a 10% WPI due to the injuries of his temporomandibular joints and masticatory muscles. This rating would include the headaches that were considered related to the clenching habit. Future medical care was required and would include an occlusal oral appliance and porcelain crowns. Regarding his TMJ and dental problems, there was no impediment for him to return to work.

Progress Note - [REDACTED], M.D. - [REDACTED] Pages 630-631. The patient had some shortness of breath with exhaling. He had a somewhat stable symptom. His cough had resolved considerably. He completed 1 month of Zithromax. He was taking the Nucala and all other medications. Dr. [REDACTED] agreed with the current medical management including the Nucala. The paranasal sinus polyposis was under control. The patient has not had prednisone in a year. He seemed to be doing better not working.

Claim for Disability Insurance Benefits - Physician/Practitioner's Certificate (Incomplete Copy) - [REDACTED], M.D. - [REDACTED] Pages 1334, 1522, 1394. The patient had been under the care of Dr. [REDACTED] from [REDACTED] to [REDACTED] regarding his chronic severe persistent asthma, sinusitis, nasal polyps, chronic serous otitis media, adverse reaction to drug, and recurrent respiratory infection. Regarding treatment, he had received monthly appointments, lung function tests, topical and inhaled medications, biologic injections, antibiotics, and x-rays. He had been incapable of performing his regular work on [REDACTED]. He was anticipated to be released to his regular or customary work on [REDACTED]. His disabling condition caused and/or was aggravated by his regular or customary work.

Progress Note - [REDACTED], M.D. - [REDACTED] Pages 1990-1995. The patient had a follow-up of his ongoing chest tightness, which had improved. His wheezing, cough and shortness of breath had improved somewhat. Nucala was going well although it did cause him to have headaches and fatigue. Overall, he felt like he was much better than 1 year ago. He has not needed prednisone or been seen in the Urgent Care in over 1 year. He has not needed antibiotics in the past 1-2 month. His SDI forms

were completed from [REDACTED] to [REDACTED]. His ACT score was 20 which indicated that he had a completely controlled asthma. He had made so much progress in the past year. He has not had to go to ER this past year. Nucala, limiting exposures to viruses, working out, and limiting stress could all help, but it was hard to say where he would be in the future. Dr. [REDACTED] planned to keep the patient on Nucala for as long as he could since it was working. The patient would be kept on the same sinus, asthma and allergy regimen. His exercise would also be continued. Moreover, he would be kept on the same aspirin dose. His medications would not be decreased at this time. He was moving toward better health with the medications and frequency that he was on now.

Medical Report - [REDACTED], M.D. - [REDACTED] Pages 2350-2353. The patient was seen following his initial visit for persistent asthma. He responded to his initial management and was back to his baseline. He still had periods of time when he wheezes, but overall, he was in much better control. His respiratory rate was 16 and his oxygen saturation was 98% on room air at rest. Dr. [REDACTED] would order a standby prescription of prednisone and azithromycin. Dr. [REDACTED] would make no changes in the current medications otherwise.

Laboratory Report - [REDACTED] - [REDACTED] Pages 693-694. A respiratory culture with smear revealed *S. aureus*. *S. aureus* was noted to be resistant to clindamycin, erythromycin, and tetracycline.

Medical Report - [REDACTED], M.D. - [REDACTED] Page 107. Due to the patient's persistent respiratory symptoms and improvement while on intense medical therapy while away from his work environment, Dr. [REDACTED] suggested that the patient remain off work through [REDACTED].

Medical Report - [REDACTED], M.D. - [REDACTED] Pages 769-774. The patient was examined with regard to his ears and hearing. He reported that his hearing had been impaired over the past 4 to 5 years. He also complained of an annoying ringing in both ears. Most of the time, he was able to block it out. He watched a television too loud. On occasion, he did not hear people when they spoke to him, particularly when they were behind him. His ear history was complicated by a history of serous otitis media. He had seen Dr. [REDACTED] for chronic mucoid otitis. About 3 years ago, ventilation tubes were placed in both ears to drain the infected fluid. The right ear drained, but the left ear was dry. His audiogram done at this time demonstrated a significant mid and high-frequency neurosensory hearing loss. There was a very small conductive component in the right ear. Diagnoses: 1. Neurosensory hearing loss – bilateral and symmetric moderate to severe in the higher frequencies. This condition was clearly work related and due to nearly 30 years of noise exposure from firearms, sirens, and other emergency alarms. 2. Serous otitis media. This was treated with ventilation tubes. Dr. [REDACTED] encouraged the patient to continue seeing Dr. [REDACTED] to have his ears examined and cleaned on every-3-months schedule. In addition, the CT scan of the temporal bone revealed polypoid changes in the ethmoids. The patient has had sinus surgery in the past for polyps and the current scan indicated that the sinus polyps had regrown. Possibly, another sinus operation would be helpful, but Dr. [REDACTED] would leave this decision to the patient and Dr. [REDACTED]. This component of his ear condition was not work related, but the effect on his hearing was currently negligible. He was P&S from the standpoint of the neurosensory hearing loss. The only treatment was the use of binaural hearing aids, which he would postpone at this time. Regarding causation, it was determined that the neurosensory hearing loss was secondary to excessive noise exposure. The chronic serous otitis media and nasal polyps were unrelated to a work condition and should be dealt with his own insurance and follow-up with Dr. [REDACTED].



CT Scan of the Temporal Bone - [REDACTED], M.D. - [REDACTED] Pages 1175-1176. Impression: Low-grade otomastoid effusion partially effecting the air cell system.

Progress Note - [REDACTED], M.D. - [REDACTED] Pages 2028-2033. [REDACTED] Infusion Center was called to reorder Nucala. Dr. [REDACTED] would use sample of Nucala for the patient at this time.

Medical Report - [REDACTED], M.D. - [REDACTED] Pages 2347-2349. The patient presented for evaluation of his persistent asthma. He remained on maximal therapy with combined multidrug inhaled treatment. He was not taking prednisone, but he still had persistent wheezing and a persistent productive cough. He was able to exercise a bit, but was still limited by his wheezing. His respiratory rate was 16 and his oxygen saturation was 96% on room air at rest. With his sputum production, a month-long course of azithromycin combined with samples of Daliresp would be initiated. Sputum culture was ordered as well.

Medical Report - [REDACTED], M.D. - [REDACTED] Pages 760-761. The patient complained of hearing loss and tinnitus. Dr. [REDACTED]'s initial evaluation revealed that the patient had a significant hearing loss in the mid and high-frequencies. At that time, the patient was not interested in pursuing a hearing aid trial. One week after this visit, he called and stated that he changed his mind and now wanted a referral for a trial of hearing aids. Since his hearing loss was substantially work related, the trial of hearing aid should be paid for under the Workers' Compensation system. He was permanent and stationary at this time. According to CA Workers' Compensation guideline, the high frequency hearing loss resulted in a 0% WPI. In view of the concomitant issue of serous otitis media, Dr. [REDACTED] would apportion the patient's hearing loss as 80% work related as a sheriff and 20% secondary to intermittent serous otitis treated by Dr. [REDACTED].

Laboratory Report - [REDACTED] - [REDACTED] Pages 694-695. A respiratory culture with smear from sputum revealed Pseudomonas fluorescens. P. fluorescens was noted to be intermediately susceptible to cefepime and imipenem.

Medical Report - [REDACTED], M.D. - [REDACTED] Pages 2344-2347. The patient presented for his chronic persistent asthma. Since his last visit, he had decided not to take the prednisone or the antibiotic. He had been maintaining himself with his chronic inhalers and in fact has had an interval improvement over the past month with decreased cough and sputum production. His sputum cultures grew out Pseudomonas fluorescence. His respiratory rate was 18 and his oxygen saturation was 97% on room air at rest. As his acute bronchitic symptoms had resolved, Dr. [REDACTED] would not make any changes in his current medications. The patient was advised that should he develop acute bronchitis, that he would start a short course of prednisone combined with antibiotics as needed.

Progress Note - [REDACTED], M.D. - [REDACTED] Pages 2037-2046. The patient returned for a follow-up on Nucala and asthma. He was last seen on [REDACTED] for his Nucala injection. He had been on Nucala for about a year and noted seeing an improvement in his asthma. His asthma had been better than before. Lately, he had been having some asthma flare-ups when doing activities, exercising, or picking up heavy items. In the last couple weeks, he had been using his rescue inhaler. Prior to exercising, he also used his inhaler. At this time, his ACT score was 19. He was seeing a pulmonologist and had a sputum test. He was put on an antibiotics, but had not taken them. The patient would be seeing Dr. [REDACTED] for his hearing aids. He would continue his Nucala and medication regimen.

Spirometry Report - [REDACTED] - [REDACTED] Page 1532. Interpretation: Normal spirometry.

Progress Note - [REDACTED], M.D. - [REDACTED] Page 637. The patient was seen to follow up his Samter's triad. He felt better overall and better rested. His sense of smell was improving. He did not take recent Zithromax and prednisone. He felt better off work with less stress and environmental exposures. Assessment: Chronic sinusitis with Samter's triad. He was improving in clinical outcome. There was no change in his regimen.

Progress Note - [REDACTED], M.D. - [REDACTED] Pages 2053-2058. Alvesco, Qnasl, Spiriva, and Xopenex HFA were dispensed.

Progress Note - [REDACTED], M.D. - [REDACTED] Pages 2059-2061. The patient indicated that he had decided to retire in 10/2017 and was requesting a medical retirement based on his work-related lung disease and hearing loss. He wanted to know if Dr. [REDACTED] would be able to complete the doctor's portion of the Application for Disability Retirement. The patient's current assignment was a [REDACTED], central division, in which he had to wear the full uniform and safety gear, drive marked patrol vehicle, and handle calls for service.

Progress Note - [REDACTED], M.D. - [REDACTED] Pages 2062-2065. The patient was given Nucala injection without any reactions. Since being on Nucala therapy, he had significant improvement with breathing and a reduction in the frequency of exacerbations, prednisone bursts, ER visits, and hospitalizations related to asthma. He was using a rescue bronchodilator inhaler. His ACT score was 17. At this time, no adjustments were made to his current medication regimen which included EpiPen #2, Advair, Alvesco, Spiriva, Xopenex, and Qnasl.

Progress Note - [REDACTED], M.D. - [REDACTED] Pages 2066-2068. Qnasl was dispensed.

Medical Evaluation of Functional Limitation/Capacity - [REDACTED], M.D. - [REDACTED] Pages 74-75, 1322. The patient required regular and inhaled therapy for his asthma and also a rescue inhaler when he had increased symptoms. When he had an infection, exposure to airway irritants, severe stress, or moderate exertion; he was quite prone to coughing, shortness of breath, wheezing, chest tightness, and other symptoms such as agitation and confusion. He needed regular access to all of his medications. He was currently assigned as a patrol deputy in South YYYYYY working in full sheriff's uniform and marked patrol vehicle. He reported that his duties were both physically and emotionally demanding. Based on his lung disease only and not taking account his reported work-related hip, back, and hearing issues, he should be precluded from doing activities that exacerbated or triggered his asthma with regards to his law enforcement duties, including sustained physical confrontations with combative subjects, running with safety gear, ascending upwards quickly; pushing, pulling, lifting, carrying moderate to heavy objects for a sustained amount of time, and prolonged exposures to stress, anxiety, air pollutants, chemical irritants, fungi bacteria and viruses.

Medical Report - [REDACTED], M.D. - [REDACTED] Pages 1182-1184. The patient suffered from severe persistent eosinophilia, asthma and chronic hyperplastic eosinophilia rhinosinusitis. He had suffered with progressive symptoms over the last 20+ years. He had progression of his respiratory disability well established in the medical records which pre-dated Dr. [REDACTED]'s care of him. The patient could not continue to work in his current job based on his known inhalational/respiratory sensitivities and vulnerability. It was recommended that he not be exposed to further infectious, allergic, irritant, or volatile triggers. His permanent disability included his severe respiratory airflow limitation, which was persistent and with frequent exacerbations. He also suffered from shortness of

breath, wheezing, coughing and inability to adequately perform his job duties. Dr. [REDACTED] believed that the patient's disability was for the performance of a substantial portion of the current duties. He was highly sensitive to both inhaled respiratory irritants and allergens, as well as having compromised pulmonary functional capacity which limited his ability to exert himself. He had been continuously physically incapacitated from performing his work duties since 2005 and up to the present time. After reviewing extensive medical records, Dr. [REDACTED] concluded that the patient's job aggravated his condition. The patient sustained substantial inhalational aggravation due to allergens, irritants, fumes and toxic respiratory substances while performing his employment duties. The patient was hired as a [REDACTED] in 12/1987. From 1987 to 1991, he worked at a jail building, where he was exposed to secondhand smoke from inmates, bacteria, molds, dust, and viruses as well as patients with lung disease and reportedly TB. From 1991 to 1999, he worked as a patrol officer, training officer, high impact team and problem-oriented police officer. On [REDACTED], he was exposed to smoke from diesel tanker truck fumes. Moreover, he had very high stress levels trying to handle calls. From 1999 to 2001, he became a narcotics detective and was exposed to chemicals at methamphetamine labs.

Audilogic Report - [REDACTED], Au.D. - [REDACTED] Pages 753-754. The patient was seen for an audiometric evaluation and a hearing aid consultation. He was retiring as a [REDACTED]. He had a noise-induced, high-frequency hearing loss. He reported that he had been suffering from bilateral constant tinnitus for many years. He had to work very hard to ignore the tinnitus. He reported that it was more difficult to ignore in the evening when he was trying to fall asleep or awakened in the middle of the night. He often had difficulty understanding conversation. He had difficulty hearing the television at the volume that his family found comfortable. He had difficulty with clarity of speech on the telephone; thus, Dr. [REDACTED] was recommending the patient be fitted with hearing aids. The hearing aids alone should reduce his perception of the tinnitus. The hearing aids would provide audibility which would increase his understanding of conversation and result in an improvement in communication.

Progress Note - [REDACTED], M.D. - [REDACTED] Pages 2069-2071. Albuterol sulfate was prescribed.

Progress Note - [REDACTED], M.D. - [REDACTED] Pages 2075-2077. The patient received Nucala injection without any reactions, for his severe persistent asthma. At this time, no adjustments were made to his current medication regimen which included EpiPen #2.

Medical Report - [REDACTED], M.D. - [REDACTED] Pages 70-73. After reviewing extensive medical records, Dr. [REDACTED] still concluded that the patient's job aggravated his condition. The patient sustained substantial inhalational aggravation due to allergens, irritants, fumes and toxic respiratory substances while performing his employment duties. From 2001 to 2016, the patient was assigned to [REDACTED] and [REDACTED] Division. The main courthouse had a large holding cell for inmates awaiting trial. The cell had an open toilet and sink. He was exposed to airborne pathogens especially by those taken into custody directly from the court and had not been medically screened. In 2002, he was exposed to nuclear waste at [REDACTED] without protective gear or warning. From 2008 to 2016, he had been exposed to mold in the office and assigned vehicles as well as lead dust and irritants.

Medical Report - [REDACTED], M.D. - [REDACTED] Page 76. Dr. [REDACTED] still believed that the patient required regular and inhaled therapy for his asthma and also a rescue inhaler when he had increased symptoms. When he had an infection, exposure to airway irritants, severe stress, or moderate

exertion, he was quite prone to coughing, shortness of breath, wheezing, chest tightness, and other symptoms such as agitation and confusion. He needed regular access to all of his medications. He was currently assigned as a patrol deputy in South YYYYYY working in full Sheriff's uniform and marked patrol vehicle. He reported that his duties were both physically and emotionally demanding. Based on his lung disease only and not taking into account his reported work-related hip, back, and hearing issues, he should be precluded from doing activities that exacerbate or trigger his asthma with regards to his law enforcement duties including sustained physical confrontations with combative subjects, running with safety gear, ascending upwards quickly; pushing, pulling, lifting, carrying moderate to heavy objects for a sustained amount of time, and prolonged exposures to stress, anxiety, air pollutants, chemical irritants, fungi bacteria and viruses.

Progress Note - [REDACTED], M.D. - [REDACTED] Pages 640-642. The patient was doing well over all. He would like the Qnasl because when he goes off of that and tries the other sprays, he would get more congested. He would like to avoid repetitive sinus surgery. His ears were having less drainage. He would like a new hearing aid. Assessment/Plan: 1. Chronic allergic rhinitis. He had extreme respiratory issues and the delivery method of the Qnasl would have better delivery and adherence; thus, this was prescribed. 2. Chronic tubotympanic suppurative otitis media of both ears. He might have difficulty with amplification secondary to moisture. If the patient did wear the hearing aids, Dr. [REDACTED] would opt to not place further PE tubes unless acute infections were present. 3. Other polyp of sinus. The patient was advised to continue with nasal steroid to decrease recurrence and Nucala. 4. Samter's triad. 5. Uncomplicated severe persistent asthma. He was ordered to stay on prescribed inhalers. Dr. [REDACTED] would verify if the patient was still on Nucala injections.

Medical Report - [REDACTED], M.D. - [REDACTED] Pages 2341-2344. The patient was here in follow-up for his asthma/COPD. Overall, he had been doing fine. He was still having problems. He would get congested and short of breath with activity. He was using his multiple long-acting inhalers in combination with his nebulizer on a when-necessary basis, and his albuterol inhaler. He had noted increase in sputum production especially in the past couple weeks. He had problems during the summertime when they had problems with the wildfires. His respiratory rate was 16 and his oxygen saturation was 98.4%. Assessment/Plan: 1. Overweight. He was provided care instructions handout. 2. Asthma. Other than increased cough and sputum production, his asthma appeared to be fairly well controlled. In order to simplify his multiple inhalers, Dr. [REDACTED] would change all the long-acting inhalers to Trelegy Ellipta. Dr. [REDACTED] would prescribe a standby prescription for a Z-Pak.

Progress Note - [REDACTED], M.D. - [REDACTED] Pages 2093-2097. The patient returned for an asthma follow-up and Nucala injection. He complained of his chest congestion. His status was fluctuating based on his activity level. The more he exerted himself, the more symptoms he experienced. His ACT score was 18. He was advised to continue with all routine medications including Trelegy, Zflo, Qnasl, and budesonide. Xopenex should be used as needed. While Dr. [REDACTED] was waiting on approval for Qnasl, a sample was provided to the patient at this time. The patient was advised to fill his Zithromax prescription as he continued to have a productive cough, status post URI.

Medical Reports - [REDACTED], Au.D. - [REDACTED] Pages 751-752. The patient reported that he was now able to hear and understand better with aids. His own voice was audible. The tinnitus was less when he was wearing it, but he was always aware of the tinnitus. He felt that he was able to ignore it without the aids. He was wearing his hearing aids daily. He was able to clean and take care of the devices.

Progress Note - [REDACTED], M.D. - [REDACTED] Pages 2102-2104. The patient received Nucala injection, without any reactions, for his severe persistent asthma. He stated that he had not been doing too well the past month and was on Zithromax due to having respiratory infection. At this time, no adjustments were made to his current medication regimen.

Progress Note - [REDACTED], M.D. - [REDACTED] Pages 2111-2113. The patient was seen for administration of Nucala injection for his severe persistent asthma. He tolerated the injection without any reactions and no adjustments were made to his current medication regimen.

Progress Note - [REDACTED], M.D. - [REDACTED] Pages 2120-2122. The patient presented for his Nucala injection which he tolerated without any reactions and no adjustments were made to his current medication regimen.

Medical Report - [REDACTED], M.D. - [REDACTED] Pages 2339-2340. The patient was here in follow-up for his asthma. Since starting Trelegy Ellipta, his asthma control had been extremely improved. He had used prednisone twice so far this year; but overall, he had excellent control of his asthma. His respiratory rate was 16 and his oxygen saturation was 97% on room air at rest. The patient was doing well on Trelegy for his asthma, so Dr. [REDACTED] would not make any changes in his current medications.

Medical Reports - [REDACTED], Au.D. - [REDACTED] Page 751. The patient noted he was able to hear and understand conversation better with his hearing aids. The left ear was itchy and he felt the hearing aid on this side could be fitted better. With the use of his hearing aids, he was aware of an improvement in his understanding of conversation. He reported that his tinnitus was unchanged. When he was not concentrating on the tinnitus, he was able to ignore it. Dr. [REDACTED] made small changes increase the audibility of speech.

Progress Note - [REDACTED], M.D. - [REDACTED] Pages 2129-2137. The patient's condition had improved. He had less chest tightness and congestion. His asthma would usually flare up with stress or exercising. He used Ventolin prior to any physical activity. For the thrush in his throat, Dr. [REDACTED] prescribed fluconazole. The patient had excellent response to Trelegy and Nucala, while Ventolin HFA was a fair response. His ACT score was 19. Nucala was administered at this time without any reactions. He was advised to continue his Nucala injection and with all routine medications. EpiPen 2-Pak was dispensed.

Spirometry Report - [REDACTED] - [REDACTED] Page 1381. Interpretation: Mild restriction.

Progress Note - [REDACTED], M.D. - [REDACTED] Page 660. The patient had improved with regard to his sense of smell. His lungs were better and his sinuses were not draining. He had not been using the budesonide irrigation. He also had some blood on mucous. The patient's Samter's triad was doing better than Dr. [REDACTED] had seen in years. The combination of Nucala, consistent use of therapies and lack of work exposures had been very therapeutic.

Progress Note - [REDACTED], M.D. - [REDACTED] Pages 2153-2155. The patient was given a Nucala injection without any reactions. No adjustments were also made to his current medication regimen.

Medical Reports - [REDACTED], Au.D. - [REDACTED] Page 751. The patient complained that his hearing aids were clogged with wax, so Dr. [REDACTED] showed the patient how to remove it.

Progress Note - [REDACTED], R.N. - [REDACTED] Pages 2159-2161. Zflo CR was prescribed.

Progress Note - [REDACTED], R.N. - [REDACTED] Pages 2162-2164. Zflo CR was refilled.

Progress Note - [REDACTED], M.D. - [REDACTED] Pages 2171-2173. The patient returned for his Nucala injection. No adjustments were made to his current medication regimen.

Progress Note - [REDACTED], M.D. - [REDACTED] Pages 2195-2202. The patient felt his asthma symptoms were continuing to improve. He was using his rescue inhaler; however, it was not nearly as bad prior to beginning Nucala injections. He could exercise for longer periods of time without his asthma flaring up. Two months ago, he cut back his Zileuton and had not noticed an increase in symptoms. He denied any issues with his Nucala injection site; however, he reported that he did experience some fatigue. Around 1 week after his last Nucala injection, he also developed symptoms of soreness in his knees and ankles and a bump on his left wrist that he was not sure was caused by Nucala or exercise. Spirometry performed at this time showed moderate restriction. His ACT score was also 16; thus, he was given his Nucala injection. He could continue to decrease his Zflo as tolerated. He would also continue Trelegy, Nucala injections, Qnasl and budesonide. He would keep EpiPen on hand to use.

Spirometry Report - [REDACTED] - [REDACTED] Page 1557. Interpretation: Moderate restriction.

Interactive Summary - County of YYYYYY - [REDACTED] Page 96. A doctor's note was submitted to Ms. [REDACTED], Personnel Analyst, on [REDACTED]. Mr. XXXXX had been away from the workplace due to a non-job-related illness since [REDACTED]. His FMLA/CFRA entitlement expired on [REDACTED]. In an email dated [REDACTED], the County's Disability Compliance Program certified Mr. XXXXX as being an individual with a disability and as such he was also a qualified individual eligible for reasonable accommodation. The County was required to engage in an interactive dialogue with the employee to identify a reasonable accommodation. On [REDACTED], Dr. [REDACTED] recommended that Mr. XXXXX be taken off work from [REDACTED] until [REDACTED]. On [REDACTED], his employer had agreed to accommodate the request for time off through [REDACTED].

Medical Report - [REDACTED], Au.D. - [REDACTED] Pages 756-757. The patient was employed by the County of YYYYYY as a [REDACTED] for 30 years. He retired on [REDACTED]. If he continued to work in his current job, he would continue to be exposed to the hazardous levels of noise that caused his hearing loss. The hearing loss would progress with more exposure to noise. He had difficulty determining the direction of sound, which was a safety hazard for him and for others. His speech would not be understood accurately. Because of this, Dr. [REDACTED] did not feel that the patient should continue to work in his current job. The patient's disability was for bilateral noise-induced sensorineural hearing loss and for constant bilateral tinnitus. This was not expected to improve. His disability was for the performance of a substantial portion of his current duties; therefore, he must not be exposed to loud noise, sirens, and airbag deployments. He must also wear his hearing aids to communicate with his coworkers. He had been continuously physically incapacitated from performing his work duties since the [REDACTED] audiometric evaluation. His disability was caused by the job.

Medical Evaluation of Functional Limitation/Capacity - [REDACTED], Au.D. - [REDACTED] Pages 758-759. The patient was precluded from being exposed to high levels of noise that might damage his hearing and his hearing aids must be working in order to hear environmental sounds and communicate.

Audiologic Report - [REDACTED], Au.D. - [REDACTED] Page 755. The patient was seen for an annual Workers' Compensation audiologic evaluation and hearing aid check. He was wearing hearing aids and has a history of occupational noise exposure and bilateral high-frequency sensorineural hearing loss. He reported difficulties communicating in his daily life, specifically with understanding his family. He was counseled on wearing his hearing aids full time and strategies for tinnitus management with hearing aids. Compared to his prior audiogram, his audiologic findings showed a minimal decrease in hearing bilaterally. Aided audiogram at this time showed good aided performance across the frequency range. Hearing aids were checked and cleaned and a new feedback test was run. Real-ear measures were performed and hearing aids were re-programmed to NAL-2 prescription targets. He reported increased clarity in sound quality. Supplies were dispensed. An electric UV dryer was also dispensed to help sanitize and preserve the longevity of his hearing aids. Annual audiologic evaluation, hearing aid evaluation, and bi-annual hearing aid check/clean with electroacoustic analysis were recommended.

I also received records including [REDACTED], M.D., G.P. [REDACTED], M.D., [REDACTED], M.D., [REDACTED], M.D., [REDACTED], M.D., [REDACTED], M.D., [REDACTED], M.D., [REDACTED], M.D., [REDACTED], M.D., [REDACTED], P.A., [REDACTED], M.D., [REDACTED], M.D., [REDACTED], N.P., [REDACTED], D.O., [REDACTED], M.D., [REDACTED], M.D., [REDACTED], M.D., [REDACTED], [REDACTED], L.C.S.W., [REDACTED], M.D., [REDACTED], M.D., [REDACTED], M.D., [REDACTED], [REDACTED], M.D., [REDACTED], P.A., [REDACTED], M.D., [REDACTED], M.D., [REDACTED], M.D., [REDACTED], [REDACTED], M.D., [REDACTED], M.D., [REDACTED], [REDACTED] Physical Therapy & Athletic Performance, and [REDACTED], which pertained to the patient's status post ORIF left hip acetabular fracture, chest pain, dysphagia, chronic pain in the neck, upper back, and lower back, conjunctive hemorrhage of right eye, kidney stones, right toe injury, abdominal pain, decreased appetite, muscle spasm, weakness, benign hypertension, idiopathic peripheral neuropathy, internal hemorrhoids, mild diverticulosis, left hip arthralgia, right foot sprain, bruxism, ventral hernia, flank pain, and chronic folliculitis as well as non-pulmonological diagnostic and laboratory tests. These records covered the period of [REDACTED] through [REDACTED].

Thank you for the opportunity to evaluate Mr. XXXXX XXXXX. Please let me know if you have any questions.

[REDACTED]

Martin Schlüsselberg, MD

May 27, 2020

**Date**

**Martin E Schlusberg, MD.**  
**6869 Indiana Ave**  
**Riverside, CA 92506**

Re: [REDACTED] XXXXXX  
DOB:  
SSN:  
Date of Injury: N/A  
Employer: Yyyyyy County  
Occupation: [REDACTED]  
Date of Examination: [REDACTED]

**DISABILITY INDEPENDENT MEDICAL EVALUATION**

I have been asked to provide an independent medical evaluation on [REDACTED] XXXXXX and provide an opinion as to whether the applicant is permanently incapacitated. The applicant is not alleging that his employment substantially caused or aggravated his incapacity. I have reviewed the attached records and provided a written report. I also note that under retirement law, incapacity means that the applicant is substantially unable to perform his usual duties and reasonable accommodations are not possible.

**IDENTIFICATION:**

Mr. [REDACTED] XXXXXX was employed as a [REDACTED] with Yyyyyy County [REDACTED]. He started working for them on [REDACTED] and last worked on [REDACTED]. He decided to apply for non-service-connected disability retirement on [REDACTED] regarding his pulmonary alveolar proteinosis. He was medically dismissed from his job on [REDACTED].

**ABSTRACT:**

**Is the member currently incapacitated? Yes.**  
**Is the member continuously incapacitated? Yes.**  
**If so, date continuous incapacity commenced? [REDACTED].**  
**Is the member permanently incapacitated? Yes.**  
**If so, is the incapacity service connected? No.**  
**Can the member return to work with treatment? No.**

**RECOMMENDATION:**

Based on my review of the records/documents as well as my examination, I would recommend that a non-service-connected disability retirement be granted.

**PRESENT ILLNESS:**



Mr. Xxxxxx is a [REDACTED]-year-old ex-smoker that smoked approximately one cigarette per day for 26 years (approximately 2-pack years). He stopped smoking in 2017. Prior to his illness, the member was able to walk 2 to 4 miles daily without any difficulty. He did not have any limitation of exertion.

In the summer of 2015, Mr. Xxxxxx noticed that he was becoming short of breath after walking only one-half mile. He also had dizziness with exertion. He denies any palpitations. He saw his primary care doctor and was treated with antihistamines which he took for two years without relief.

The symptoms progress until August 2017. At that time, he went on a vacation to Lake Tahoe and went to Heavenly Valley, which is at an altitude of 10,000 feet. He took a tram to get to his destination. Once he was out in the high altitude, he walked a short distance and then fell to his knees and had brief loss of consciousness which he describes as seconds. He asked for help and was given oxygen and a wheelchair. He felt better after receiving the oxygen therapy. He then went down to sea level by tram without further incident.

Following this incident, he noticed that he had increased dyspnea after only walking 10 to 15 feet at a time. The member went to an Urgent Care center where he had a chest x-ray and was subsequently admitted to [REDACTED] hospital on [REDACTED] with suspicion of pneumonia. Chest x-ray showed diffuse bilateral groundglass and reticular opacities. CT scan of the chest showed extensive bilateral alveolar opacities with moderate focal consolidation in the left lower lobe.

He underwent bronchoscopy and was diagnosed acute hypoxic respiratory failure and pneumonia due to infectious organism.

The member continued to be symptomatic following his admission, complaining of chest tightness and shortness of breath. The member was evaluated by Cardiology and had a negative stress test. The member was also evaluated for polycythemia by a hematologist.

On [REDACTED], he underwent CT of the chest that revealed improving bilateral parenchymal opacities, with residual bilateral crazy paving, resolution of borderline mediastinal lymphadenopathy and crazy paving pattern classically described with alveolar proteinosis.

On [REDACTED], he was again hospitalized for hypoxemia and bilateral pulmonary opacities. He was treated with antibiotics and had another bronchoscopy at that time which was negative for infectious ideologies. Mr. Xxxxxx was on 5 L nasal cannula oxygen at this time. He was diagnosed with acute respiratory failure, interstitial pneumonia and hypoxia.

A decision was made to send Mr. Xxxxxx for open lung biopsy. On [REDACTED], he underwent bronchoscopy with aspiration, right-sided video-assisted thoracoscopy with lung biopsy. Surgical pathology was consistent with pulmonary alveolar proteinosis. His clinical course was complicated by a pneumothorax and respiratory failure requiring ventilator support that lasted 21 days. The wife had agreed to tracheostomy but he was able to be extubated prior to ordering that procedure.

The member was referred to a tertiary care hospital for whole lung lavage. On [REDACTED], Mr. Xxxxxx underwent whole lung lavage on ECMO at UCSF.

On [REDACTED], vocal cord dysfunction was diagnosed. Mr. Xxxxxx developed a raspy voice and had difficulty carrying on conversations for a protracted period of time. He would sometimes have to talk in whispers. This was also noted during his evaluation.

Pulmonary function tests, done [REDACTED], showed mild restrictive lung disease with a significant bronchodilator response and mild diffusion impairment.

On [REDACTED], Mr. Xxxxxx underwent a sleep study which showed moderate obstructive sleep apnea. The member was started on CPAP but could not tolerate it and is currently on supplemental oxygen at night.

On [REDACTED], he presented with fever cough, hoarseness, sinusitis, hyponatremia and progressive left-sided numbness and tingling. Mr. Xxxxxx was admitted and diagnosed with right lower lobe pneumonia and brain abscess due to Nocardia. He was treated with meropenem and Septra.

The member developed right-sided hearing loss with dizziness, paresthesia and fatigue concurrent with this illness.

In April 2019, Mr. Xxxxxx was complaining of vertigo and balance issues.

On [REDACTED], in accordance with section 17.6 of his labor agreement between the Yyyyyy County and Yyyyyy County [REDACTED], he was medically terminated from his employment with the county.

On [REDACTED] and [REDACTED], he underwent additional sequential whole lung lavage.

**PAST HISTORY:**

DIAGNOSIS	DATE	PHYSICIAN OR NP
Pneumonia	[REDACTED]	Dr. [REDACTED]
Acute and Chronic Hypoxemic Respiratory Failure	[REDACTED]	Dr. [REDACTED]
Polycythemia	[REDACTED]	Dr. [REDACTED]
Pulmonary Alveolar Proteinosis	[REDACTED]	Dr. [REDACTED]
Vocal Cord Dysfunction	[REDACTED]	Dr. [REDACTED]
Obstructive Sleep Apnea	[REDACTED]	Dr. [REDACTED]
Nocardia Pneumonia/Brain Abscess	[REDACTED]	Dr. [REDACTED]
R Hearing Loss	[REDACTED]	Dr. [REDACTED]
Diabetes Mellitus Type II	[REDACTED]	Dr. [REDACTED]

Hypertension		
Obesity		
h/o Syncope		

MEDICAL ALLERGIES: Gabapentin

MEDICATIONS:

Janumet/Metformin 50/1000 Q day  
 Atorvastatin 10 mg Q day  
 Amlodipine 10 mg Q day  
 Metoprolol 100 mg Q day  
 Losartan 100 mg Q day  
 Lantus 18 unit subcu Q day

FAMILY HISTORY:

Noncontributory

REVIEW OF SYSTEMS:

Mr. Xxxxxx denies any fever, chills, and headaches. He denies any problem with his eyes nose or throat. He admits to hearing loss in his right here. He admits to hoarseness and difficulty talking for long periods of time. He states that if he speaks for long periods, he has to talk in a whisper. The member has a history of dyspnea and dyspnea on exertion. He's had cough in the past but not presently. He has no history of hemoptysis. He has had sputum production in the past when he has had upper respiratory infections. He has had chest tightness associated with his pulmonary alveolar proteinosis. He denies palpitations. He denies nausea, vomiting, constipation, diarrhea. He has a history of numbness on the left side in association with his brain abscess. The member has a history of syncope that lasted seconds according to history. He also has a history of vertigo and loss of balance in association with his brain abscess.

**PHYSICAL EXAMINATION:**

This examination was done via telemedicine; therefore, the observations were limited to what could be seen over the video feed. During the interview the member was wearing oxygen. He did have some difficulty hearing me at times. The member spoke with a hoarse voice. Later on in the interview the member spoke with a whisper and I was unable to hear him; therefore, the remainder of the interview, had to be done mainly with the wife.

Further observation was that although the member was alert and oriented times three, he had difficulty concentrating during the interview, and his wife had to help him many times when he was unable to remember; for instance, the member was unable to recall the names of his medications. He also had some difficulty remembering the dates of his illness. He also did not have any recollection of his admission for brain abscess until I reminded him during the interview.

Further physical examination was not possible in the setting.

**DIAGNOSTIC IMPRESSION:**

Chronic hypoxic respiratory failure, O2 dependent  
Pulmonary alveolar proteinosis  
Restrictive lung disease  
Right hearing loss due to history of brain abscess  
Vocal cord dysfunction due to prolonged intubation (21 days)  
Hoarseness secondary to vocal cord dysfunction  
Impaired short-term memory due to hypoxia  
Cognitive dysfunction  
Sleep apnea  
Diabetes mellitus type II  
Hypertension  
Hyperlipidemia

**SUMMARY:**

Mr. Xxxxxx' pulmonary problems began approximately in the beginning of 2004 when he experienced difficulty breathing and shortness of breath with exertion. He was an ex-smoker. He smoked 1 pack of cigarettes a month for 26 years. On [REDACTED], he was seen by Nurse Practitioner [REDACTED] due to dry cough. Levalbuterol was prescribed.

On [REDACTED], he presented to Nurse Practitioner [REDACTED] complaining of dry cough and shortness of breath. He was diagnosed with upper respiratory tract infection and cough. Azithromycin and albuterol sulfate HFA were prescribed.

On [REDACTED], Mr. Xxxxxx was hospitalized due to worsening shortness of breath and dry cough and he was diagnosed with pneumonia. He had a chest x-ray which showed diffuse bilateral ground glass and reticular opacities and a CT of the chest which showed extensive bilateral alveolar opacities with moderate focal consolidation in the left lower lobe. He had a pulmonary consult and he underwent bronchoscopy.

On [REDACTED], Mr. Xxxxxx saw Dr. [REDACTED], who discharged him with diagnoses of acute hypoxemic respiratory failure and pneumonia due to infectious organism.

On [REDACTED], he presented to Dr. [REDACTED] complaining of shortness of breath upon exertion, an episode of near syncope and chest tightness. He was diagnosed with dyspnea. A CT of the chest HR, PFT with DLCO and Lexi scan were ordered. On [REDACTED], he underwent a CT of the chest that revealed improving bilateral parenchymal opacities, with residual bilateral crazy paving; resolution of borderline mediastinal lymphadenopathy and crazy paving pattern classically described with alveolar proteinosis.

On [REDACTED], he saw Dr. [REDACTED] for his respiratory failure. Pulmonology follow-up and repeat CT of the chest were recommended.

On [REDACTED], he was seen by Dr. [REDACTED] again for his polycythemia. During this visit, he stated that he quit smoking earlier that year and that he was recently admitted to the hospital for respiratory failure and he was treated empirically with antibiotics for pneumonia. He was on home oxygen. His imaging studies in the hospital had raised concerns about viral pneumonia. A lung biopsy was considered.

On [REDACTED], he presented to Dr. [REDACTED] and was admitted to the hospital due to complaints of hypoxemia and bilateral pulmonary opacities. He was treated with antibiotics and then had a bronchoscopy which was negative for any microbial entities. His oxygen saturation was borderline on 5 L nasal cannula. He was diagnosed with acute respiratory failure, interstitial pneumonia and hypoxia. An open lung biopsy was ordered.

He was seen by Dr. [REDACTED] on [REDACTED] for a thoracic surgery consultation regarding his interstitial lung disease and evaluation for lung biopsy. The following day, [REDACTED], he underwent bronchoscopy with aspiration, right-sided video-assisted thoracoscopy with lung biopsy with Dr. [REDACTED]. His surgical pathology on [REDACTED] was consistent with pulmonary alveolar proteinosis.

On [REDACTED], he had CT of the chest which revealed diffuse ground glass density and interlobular septal thickening with subpleural sparing in both lungs, involving all lobes; interval decrease in previously seen dense consolidation in both lower lungs; and postsurgical changes in the posterior right upper lobe with associated more dense opacity as well as right lower lobe dense oval nodule that measured 8 mm. His chest x-ray dated [REDACTED] showed stable postsurgical appearance of the right lung and background interstitial lung disease consistent with pulmonary alveolar proteinosis. He underwent right lung therapeutic bronchoalveolar lavage on [REDACTED].

On [REDACTED], he underwent selective left lung therapeutic bronchoalveolar lavage with Dr. [REDACTED]. On [REDACTED], Dr. [REDACTED] saw Mr. Xxxxxx for follow-up of his pulmonary alveolar proteinosis with persistent hypoxemia. He was diagnosed with pulmonary alveolar proteinosis, obesity class III, pneumonia due to infectious organism, Acinetobacter, acute on chronic respiratory failure with hypoxia and hypoxemia. That day, he was also seen by Dr. [REDACTED], who cleared him for discharge on home oxygen and a follow-up to outpatient pulmonary clinic, since Mr. Xxxxxx's condition had been stable. He was placed off work.

Mr. Xxxxxx saw Dr. [REDACTED] on [REDACTED] and reported that he was doing well with his O2 which he used most of the time when walking around. Pulmonary follow-up was recommended.

On [REDACTED], he saw Dr. [REDACTED] for his recurrent polycythemia, increased serum ferritin, respiratory insufficiency and transaminitis. CT scan of neck, chest, abdomen and pelvis was ordered. After that, Dr. [REDACTED] saw him on [REDACTED] for follow-up of his pulmonary alveolar proteinosis. He reported partial relief from his whole lung lavage and that he was still on

oxygen at 3-4 liters with any activity. Vocal cord dysfunction was diagnosed. Laboratory tests were performed. He continued to follow up with Dr. [REDACTED].

On [REDACTED], he underwent bronchoscopy/laser bronchoscopy with APC under general anesthesia LMA ventilation, laryngeal/bronchoscopy with Dr. [REDACTED]. He then had tracheal nodule biopsy which revealed inflamed granulation tissue and fibrinoid exudates with prominent cautery/crushed artifact without evidence of malignancy. A CT of the chest dated [REDACTED] showed decreased alveolar proteinosis. He remained off work.

On [REDACTED], he had pulmonary function test showing mild restrictive physiology without significant bronchodilator response and mild effusion impairment which were compatible with his clinical diagnosis of pulmonary alveolar proteinosis.

His speech evaluation complex cine video dated [REDACTED] showed no evidence of frank aspiration or deep laryngeal penetration.

On [REDACTED], Mr. Xxxxxx followed up with Dr. [REDACTED] regarding his pulmonary alveolar proteinosis, throat pain and chronic hoarseness. Valium was prescribed. Bronchoscopy was ordered.

On [REDACTED], he underwent video bronchoscopy with Dr. [REDACTED]. Afterwards, he saw Dr. [REDACTED] complaining of hypoxia with walking, talking and any exertion. His O2 sat at home dropped to 80s. His disability was discussed and extended until [REDACTED]. He continued to follow up with Dr. [REDACTED], who ordered portable oxygen concentrator. On [REDACTED], he had a sleep study which showed moderate obstructive sleep apnea.

On [REDACTED], he presented to Dr. [REDACTED] for follow-up after his large volume lavage on ECMO. During this visit, Mr. Xxxxxx related that he underwent a whole lung lavage on ECMO on [REDACTED] at UCSF and then 2 days later he was decannulated and was transferred back to the OSH for extubation; subsequently underwent 2 other whole lung lavages on [REDACTED] or [REDACTED] and on [REDACTED]. He remained stable. A 6-month PFTs was recommended.

On [REDACTED], Dr. [REDACTED] issued a statement that Mr. Xxxxxx was unable to perform the activities of a Park Ranger due to his pulmonary alveolar proteinosis with hypoxia dependent on oxygen therapy and that his condition was permanent. Therefore, on [REDACTED], Mr. Xxxxxx applied for non-service-connected disability retirement.

On [REDACTED], he saw Nurse Practitioner [REDACTED] due to cough, voice hoarseness, acute non-recurrent maxillary sinusitis and left-sided numbness and tingling. He was then referred to ER and to see an ENT. That same day, he was admitted for sepsis/paresthesia and was discharged on [REDACTED].

On [REDACTED], he saw Dr. [REDACTED] regarding his sepsis, hyponatremia, right lower lobe lung mass, brain abscess, type 2 diabetes mellitus with hyperglycemia, pulmonary alveolar proteinosis, pneumonia of right lower lobe due to infectious organism and essential hypertension. Laboratory tests were ordered.

On [REDACTED], Mr. Xxxxxx was medically terminated from his employment with the County of Yyyyyy as a [REDACTED]. Afterward, he saw Dr. [REDACTED] on [REDACTED], complaining of an episode of vertigo and balance issues. During this time, his pneumonia/chronic pulmonary disorder was resolving. He then continued seeing Nurse Practitioner [REDACTED] for his medical issues.

On [REDACTED], he underwent right lung lavage. On [REDACTED], he again saw Nurse Practitioner [REDACTED] regarding his complaints of cough with clear phlegm, unchanged chronic shortness of breath, sinus pressure and runny and stuffy nose. ProAir HFA and Augmentin were prescribed. Chest x-ray and laboratory tests were ordered. He was then scheduled for lung lavage on [REDACTED].

**Mmmmm REPORT QUESTIONS:**

1) *Is the member physically and/or mentally incapacitated from substantially performing the usual duties of his job, with or without accommodation, due to the claimed injury(ies) or disease(s)? Please consider the following: "Disability" has been defined as the "substantial inability of the member to perform his usual duties." Inability to perform some of the duties of a position does not render one disabled.*

Yes. The member is physically incapacitated from substantially performing the duties of his job as a [REDACTED], with or without accommodation due the claimed disease. Pulmonary alveolar proteinosis is a chronic progressive disease requiring repeated whole lung lavage. The member has chronic hypoxia and is O2 dependent.

2) *Is the incapacity permanent?*

Yes. The incapacity is permanent with no expectation of resolution or improvement with additional treatment or passage of time. Pulmonary alveolar proteinosis is a life-long disease.

3) *(If applicable) Is the incapacity service connected? If so, please explain the mechanism of injury that is a link between the employment and the incapacity. Please consider the following: Members seeking service-connected disability retirement must produce a preponderance of substantial evidence of a real and measurable work contribution to the claimed injury(ies) or disease(s).*

No. The incapacity is not service connected. There is no real and measurable work contribution.

4) *Is the member able to perform other job duties based on restrictions imposed by his claimed injury(ies) or disease(s)? Please list the specific restrictions and limitations.*

No. The member cannot perform even light office work due to 1) vocal cord dysfunction, which impairs his ability to speak; 2) right hearing loss; 3) cognitive impairment due to repeated episodes of prolonged hypoxemia; 4) risk of serious infection; 5) chronic hypoxia which impairs his ability to do minimal exertion.

5) *Is the member able to perform other work in Yyyyyy County Service?*

No. The member is unable to perform other work in Yyyyyy County Service. As outlined in response to question #4, he has permanent limitations that render him permanently incapacitated.

6) *Is there any evidence that the member's claimed injury(ies) or disease(s) resulted from the member's intemperate use of alcohol or drugs or willful misconduct?*

No. There is no evidence the member's claimed disease resulted from intemperate use of alcohol or drugs or willful misconduct. There is no evidence of any history of alcohol or drug abuse.

7) *(If applicable) If the application date is more than four (4) months after the discontinuation of service date, was the member continuously physically and/or mentally incapacitated for the performance of his usual job duties from the discontinuation of service date to the application date? If so, on what date would you consider him to be permanently incapacitated? Please consider the following: Timeliness of application rules require that when a member applies for disability retirement beyond four (4) months after leaving service, an additional burden of proof is placed on the member to prove through the medical evidence that he was continuously physically and/or mentally incapacitated to substantially perform his duties from the discontinuation of service to the application date.*

The applicant was continuously physically incapacitated for the performance of his usual job duties from the discontinuation of service date to the application date.

8) *Has the member received appropriate treatment for the stated illness/injury? Staying within your specialty, is additional medical or other treatment needed?*

Yes, the member has received appropriate care and will need ongoing treatment for pulmonary alveolar proteinosis.

#### **MEDICAL RECORDS REVIEW:**

Disability Retirement Application - Mr. [REDACTED] Xxxxxx - [REDACTED] Pages 63-71.

Employment Psychological Assessment Result - [REDACTED], Ph.D. - [REDACTED] Pages 113-114. The patient was free from any emotional or mental condition that might adversely affect the exercise of the powers of a peace officer. He was therefore recommended for the position of a Park Ranger 1.

Progress Report - [REDACTED], D.O. - [REDACTED] Pages 385-386. The patient stated that his shingles had improved but he still had occasional light pain. He was taking metoprolol for his blood pressure which read as 170/96 mmHg. Diagnoses: 1. Hypertension. 2. Obesity. 3. Shingles. Hydrochlorothiazide was prescribed. He was to obtain BP machine and to check his BP twice a day.



Progress Report - [REDACTED], D.O. - [REDACTED] Page 387. The patient stated that he was doing well with his BP medications. He had a skin lesion in the past several years which was darker. Assessment: Hypertension. He was to continue taking metoprolol. Lisinopril was prescribed. Excision of skin lesion on his face was recommended.

Progress Report - [REDACTED], D.O. - [REDACTED] Pages 388-389. The patient underwent shave/excision procedure on his face. The area was draped and prepped with BD. Local anesthesia was obtained with perilesional injection of 2% Lidocaine with epinephrine and sodium bicarbonate. The lesion was shaved/excised with 1-mm margins. Dressing/surgical was applied and he was advised regarding wound care.

Surgical Pathology - [REDACTED] M.D. - [REDACTED] Pages 390-392. Diagnosis: Skin, right eyelid, shave biopsy – Verruca.

Progress Report - [REDACTED], D.O. - [REDACTED] Pages 393-395. The patient was seen for complete physical exam. Currently, he complained of nocturia, foot/heel pain and obesity. Diagnosis: Routine general medical examination at a health care facility. Laboratory tests were ordered. Weight issue was discussed.

Progress Report - [REDACTED], D.O. - [REDACTED] Pages 396-397. The patient presented for his test results. He was taking Toprol and lisinopril. Diagnosis: Elevated LFTs. Findings: 1. Hypertension. 2. Obesity, class III, BMI 40-49.9 (morbid obesity) (HCC). 3. Hyperglycemia. 4. Dyslipidemia. His BP was well controlled with his meds. He was advised regarding potential health risks of obesity. Options for weight loss programs were discussed as well as various diet routines and exercise. He would review options and pursue a weight reduction program. He was advised potential for T2DM and attendant risk factors for end-organ damage. Dietician referral was recommended. Fenofibrate and atorvastatin were prescribed.

Office Visit - [REDACTED], N.P. - [REDACTED] Pages 407-408. The patient was seen for recheck of his BP. He stated that he ran out of meds more than one month ago. He also stated that he had times of dry cough and had used his son's inhaler with relief. He worked mostly outdoors. He had not taken anything for allergies. Diagnoses: 1. Essential hypertension with goal blood pressure less than 140/90. 2. Dyslipidemia. 3. Essential hypertension. 4. Cough. Lipitor, Lofibra, lisinopril, Toprol XL and levalbuterol were prescribed. He was to begin daily over-the-counter Claritin or Allegra.

Office Visit - [REDACTED], N.P. - [REDACTED] Pages 409-411. The patient presented with dry cough and shortness of breath for 4 days with low-grade fever and sinus pressure. He stated that for the past week, he had been running a low-grade fever. He had sinus pressure and pain, nasal congestion, post nasal drip, vocal hoarseness and mostly non-productive cough. He was experiencing episodes of dyspnea with coughing as well as with exertion. Over-the-counter medications were providing no relief. Assessment: 1. Upper respiratory tract infection, unspecified type. 2. Cough. Azithromycin and albuterol sulfate HFA were prescribed.

Revised Job Description for a [REDACTED] - Yyyyyy County - [REDACTED] Pages 73-77. A [REDACTED] performed duties related to law enforcement, visitor services, interpretive programs, resource and wildlife protection, safety enforcement, pollution control, public relations and fee collection for the County [REDACTED] System. This job entailed patrolling park areas by foot, bicycle, motorcycle, boat and/or motor vehicle to provide visitor services and to prevent vandalism, area misuse or other undesirable activities; identifying and when possible reducing and eliminating safety hazards; performing rescue and enforcement operations in rough terrain and/or in the American River and other waterways; rendering first aid in emergency situations; assisting in administration of a park area by assisting in development of operating plans and policies, to maximize enjoyment and safety of visiting public while efficiently using available resources, and performing minor maintenance tasks such as picking up trash and removing obstacles from trails.

Office Visit - [REDACTED], D.O. - [REDACTED] Pages 412-414. The patient was seen for physical exam. He complained of recurrent low back pain and right leg pain. Impression: 1. Sciatica. 2. Possible degenerative disc disease. 3. Possible lumbar radiculopathy. Diagnoses: 1. Right leg pain. 2. Low back pain, unspecified back pain laterality, unspecified chronicity, with sciatica presence unspecified. 3. Routine general medical examination at a health care facility. Laboratory tests, Insure kit and ECG were ordered as well as x-ray of the lumbar spine. Physical therapy was recommended. Gabapentin was prescribed.

Office Visit - [REDACTED], D.O. - [REDACTED] Pages 416-418. The patient presented for his test results. He was taking Lipitor, fenofibrate, lisinopril, Toprol XL, Neurontin, ProAir HFA and Xopenex HFA. Diagnoses: 1. Other abnormal blood chemistry. 2. Essential hypertension. 3. Obesity, Class III, BMI 40-49.9 (morbid obesity) (HCC). 4. Hyperglycemia. 5. Dyslipidemia. 6. Lumbar degenerative disc disease. Findings: 1. Dyslipidemia. 2. Lumbar degenerative disc disease. 3. Hypertension. 4. Obesity, Class III, BMI 40-49.9 (morbid obesity) (HCC). 5. Hyperglycemia. Amlodipine and Lyrica were prescribed. Laboratory tests were ordered.

Cytopathology Report - [REDACTED], M.D. - [REDACTED] Page 327. Diagnosis: Bronchial washings, thin prep cytology and cell block – 1. Few benign bronchial epithelial cells. 2. Alveolar macrophages. 3. No pneumocystis organisms identified on GMS special stain. 4. No malignancy seen.

Pulmonary ICU General Progress Note - [REDACTED], D.O. - [REDACTED] Pages 365-369. The patient stated that he felt much better. He was down to a 4 L nasal cannula. He still had some shortness of breath but overall, he had significantly improved. Assessment: 1. Acute hypoxemic respiratory failure. 2. Hyperglycemia. 3. Pneumonia due to infectious organism. 4. Leukocytosis. 5. Polycythemia. Option of open lung biopsy during this hospitalization versus empiric treatment with steroids for the next couple of months and repeat CT scan were discussed. He opted for going home on steroids and following up with Dr. [REDACTED]. IV Solu-Medrol was changed to prednisone. Tapering steroids was recommended. Repeat CT of the chest without contrast was ordered. He would be discharged to home on [REDACTED]. His case was discussed with Dr. [REDACTED]. He was to follow up in 4-6 weeks.

Discharge Summary - [REDACTED], M.D. - [REDACTED] Pages 370-376. Final Diagnoses: 1. Acute hypoxemic respiratory failure. 2. Hyperglycemia. 3. Pneumonia due to infectious organism. 4. Leukocytosis. 5. Polycythemia. The patient was admitted on [REDACTED] due to worsening shortness of breath and dry cough for 9 months. When he arrived at the emergency department, his chest x-ray showed diffuse bilateral ground glass and reticular opacities. He was admitted to telemetry floor and placed on pneumonia pathway. CT of the chest with contrast was obtained, which showed extensive bilateral alveolar opacities with moderate focal consolidation in the left lower lobe. He was placed on Solu-Medrol and IV antibiotics. Pulmonary consult was obtained and he underwent bronchoscopy. HIV, hepatitis panel, ANA, ACE level, and hypersensitivity panel were negative. His cytology came back negative for pneumocystis carinii or malignancy from bronchial washings. His blood and respiratory chest x-ray were negative so far. He would be discharged on prednisone with low taper of 10mg every 2 weeks. He would also continue oral Levaquin to complete a course of 14 days. He was to follow up with a pulmonologist in 4-6 weeks with repeat CT chest. If he continued to have symptoms or infiltrates, he would need a biopsy. Physical activity as tolerated and low-salt and diabetic diet were recommended. He was discharged to home.

Medical Report - [REDACTED], D.O. - [REDACTED] Page 133. The patient was excused from work starting 08/04/17 thru 11/07/17.

Progress Report - [REDACTED] M.D. - [REDACTED] Pages 377-381. The patient presented with shortness of breath upon exertion. He had an episode of near syncope once while in higher elevation. He had been having gradual progressive dyspnea over 9 months. His symptoms were worse. He also had been having chest tightness, intermittent with ambulation. He had trace edema. Assessment: 1. Dyspnea. 2. Chest tightness. 3. Polycythemia. 4. Hypertension. 5. Diabetes mellitus. 6. Dyslipidemia. CT of the chest HR, PFT with DLCO were recommended as well as Lexi scan stress perfusion study. He was to continue on metoprolol, amlodipine, losartan and atorvastatin. He was to follow up in 1 month.

CT of the Chest with Contrast - [REDACTED], M.D. - [REDACTED] Pages 272-273. Impression: Improving bilateral parenchymal opacities, with residual bilateral crazy paving. Dense consolidation within lower lobes had essentially resolved. There had also been resolution of borderline mediastinal lymphadenopathy. Pulmonary findings remained nonspecific. Considerations included resolving pulmonary infection, eosinophilic pneumonia, noncardiogenic edema and alveolar hemorrhage. Given clinical scenario, ARDS or acute interstitial pneumonia were considered less likely. Crazy paving pattern had also been classically described with alveolar proteinosis.

Progress Report (Incomplete Copy) - [REDACTED], M.D. - [REDACTED] Pages 178-179. The patient's CT of the chest on [REDACTED] showed extensive bilateral alveolar opacities with moderate focal consolidation in the left lower lobe were nonspecific but might represent pneumonia or edema, with underlying neoplasm especially in the left lower lobe not entirely excluded. No evidence of pulmonary embolism. Assessment: 1. Respiratory failure. 2. Ex-smoker. 3. Polycythemia. 4. Transaminitis. 5. Hypertension. 6. Diabetes mellitus. 7. Dyslipidemia. He was to follow up with Pulmonology. He was to continue using portable home oxygen and to continue to abstain from smoking. Repeat CT of the chest and CT scan of the

abdomen/pelvis or PET scan were ordered as well as laboratory tests. He was to avoid hepatotoxic medications. He was to follow up with liver function tests. As needed abdominal ultrasound or GI evaluation was recommended. He was to follow up with his primary care physician.

Laboratory Report - [REDACTED] Medical Center Laboratory - [REDACTED] Pages 311-312.  
Gamma glutamyl transferase was high.

Laboratory Report - [REDACTED] Medical Center Laboratory - [REDACTED] Pages 315-316.  
Lactate dehydrogenase was high.

Laboratory Report - [REDACTED] Medical Center Laboratory - [REDACTED] Pages 319-320.  
Comprehensive metabolic panel with GFR showed low sodium and high glucose, alkaline phosphatase, AST and ALT.

Laboratory Report - [REDACTED] Medical Center Laboratory - [REDACTED] Pages 323-324. CBC with manual differential showed high WBC, RBC, hemoglobin, MCHC, neutrophil and low lymphocyte.

Consultation - [REDACTED], M.D. - [REDACTED] Pages 382-384. The patient was seen for his polycythemia. He was an ex-smoker. He smoked 1 pack of cigarettes a month for 26 years and quit earlier this year. He also has a history of hypertension, diabetes mellitus, and dyslipidemia. He had been admitted to the hospital recently due to respiratory failure. He was treated empirically with antibiotics for pneumonia. He was on tapering dose of prednisone. He had a bronchoscopy, currently he was on home oxygen. His imaging studies in the hospital had raised concerns about viral pneumonia. Hematology consultation had been requested regarding his elevated hemoglobin and hematocrit. In 5/2017, his hemoglobin and hematocrit were mildly elevated at 16.6 and 46.4 respectively. Currently, in the hospital when he was admitted with pneumonitis and respiratory failure, his hemoglobin and hematocrit had increased to 19.7 and 54.9 respectively. He also had abnormal liver function tests with an alkaline phosphatase of 188 and AST and ALT of 41 and 136. Lipitor and fenofibrate had been discontinued. He was on tapering dose of steroids and his white blood cell count had decreased from 20.2 to 7.7. JAK2 mutation was negative. He has a history of COPD, pneumonia, lumbar spondylosis and obesity. He is allergic to gabapentin. Impression: A 47-year-old male, who was an ex-smoker. He was on portable oxygen for respiratory failure. He was status post bronchoscopy. He had polycythemia, rule out secondary polycythemia; i.e., secondary to his respiratory failure. JAK2 mutation was negative. BCR-ABL was pending. Less likely primary polycythemia vera. He was scheduled to be seen by pulmonology in follow-up for further management of his unexplained respiratory failure. He needed to continue to abstain from smoking. A lung biopsy was considered. He was on tapering dose of Prednisone and portable oxygen. He was to increase his hydration. His blood counts would be monitored closely. If his hematocrit kept rising, he might need temporary weekly phlebotomies to try and bring his hematocrit below 45. BCR ABL result was pending. His liver function tests would be monitored closely. Lipitor had already been held. He was to avoid all hepatotoxic medications. CT scan of the chest, abdomen and pelvis or a PET scan were considered.

NM Myocardial Perfusion Multiple (SPECT) - [REDACTED], M.D. - [REDACTED] Pages 268-269.  
Impression: Normal myocardial perfusion, myocardial perfusion wall motion with an LVEF greater than 70%.

Medical Report - [REDACTED], D.O. - [REDACTED] Pages 229-233. The patient was seen for follow-up of his acute respiratory failure. He complained of hypoxemia. He stated that he was admitted to the hospital longer than a month ago with shortness of breath. He worked in the forestry service department and was frequently outdoors and exposed to a variety of dusts and organic material. On arrival to the ER, he was quite hypoxic and had bilateral pulmonary opacities. He was treated with antibiotics and then had a bronchoscopy which was negative for any microbial entities. Cytology was also negative. He was then started on high-dose steroids for presumed pneumonitis. He improved and was down to 4 L nasal cannula. Plan was for him to get an open lung biopsy but he refused and wanted to go home and try conservative management with prednisone. Currently, he was seen with over 1 month's use of prednisone and actually had no improvement. In fact, he had been worsening over the past day or so and was currently unable to walk across the room without having to stop due to severe shortness of breath. His oxygen saturation was borderline on 5 L nasal cannula. He was positive for snoring, shortness of breath when walking or lying down, shortness of breath and diabetes. He was taking amlodipine, atorvastatin, fenofibrate, furosemide, Janumet, levofloxacin, losartan and prednisone. He also had acute respiratory failure and interstitial pneumonia. He had difficulty walking or climbing stairs. He consumed alcohol. Assessment: 1. Overweight. 2. Acute respiratory failure. 3. Interstitial pneumonia. 4. Hypoxia. 5. Essential hypertension. He was admitted to the hospital. Thoracic surgeon was contacted and he would receive an open lung biopsy as soon as possible.

Thoracic Surgery Consultation - [REDACTED], M.D. - [REDACTED] Pages 363-364. The patient was seen for interstitial lung disease and evaluation for lung biopsy. For the last many months, he had been experiencing progressive dyspnea on exertion that had significantly progressed over the last 4 months. He worked outside as a [REDACTED]. There had been a dry cough. He underwent extensive workup, including trials of steroid and a bronchoscopy, and diagnosis remained elusive. He was readmitted last night with worsening shortness of breath. He was currently comfortable on 3 to 4 L nasal cannula oxygen and request was made for consideration of lung biopsy to further direct therapy. He has a history of hypertension, obesity, type 2 diabetes, hyperlipidemia and interstitial lung disease, hypoxemia requiring supplemental oxygen. He is allergic to gabapentin. He used to smoke 1 pack per month and none recently. Assessment: A 47-year-old male with interstitial lung disease, admitted with hypoxemia. He was to proceed with right-sided thoracoscopy with lung biopsy on [REDACTED]. Procedure was discussed in detail. Preop orders had been written.

Operative Report - [REDACTED], M.D. - [REDACTED] Pages 361-362. Preprocedural and Postprocedural Diagnosis: Interstitial lung disorders. Procedure Performed: Bronchoscopy with aspiration, right-sided video-assisted thoracoscopy with lung biopsy, pulmonary infiltrate.

Surgical Pathology - [REDACTED], M.D. - [REDACTED] Pages 308-309. Diagnosis: 1. Right lung, middle lobe, wedge biopsy – Consistent with pulmonary alveolar proteinosis. 2. Right lung, upper lobe, wedge biopsy – Consistent with pulmonary alveolar proteinosis.

NIVL Venous Duplex Right Upper Extremity - [REDACTED], D.O. - [REDACTED] Pages 266-267. Impression: No DVT evident right upper extremity. Right PICC line catheter noted.

CT of the Chest without Contrast - [REDACTED], M.D. - [REDACTED] Pages 258-259. Impression: 1. Diffuse ground glass density and interlobular septal thickening with subpleural sparing in both lungs, involving all lobes. 2. Interval decrease in previously seen dense consolidation in both lower lungs on [REDACTED]. 3. Postsurgical changes in the posterior right upper lobe with associated more dense opacity. Right lower lobe dense oval nodule measures 8 mm. Attention on follow-up. CT dose index 32.89 mGy. Total exam dose length product for a 1286.11 mGy-cm.

Chest X-ray - [REDACTED], M.D. - [REDACTED] Pages 251-252. Impression: Stable postsurgical appearance of the right lung and background interstitial lung disease consistent with the given clinical history of pulmonary alveolar proteinosis.

Bronchoscopy Operative Note - [REDACTED], M.D. - [REDACTED] Pages 359-360.  
Preoperative Diagnosis: Pulmonary alveolar proteinosis. Postoperative Diagnosis: Pulmonary alveolar proteinosis with therapeutic irrigation from the left apical posterior segment, left lower lobe superior basilar segment and left lower lobe posterior basilar segment. Procedure Name: Selective left lung therapeutic bronchoalveolar lavage.

PMA Progress Note - [REDACTED], M.D. - [REDACTED] Pages 351-354. The patient was seen for follow-up of his pulmonary alveolar proteinosis with persistent hypoxemia. Two days ago, Dr. [REDACTED] did a selective right lung therapeutic lavage. There was noticeable clearing of the cloudiness of the fluid coming from the right middle lobe today compared to [REDACTED]. He was doing much better and was only on 2 L of oxygen. He was able to ambulate around the nursing station. Assessment: 1. Pulmonary alveolar proteinosis (HCC). 2. Obesity, class III, BMI 40-49.9 (morbid obesity) (HCC). 3. Pneumonia due to infectious organism, Acinetobacter. 4. Acute on chronic respiratory failure with hypoxia (HCC). 5. Hypoxemia. He would be discharged to home with supplemental oxygen. He was to follow up with pulmonary medicine associates.

Discharge Summary - [REDACTED], M.D. - [REDACTED] Pages 355-358. Final Diagnoses: 1. Pulmonary alveolar proteinosis. 2. Acute on chronic respiratory failure with hypoxia. 3. Essential hypertension. 4. Diabetes mellitus type 2. 5. Pneumonia due to Acinetobacter. 6. Hyponatremia, resolved. The patient was admitted for pulmonary alveolar proteinosis which was confirmed by operative lung biopsy. He was transferred to UC San Francisco and underwent bilateral lung lavage. He returned here on mechanical ventilatory support but was extubated on [REDACTED]. He was also diagnosed with bacterial pneumonia likely due to Acinetobacter. He completed the course of antibiotic with IV cefepime. He underwent right lung therapeutic bronchoalveolar lavage on [REDACTED] and selective left lung therapeutic bronchoalveolar lavage on [REDACTED]. His respiratory status was partially improved with this intervention. He otherwise remained in stable condition and was cleared for discharge on home oxygen by Dr. [REDACTED]. He was recommended to follow up with his primary care physician within a week and to follow up with outpatient pulmonary clinic in 2-3 weeks. He was discharged in stable condition.

Medical Report - [REDACTED], D.O. - [REDACTED] Page 130. The patient was to remain off work until [REDACTED].

Office Visit - [REDACTED], N.P. - [REDACTED] Pages 420-425. The patient was seen for follow-up from hospital. He had been admitted on [REDACTED] and was discharged on [REDACTED]. Currently, he was feeling better. He had chronic shortness of breath with exertion but improved after the lung lavages he had done at USCF. He was told there would be another lung lavage to be done in 3 weeks. He had a slight cough, non-production. He was positive for fatigue, cough and shortness of breath (chronic shortness of breath had improved since lung lavages).  
Assessment: 1. Pulmonary alveolar proteinosis determined by biopsy of lung. 2. Abnormal liver function. 3. Acute hypoxemic respiratory failure (HCC). 4. Polycythemia. 5. Type 2 diabetes mellitus with complication, with long-term current use of insulin (HCC). 6. Essential hypertension. 7. Abnormal CT scan of chest. He was to follow up with pulmonologist. GI referral was given. He was advised to follow up with Dr. Reddy. He was to continue with his current regimen. Thyroid ultrasound was ordered.

Laboratory Report - [REDACTED] Medical Center Laboratory - [REDACTED] Pages 186-189. Comprehensive metabolic panel with GFR showed low potassium, BUN and high chloride, glucose and AST. Lactate dehydrogenase was high. Ferritin was high. Uric acid was within normal limits. GGT was high.

Fluorescence in Situ Hybridization (FISH) Report - [REDACTED], Ph.D. - [REDACTED] Pages 190-191. Interpretation: Fluorescence in situ hybridization (FISH) analysis was performed on the patient's specimen using DNA probes for BCR/ABL 1 ASS1. Two hundred interphase nuclei were examined and the signal patterns did not reveal any assay specific abnormalities. Based on the performance characteristics established on this assay, all test values were within the normal reference range. Genetic changes other than those assayed here could not be ruled out on the basis of this testing. Correlation with cytogenetic, clinical and pathological findings was suggested for a complete interpretation of the results.

Chest X-ray - [REDACTED], M.D. - [REDACTED] Pages 249-250. Impression: 1. Postoperative changes of the right upper lung. 2. Diffuse interstitial prominence was consistent with the given diagnosis of alveolar proteinosis. 3. No radiographic evidence of pneumonia.

Laboratory Report - [REDACTED] Medical Center Laboratory - [REDACTED] Pages 296-297. CBC with manual differential showed low RBC, hemoglobin, hematocrit, lymphocyte and high metamyelocyte.

Progress Report - [REDACTED], M.D. - [REDACTED] Pages 180-181. The patient was seen for his respiratory failure. He was status post bronchoscopy and antibiotics. He was on tapering doses of Prednisone and portable oxygen. He was due for his pulmonology follow-up. He was an ex-smoker. He had polycythemia probably secondary to his respiratory failure and for being an ex-smoker, less likely polycythemia vera/myeloproliferative neoplasm. His JAK2 was negative. He also had transaminitis. Lipitor was on hold. His viral hepatitis profile was negative. His liver function tests were getting better. He also had hypertension, diabetes mellitus and dyslipidemia. He was feeling cold easily and was on iron. Assessment: 1. Resolved polycythemia/mild anemia. 2. Increased serum ferritin. 3. Respiratory insufficiency. 4. Resolved transaminitis. 5. Cold sensitivity, rule out thyroid insufficiency. Pulmonology follow-up was recommended. He was to

decrease iron intake. Laboratory tests, thyroid function test and CT of the chest, abdomen and pelvis were ordered. He was to follow up with BCR-ABL result. KCl was prescribed.

Medical Report - [REDACTED], D.O. - [REDACTED] Pages 227-229. The patient was seen for his lab results. He stated that he had been admitted to the hospital a couple of months ago with shortness of breath. He worked in the forestry service department and was frequently outdoors and exposed to a variety of dusts and organic material. On arrival to the ER, he was quite hypoxic and had bilateral pulmonary opacities. He was treated with antibiotics and then had a bronchoscopy which was negative for any microbial entities. Cytology was also negative. He was then started on high-dose steroids for presumed pneumonitis. He improved and was down to 4 L nasal cannula. Plan was for him to get an open lung biopsy but he refused and wanted to go home and try conservative management with prednisone. He came back to clinic and was in extremis and sent to the ER. He had a lung biopsy which confirmed alveolar proteinosis and was sent to UCSF for whole lung lavage. He returned to SRMC and had another semi whole lung lavage. He was down to 3 liters NC and sent home. He again presents today on 4 L NC. He looked much better than the last time he was seen in clinic but he still had shortness of breath and difficulty with fatigue. He had no other complaints currently. Assessment: 1. Pulmonary alveolar proteinosis. 2. Hypoxia. 3. Acute respiratory failure. 4. Obesity. Six-minute walk test was performed and he walked a total of 480 feet. 120 feet on room air 360 on 2 L oxygen. Repeat lavage was recommended. Dr. [REDACTED] was working on scheduling this procedure. In the meantime, he tried an oxywalk today and he still required about 4 L NC to keep O2 sats up. He was to return in 1 month for post lavage follow-up.

CT of the Chest without Contrast - [REDACTED], M.D. - [REDACTED] Pages 247-248.  
Impression: Within the limits of the examination, negative for pulmonary artery embolism. No significant interval change in the extensive interstitial infiltrates and bilateral trace pleural effusions. Radiographic findings were consistent with alveolar proteinosis. Total exam dose length product: 697 mGy-cm. Total exam CT dose index: 19, 101, 63, 16 mGy.

Medical Report - [REDACTED], M.D. - [REDACTED] Pages 224-226. The patient was seen for follow-up on pulmonary alveolar proteinosis. Since he was last seen, he called complaining of worsening shortness of breath and Dr. [REDACTED] did a direct admission into the hospital for whole lung lavage. They did whole lung lavage on the right lung and brain to get 10 L of saline lavage before the double-lumen endotracheal tube slipped out of the left mainstem and saline started to leak into the left lung. At that point, the procedure was discontinued and the rest of the saline was suctioned from the right lung. He remained intubated and was sent to the intensive care unit afterwards. He was extubated the next day and eventually sent home on 4 L nasal cannula which appeared to be his baseline. He was currently here for follow-up after the hospitalization. He had done well since he was discharged. He had more energy and was able to ambulate much further and much faster. He was still complaining of some voice hoarseness after the intubation recently. He had no other complaints. Assessment: 1. Pulmonary alveolar proteinosis. 2. Elevated blood pressure. 3. Hypoxia. 4. Acute respiratory failure. 5. Obesity. 6. Essential hypertension. At this point, Dr. [REDACTED] felt like the patient would benefit from repeat bronchoscopies with targeted localized in the upper lobes. He had a CT scan done in the hospital which demonstrated a significant burden of peripheral ground glass opacities predominantly in the upper lobes. They were waiting on G-CSF antibodies to determine if he



would benefit from Neupogen therapy. In the meantime, he was to continue on his current levels of oxygen. Dr. [REDACTED] would support the patient's transfer of care to UCSF.

Office Visit - [REDACTED], D.O. - [REDACTED] Pages 426-429. The patient was known to the pulmonary medical associates service due to pulmonary alveolar proteinosis. He was first hospitalized for this on [REDACTED] and underwent bronchoscopy on [REDACTED] which showed a large amount of proteinaceous debris on bronchoalveolar lavage. The cultures were negative for infectious organisms and he seemed to respond initially to corticosteroid therapy and was subsequently discharged home at his request. He deteriorated at home and was re-hospitalized on [REDACTED]. With this hospitalization, a thoracic surgery consultation was obtained and he underwent operative lung biopsy on [REDACTED] which was diagnostic for pulmonary alveolar proteinosis. He then developed progressive respiratory failure and ultimately transferred to UC San Francisco on [REDACTED] wherein he underwent whole lung lavage, with ECMO support. Both lungs were done during that hospital stay (1 at a time with a few days respite in between). He was readmitted as part of the takeback agreement from UC San Francisco on [REDACTED] and remained at [REDACTED] until discharge on [REDACTED]. During the course of his remaining hospital stay, he underwent physical therapy and rehabilitation. Dr. [REDACTED] performed some therapeutic bronchoscopy with washing 2 days in a row prior to his discharge which seemed to improve his gas exchange. They were planning on elective admission to the hospital on [REDACTED] to undergo whole lung lavage. In the meantime, he contacted Dr. [REDACTED] and informed her that he was getting more breathless with activity and started to have increased cough again. During hospital course, he underwent whole lung lavage on [REDACTED] in the OR. Postoperatively, he was quite hypoxic and therefore kept on the ventilator overnight. On the following day, he was extubated. After that, he had stridor for which he was given racemic epinephrine as well as a couple of doses of Decadron. Currently, he felt much better and was back down to 4 L oxygen which was baseline. CTA of the chest was obtained and there was no PE detected and continued to have changes of ILD with crazy paving consistent with PAP. He was otherwise deemed to be stable for discharge home. He planned on following up with Dr. [REDACTED] next week. Discharge Diagnosis: Pulmonary alveolar proteinosis. Impression: Hypertension, uncontrolled. He was to follow up at UCSF as ordered. Losartan was increased to 50 mg per day. LFTs were ordered. Visit Diagnoses: 1. Essential hypertension. 2. Obesity, Class III, BMI 40-49.9 (morbid obesity) (HCC). 3. Pulmonary alveolar proteinosis determined by biopsy of lung. 4. Hypoxemia. 5. Polycythemia. 6. Acute hypoxemic respiratory failure (HCC).

Office Visit - [REDACTED], N.P. - [REDACTED] Pages 244-246. The patient stated that he was not taking his BPs at home. He was positive for unexpected weight change. Assessment: 1. Hypertension, unspecified type, uncontrolled. 2. Pulmonary alveolar proteinosis (HCC). 3. Hypoxemia. He was advised to do labs in 7-10 days after starting losartan/HCTZ. Laboratory tests were ordered. For his pulmonary alveolar proteinosis, he was recommended to have a 6-minute walk test every 3 months and full PFTs with DLCO every 6 months by Dr. [REDACTED]. He had appointment with PMA pulmonologist this month. For his hypoxemia, he stated that had not been using his oxygen and his O2 sat at rest was okay, but Ms. Stephens walked him around the clinic and his O2 sat dropped to 88%, so he was advised to start using his oxygen again at 4L via nasal cannula. He was to see pulmonologist next week to do his 6-minute walk test.

Office Visit - [REDACTED], D.O. - [REDACTED] Pages 434-436. The patient was doing well with his O2. He was using O2 most of the time when walking around. His O2 sat when resting average was 95-96%. Assessment: Improved BP control. Pulmonary follow-up was recommended. Visit Diagnoses: 1. Essential hypertension. 2. Pulmonary alveolar proteinosis determined by biopsy of lung. 3. Obesity, Class III, BMI 40-49.9 (morbid obesity) (HCC). 4. Type 2 diabetes mellitus with hyperglycemia, without long-term current use of insulin (HCC).

Laboratory Report - [REDACTED] Medical Center Laboratory - [REDACTED] Pages 288-289. Comprehensive metabolic panel with GFR showed low sodium and high glucose, alkaline phosphatase, AST and ALT.

Medical Report - [REDACTED], D.O. - [REDACTED] Page 108. The patient was excused from work until [REDACTED].

Laboratory Report - [REDACTED] Medical Center Laboratory - [REDACTED] Pages 192-196. Iron and iron binding capacity showed low iron % saturation. Comprehensive metabolic panel with GFR showed low sodium and high glucose, alkaline phosphatase, AST and ALT. CBC with automated differential showed high hemoglobin and hematocrit. Lactate dehydrogenase was high. Uric acid, TSH, free T4 and T3 were within normal limits. Ferritin was high.

Progress Report - [REDACTED], M.D. - [REDACTED] Pages 181-183. The patient complained of headache, fatigue and blurring of vision. Based on increasing hematocrit, he was willing to start weekly phlebotomies to bring his hematocrit back to normal. He wanted to hold off on bone marrow biopsy and CT scan of neck, chest, abdomen and pelvis. Assessment: 1. Recurrent polycythemia. 2. Increased serum ferritin. 3. Respiratory insufficiency. 4. Transaminitis. He was to start phlebotomies. Pulmonology follow-up was recommended. He was to decrease iron intake. As needed CT scan of neck, chest, abdomen and pelvis was ordered as well as bone marrow biopsy and aspiration. Laboratory tests were also ordered.

Medical Report - [REDACTED], M.D. - [REDACTED] Pages 221-223. The patient was seen and examined in follow-up of his pulmonary alveolar proteinosis. Since last visit, he had whole lung lavage on November 1st. He had only partial relief from that and was still on oxygen at 3-4 liters but could be on room air at rest but needed oxygen with any activity. He had hoarseness after the intubation from the last lavage and hoarseness had persisted. He was scheduled to see Dr. [REDACTED] in February. He noted occasional cough with no significant sputum production and had no fevers, chills, night sweats or hemoptysis. Assessment: 1. Pulmonary alveolar proteinosis. 2. Hypoxia. 3. Obesity. 4. Vocal cord dysfunction. Dr. [REDACTED] ambulated the patient 3 times from the office today. This was on room air. He demonstrated a drop in O2 saturations from 98-90% but did not demonstrate hypoxemia. Laboratory tests, bronchoscopy, with bronchial alveolar lavage and CT of the chest without contrast were ordered. He would be evaluated by Dr. [REDACTED] in February.

Laboratory Report - [REDACTED] Oncology Laboratory - [REDACTED] Pages 196-198. Comprehensive metabolic panel with GFR showed low sodium and high glucose, calcium, alkaline phosphatase, AST and ALT. CBC with automated differential showed high hemoglobin and absolute monocyte. Ferritin was high. Iron and iron binding capacity were within normal limits.

Laboratory Report - [REDACTED] Oncology Laboratory - [REDACTED] Pages 199-200. Comprehensive metabolic panel with GFR showed low sodium and high glucose, calcium, alkaline phosphatase, AST and ALT. CBC with automated differential showed high absolute monocyte. Ferritin was high.

Laboratory Report - [REDACTED] Oncology Laboratory - [REDACTED] Pages 201-202. Comprehensive metabolic panel with GFR showed low sodium, potassium and high glucose, calcium, alkaline phosphatase, AST and ALT. CBC with automated differential was within normal limits. Ferritin was high.

Progress Report - [REDACTED], M.D. - [REDACTED] Pages 183-185. The patient was tolerating his weekly phlebotomies well. He had 3 phlebotomies so far. Currently, he had questions regarding hepatic function. Assessment: 1. Recurrent polycythemia, possibly secondary to respiratory insufficiency. 2. Increased serum ferritin. 3. Respiratory insufficiency. 4. Transaminitis. He was to continue phlebotomies. Pulmonology follow-up was ongoing. Repeat CT of the chest was ordered. As needed CT scan of neck, chest, abdomen and pelvis was considered as well as bone marrow biopsy and aspiration. He was to follow up on his laboratory tests as well as with his primary care physician.

Laboratory Report - [REDACTED] Oncology Laboratory - [REDACTED] Pages 203-205. Comprehensive metabolic panel with GFR showed high glucose, alkaline phosphatase and AST. CBC with automated differential showed high absolute monocyte. Lactate dehydrogenase was high. Uric acid was within normal limits. Ferritin was high.

Surgical Pathology - [REDACTED], M.D. - [REDACTED] Pages 285-286. Diagnosis: Tracheal nodule, biopsy – Inflamed granulation tissue and fibrinoid exudates with prominent cautery/crushed artifact; no evidence of malignancy.

Operative Report - [REDACTED], M.D. - [REDACTED] Pages 349-350. Pre-procedure Diagnosis: Malignant neoplasm of trachea. Post-procedure Diagnosis: 5 mm subglottic tracheal nodule. Procedure Performed: Bronchoscopy/laser bronchoscopy with APC under general anesthesia LMA ventilation, laryngeal/bronchoscopy.

Laboratory Report - [REDACTED] Oncology Laboratory - [REDACTED] Pages 206-208. Comprehensive metabolic panel with GFR showed low potassium and high glucose, alkaline phosphatase and AST. CBC with automated differential was within normal limits. Ferritin was high.

CT of the Chest without Contrast - [REDACTED], M.D. - [REDACTED] Pages 241-242. Impression: Findings the alveolar proteinosis were again identified, though appeared decreased from [REDACTED]. No new cardiopulmonary abnormality identified.

Medical Report - [REDACTED], D.O. - [REDACTED] Page 159. The patient was excused from work until [REDACTED].

Laboratory Report - [REDACTED] Medical Center Laboratory - [REDACTED] Pages 208-209. Comprehensive metabolic panel with GFR showed high glucose, alkaline phosphatase and AST. CBC with automated differential showed high absolute monocyte.

Laboratory Report - [REDACTED] Medical Center Laboratory - [REDACTED] Pages 210-211. Comprehensive metabolic panel with GFR showed low sodium, potassium and high glucose, alkaline phosphatase and AST. CBC with automated differential showed low lymphocyte % and high absolute monocyte.

Pulmonary Function Test - [REDACTED], M.D. - [REDACTED] Pages 238-239. Impression: Mild restrictive physiology without significant bronchodilator response and mild effusion impairment. The findings were compatible with the patient's clinical diagnosis of pulmonary alveolar proteinosis.

Medical Report - [REDACTED], D.O. - [REDACTED] Page 122. The patient's disability was being extended to [REDACTED].

XR Speech Evaluation Complex Cine Video - [REDACTED], M.D. - [REDACTED] Pages 236-237. Impression: No evidence of frank aspiration or deep laryngeal penetration.

Medical Report - [REDACTED], M.D. - [REDACTED] Pages 218-220. The patient was seen and examined in follow-up of his pulmonary alveolar proteinosis. He had difficulty with hoarseness which came up following his last lung lavage. He had been evaluated by ENT and was not felt to have any vocal cord dysfunction but was noted to have some mucus sitting on his vocal cords. He underwent a swallow evaluation with speech therapy. This did not show any obvious dysphagia. He had some granulation tissue noted on a prior bronchoscopy and underwent laser fulguration of that by Dr. [REDACTED] in January. He was seen at [REDACTED] regarding his pulmonary alveolar proteinosis and had a CT scan at that facility. This showed areas where there was residual pulmonary alveolar proteinosis involvement but he was not felt to be severe enough to warrant additional lung lavage. Prior to that, they had done a CT scan in January which showed improvement compared to his prior CT scan in November. He also had pulmonary function studies which showed some restrictive physiology which was in keeping with the pulmonary alveolar proteinosis. His main complaint in addition to the persistent hoarseness was a sensation of tightness in his throat. This occurred fairly consistently. There were times where this would be worse. For example, he stated he laughed at a joke recently that made his voice and breathing a tight squeaky sound. Assessment: 1. Pulmonary alveolar proteinosis. 2. Pain in throat. 3. Chronic hoarseness.

Laboratory Report - [REDACTED] Medical Center Laboratory - [REDACTED] Pages 276-283. Fluid cell count was within normal limits. Pneumocystis smear was negative. AFB with smear culture showed no acid fast bacilli isolated in 7 weeks. Fungus culture showed no fungus isolated in 4 weeks.

Cytopathology Report - [REDACTED], M.D. - [REDACTED] Page 284. Diagnosis: Lung, left upper lobe, bronchoalveolar lavage – 1. Inspissated eosinophilic material, pas positive,

compatible with history of pulmonary alveolar proteinosis. 2. Scattered histiocytes. 3. GMS stain negative for pneumocystis or fungal organisms. 4. No malignant cells identified.

Procedure Report - [REDACTED], M.D. - [REDACTED] Pages 336-337. Preoperative Diagnosis: Pulmonary alveolar proteinosis and hoarseness, evaluate for vocal cord dysfunction. Postoperative Diagnosis: Pulmonary alveolar proteinosis and hoarseness, evaluate for vocal cord dysfunction. The patient likely had some degree of vocal cord dyskinesia as at the end of the case and the topical anesthesia from the vocal cords had worn off. He developed some laryngeal spasm of the bronchoscope still in the airway. Procedure Name: Video bronchoscopy.

Medical Report - [REDACTED], D.O. - [REDACTED] Page 140. The patient continued to be on disability until 09/08/18.

Reasonable Accommodation Request for Employees - [REDACTED], D.O. - [REDACTED] Page 85. The patient had a medical condition that limited his major life activity. He had physical impairment. He had limited walking, lifting, breathing, communicating and working. He was to limit walking, talking, climbing and lifting.

Progress Report - [REDACTED], D.O. - [REDACTED] Pages 338-340. The patient complained of hypoxia with walking, talking and any exertion. His O2 sat at home dropped to 80s. He did well when sitting and lying. His problem list included essential hypertension, obesity class III, dyslipidemia, lumbar DDD, pneumonia due to infectious organism, Acinetobacter, leukocytosis, polycythemia, acute hypoxemic respiratory failure (HCC), smoker, transaminitis, respiratory failure (HCC), acute on chronic respiratory failure with hypoxia (HCC), pulmonary alveolar proteinosis determined by biopsy of lung, pulmonary alveolar proteinosis (HCC), hypoxemia, abnormal CT of the chest, pulmonary alveolar proteinosis (HCC), type 2 diabetes mellitus with hyperglycemia and dyspnea on exertion. Assessment: 1. Pulmonary alveolar proteinosis. 2. History of respiratory failure. 3. Per problem list. Disability was discussed. He was unable to work. Forms were completed. He was to recheck as needed.

Medical Report - [REDACTED], D.O. - [REDACTED] Page 166. The patient continued to be on disability until [REDACTED].

Medical Report - [REDACTED], M.D. - [REDACTED] Pages 215-217. The patient was seen and examined in follow-up of pulmonary alveolar proteinosis and persistent hoarseness. He was requesting to be set up for portable oxygen concentrator to help with exercise. He stated that he got short of breath with moderate activity such as climbing stairs or brisk walking. He was hopeful that if he could return to exercising that he might be able to lose weight to help with his breathing. He noted occasional cough. He was evaluated at [REDACTED]. His swallowing and laryngeal structures were evaluated and there was no significant structural abnormality noted. He also had a follow-up CT scan. This showed no worsening of the pulmonary alveolar proteinosis and it was felt he did not need any additional lung lavage. He tried oral Valium to see if that would help with his dyskinesia and spasm multiple ribs. He noted that it made him sleepy but really did not do any good as far as alleviating the tightness sensation in his throat. He also noted occasional cough but no sputum production and no fevers, chills, night sweats or hemoptysis. He stated that he was more short of breath for air quality on the days of the wildfires

last month. Assessment: 1. Pulmonary alveolar proteinosis. 2. Dyspnea on exertion. 3. Vocal cord dysfunction. 4. Obstructive sleep apnea of adult. Portable oxygen concentrator was ordered. Prilosec was prescribed. Home sleep testing was recommended.

Interactive Process Summary – Illegible Signature - [REDACTED] Pages 98-100. Mr. Xxxxxx was currently on an unpaid leave of absence. His first absence from work was [REDACTED]. He currently was not eligible for FMLA/CFRA protection. His situation was challenging because his medical condition appeared with a sudden onset and his physician could not determine a prognosis. His condition had improved greatly over the past year. He had physical limitations and required oxygen treatments that created difficulties performing the duties of a [REDACTED]. He stated on his Reasonable Accommodation request that he had difficulties with walking short and long distances, running, and talking for prolonged periods. He stated during the meeting that he felt he would not be able to return to the [REDACTED] position and he and his wife wanted to discuss other options available to him. Ms. [REDACTED] asked Chief [REDACTED] and Ms. [REDACTED] if there were office-based positions for [REDACTED]. Mr. [REDACTED] explained that there were no full-time office positions for [REDACTED]. Mr. [REDACTED] also explained that for short-term temporary restrictions for [REDACTED], they might be able to provide a temporary accommodation, but there was not full-time office work available for the [REDACTED] classification. Ms. [REDACTED] asked if Mr. Xxxxxx would be interested in possible reassignment through the Accommodation Transfer List (ATL) process. He stated he would be interested in exploring that opportunity. Although Mr. Xxxxxx would like to explore the ATL process, retirement options were also presented and discussed. Mr. Xxxxxx was not yet eligible to apply for service retirement, but he could be eligible to apply for disability retirement due to the duration of his condition. Ms. [REDACTED] advised Mr. Xxxxxx to contact Mmmmm to schedule an appointment with both his Retirement Specialist and Disability Retirement Specialist ([REDACTED]). Social Security Disability was also discussed as a potential option for Mr. Xxxxxx should he decide not to pursue the ATL or if was unable to find a suitable transfer. Mr. Xxxxxx' current medical note expired on 11/09/18 and he was reminded that updated medical documentation would be required even if he was working through the ATL process.

Diagnostic Report - [REDACTED], M.D. - [REDACTED] Pages 234-235. Interpretation: Moderate obstructive sleep apnea.

Office Visit - [REDACTED], D.O. - [REDACTED] Pages 440-443. The patient was seen for complete physical exam. He had chronic shortness of breath and was O2 dependent. Diagnoses: 1. Encounter for general adult medical examination without abnormal findings. 2. Essential hypertension. 3. Elevated liver enzymes. 4. Type 2 diabetes mellitus with hyperglycemia, without long-term current use of insulin. 5. Screening for rectal cancer. Laboratory tests and ECG were ordered. He was referred to endocrinology.

Interventional Pulmonary Clinic Note - [REDACTED], M.D. - [REDACTED] Pages 329-334. The patient was seen for follow-up after large volume lavage on ECMO. He stated that he was transferred to UCSF after developing hypoxemic respiratory failure. He was admitted to [REDACTED] on [REDACTED] with hypoxemia. He had a VATS there, which confirmed PAP; however, post procedurally he did poorly and required intubation and developed a tension pneumothorax. He was transferred to UCSF on [REDACTED] for whole lung lavage. Due to the severity of his

hypoxemia, this required ECMO and he underwent right whole lung lavage on [REDACTED], both on ECMO. He was decannulated 2 days later and then transferred back to the OSH for extubation. Since discharge from the OSH, he had required 2 further whole lung lavages, first on [REDACTED] of [REDACTED] and then on [REDACTED]. It sounded like the second whole lung lavage was difficult due to spillover of fluid into other lung. He worked as a [REDACTED], but was currently on disability. Currently, he continued to be stable. He intermittently used oxygen, but reported that the lowest O2 sat he had seen while off was 88%. He was 95% off oxygen currently in the clinic. He continued to have difficulty with his voice. He had seen an otolaryngologist at [REDACTED] and they had given him voice exercises. He had not had new PFTs or imaging since his last visit. He was positive for malaise/fatigue, cough and shortness of breath as well as weakness. Assessment: A 48-year-old, male who was referred to interventional pulmonary clinic for evaluation and treatment of pulmonary alveolar proteinosis. He underwent a whole lung lavage on ECMO in September and had subsequently undergone 2 other whole lung lavages. A 6-month PFTs was recommended during which he would follow his DLCO. If he developed worsening exertional dyspnea, repeat CT of the chest and possible repeat lavage would be recommended.

Correspondence - [REDACTED], D.O. - [REDACTED] Pages 78-80. Dr. [REDACTED] currently served as the primary treating physician for the patient, who suffered from a severe pulmonary condition, diagnosed as pulmonary alveolar proteinosis. He had required multiple hospitalizations including the need for intubation due to respiratory failure and hypoxemia. He had been admitted to University of [REDACTED] and [REDACTED] hospitals. His pulmonary problems began approximately the beginning of 2004 when he experienced difficulty breathing and shortness of breath with exertion. His first hospitalization for this condition was on [REDACTED] and he was diagnosed at that time with pneumonia. Subsequently, he was hospitalized in [REDACTED] for hypoxemia and respiratory failure that required a lung biopsy, indicating a diagnosis of pulmonary alveolar proteinosis. This required a transfer to the University of [REDACTED] for further treatment including a lung lavage and intubation. He was unable to perform the activities of a [REDACTED] due to significant shortness of breath. Bronchoscopy, intubation, pulmonary lavage and a lung biopsy were performed in 09/2017 with another video bronchoscopy on [REDACTED]. During this time frame, his CT scan of the chest revealed persistent extensive interstitial infiltrates in bilateral trace pleural effusions. The radiographic findings were consistent with pulmonary alveolar proteinosis. He required periodic oxygen at home for shortness of breath and hypoxia as demonstrated by an oximeter. Currently, he was using home oxygen and albuterol inhalers as needed. He could not continue to work in his current occupation due to his pulmonary alveolar proteinosis with hypoxia dependent on oxygen therapy. His disabling disease was permanent. His current work restrictions included no fast walking or running and limited bending and squatting. He was unable to detain or apprehend or arrest another person; unable to physically defend himself against attack or aggression; unable to perform rescues such as swimming and unable to withstand extremely hot or cold conditions. He had been continuously physically incapacitated from performing his work duties since approximately 08/2017. His current disease was not caused by his job and his job did not aggravate his current disease.

Office Visit - [REDACTED], N.P. - [REDACTED] Pages 444-446. The patient complained of wet cough for 5 days, with pinkish phlegm. His temperature at home was at 99-100. He had sinus pressure for 5 days as well as right ear pressure. He also had tingling in the left side of his body

for 5 days and it started gradually in his left foot, then started going up to his left leg, left side of body, left arm and left side of face. He was positive for fever, sinus pressure, voice change, right ear plugged, cough, diarrhea, numbness and headaches. He stated that ever since his intubation for lung lavage (secondary to pulmonary alveolar proteinosis), he had voice hoarseness. He saw an ENT for it. Assessment: 1. Voice hoarseness. 2. Cough. 3. Acute non-recurrent maxillary sinusitis. 4. Left-sided numbness and tingling. He was referred for ER evaluation. ENT referral was recommended.

Office Visit - [REDACTED], D.O. - [REDACTED] Pages 447-455. The patient presented with left-side foot numbness radiating up to his leg/arm and into his face. He had fever, cough for 5 days and dizziness. He was admitted on [REDACTED] for sepsis/paresthesia and was discharged on [REDACTED]. Currently, he complained of right ear hearing loss for 3 weeks with some dizziness, right-sided paresthesias, patchy and fatigue. His FBS at home was 110. His acute hospital medical problems included type 2 diabetes mellitus with hyperglycemia, sepsis, right lower lobe lung mass, pulmonary alveolar proteinosis, pneumonia of right lower lobe due to infectious organism, hyponatremia, essential hypertension and brain abscess. He had pneumonia and possible atypical infection due to his history of PAP. He could have Nocardia and was to continue meropenem and Septra. Infectious versus a neoplastic CITATION-guided biopsy versus bronchoscopy was ordered. He was to continue current treatment with broad spectrum antibiotics and beta blocker. Laboratory tests were ordered as well. He was followed by Neurology and Neurosurgery. Final Diagnoses: 1. Sepsis. 2. Hyponatremia. 3. Right lower lobe lung mass. 4. Brain abscess. 5. Type 2 diabetes mellitus with hyperglycemia, without long-term current use of insulin. 6. Pulmonary alveolar proteinosis. 7. Pneumonia of right lower lobe due to infectious organism. 8. Essential hypertension.

Correspondence - County of Yyyyyy - [REDACTED] Pages 117-118. Mr. Xxxxxx was informed that he was medically terminated from his employment with the County of Yyyyyy as a [REDACTED] with the Department of [REDACTED] as of [REDACTED], in accordance with section 17.6 of his labor agreement between Yyyyyy County and Yyyyyy County [REDACTED]. On [REDACTED], Mr. Xxxxxx was sent a Notice of Proposed Medical Termination that informed him of the Department's intent to medically terminate him from his job as a [REDACTED]. The notice provided a review of Mr. Xxxxxx' situation and he was provided his options regarding his continued employment with Yyyyyy County given his medical condition. Based on the Department's review of the records and all related documents, they concluded that medical termination was appropriate, as Mr. Xxxxxx's disability precluded him from properly performing the essential duties of his job with or without reasonable accommodation. This termination was a non-punitive termination and did not impact his ability to seek future employment with Yyyyyy County.

Office Visit - [REDACTED], D.O. - [REDACTED] Pages 456-459. The patient was seen with episode of vertigo 2 weeks ago and balance issue. He had persistent hearing loss. He had PICC in place. His appetite was good. Assessment: 1. Hearing loss. 2. Vertigo. 3. Resolving pneumonia/chronic pulmonary disorder. 4. Possible resolving brain abscess. 5. Possible thyromegaly. He was scheduled to see pulmonary and neurology physicians. Fatty liver related to obesity was discussed. Dr. [REDACTED] would speak to radiologist regarding thyroid and cardiomegaly.



Office Visit - [REDACTED], N.P. - [REDACTED] Pages 460-463. The patient was seen to discuss his low sodium. He admitted that he continued taking losartan/HCTZ even though he was told to stop it, which might explain why his sodium was low. He was seeing a neurologist, infectious disease and 2 pulmonary doctors. He saw Dr. [REDACTED] for brain abscess. He had repeat MRI of the brain and was seen by Dr. [REDACTED] an infectious disease doctor. He had seen an ENT as he still had problem with his right hearing loss. He was told that his hearing should slowly improve. He stated that 1 month ago, he had CT of the chest and would be having another lavage on [REDACTED]. His oxygen sat was in the 90s or higher. His chronic shortness of breath was unchanged. He was positive for postnasal drip, cough, and chronic voice hoarseness since lavage 2 years ago, and had acid reflux when he ate spicy foods. He was placed on PPI by lung doctor but he noted no change. Assessment: 1. Hyponatremia. 2. Postnasal drip. 3. Essential hypertension. 4. Type 2 diabetes mellitus with hyperglycemia, without long-term current use of insulin. 5. Elevated AST (SGOT). 6. Polycythemia. Laboratory tests and abdominal ultrasound were ordered. Allegra, losartan, Lantus, Lipitor and Janumet were prescribed.

Office Visit - [REDACTED], N.P. - [REDACTED] Pages 464-466. The patient was seen to discuss his labs. He reported that his BP at home was 120/80 mmHg. His FBS was 178-336 and at HS was 189-220. He stopped taking Janumet due to possible cirrhosis of liver. He had lavage on his right lung on [REDACTED] and was due for another lavage next week for his left lung. He was positive for postnasal drip and cough. Assessment: 1. Cholelithiasis without cholecystitis. 2. Abnormal abdominal ultrasound. 3. Microalbuminuria due to type 2 diabetes mellitus. 4. Decreased platelet count. 5. Type 2 diabetes mellitus with hyperglycemia, with long-term current use of insulin. 6. Goiter per CT. 7. Tinea pedis of right foot. Low-fat diet was recommended. Referral to general surgeon was offered but he declined. He was referred to GI, Nephrology, Hematology and Endocrinology. Lotrimin 1% cream and Allegra were prescribed.

Office Visit - [REDACTED], N.P. - [REDACTED] Pages 467-469. The patient complained of cough for 1 week with clear phlegm. His chronic shortness of breath was unchanged. He had runny and stuffy nose for almost 2 weeks. He was getting sinus pressure when leaning forward. He was currently on 14 units of insulin. He was positive for congestion and rhinorrhea and cough. Assessment: 1. Cough. 2. Acute maxillary sinusitis, recurrence not specified. 3. Type 2 diabetes mellitus with hyperglycemia, with long-term current use of insulin. 4. Pulmonary alveolar proteinosis. Proair HFA and Augmentin were prescribed. Chest x-ray and laboratory tests were ordered. He was scheduled for lung lavage on [REDACTED]. He had a referral to see an endocrinologist.

Thank you for the opportunity to evaluate Mr. [REDACTED] Xxxxxx. Please let me know if you have any questions.

---


**Martin Schlüsselberg, M.D.**

---

**Date**

**FOR INFORMATION ONLY**

October 5, 2020

TO: Each Trustee  
Board of RetirementFROM: Ricki Contreras, Division Manager   
Disability Retirement Services

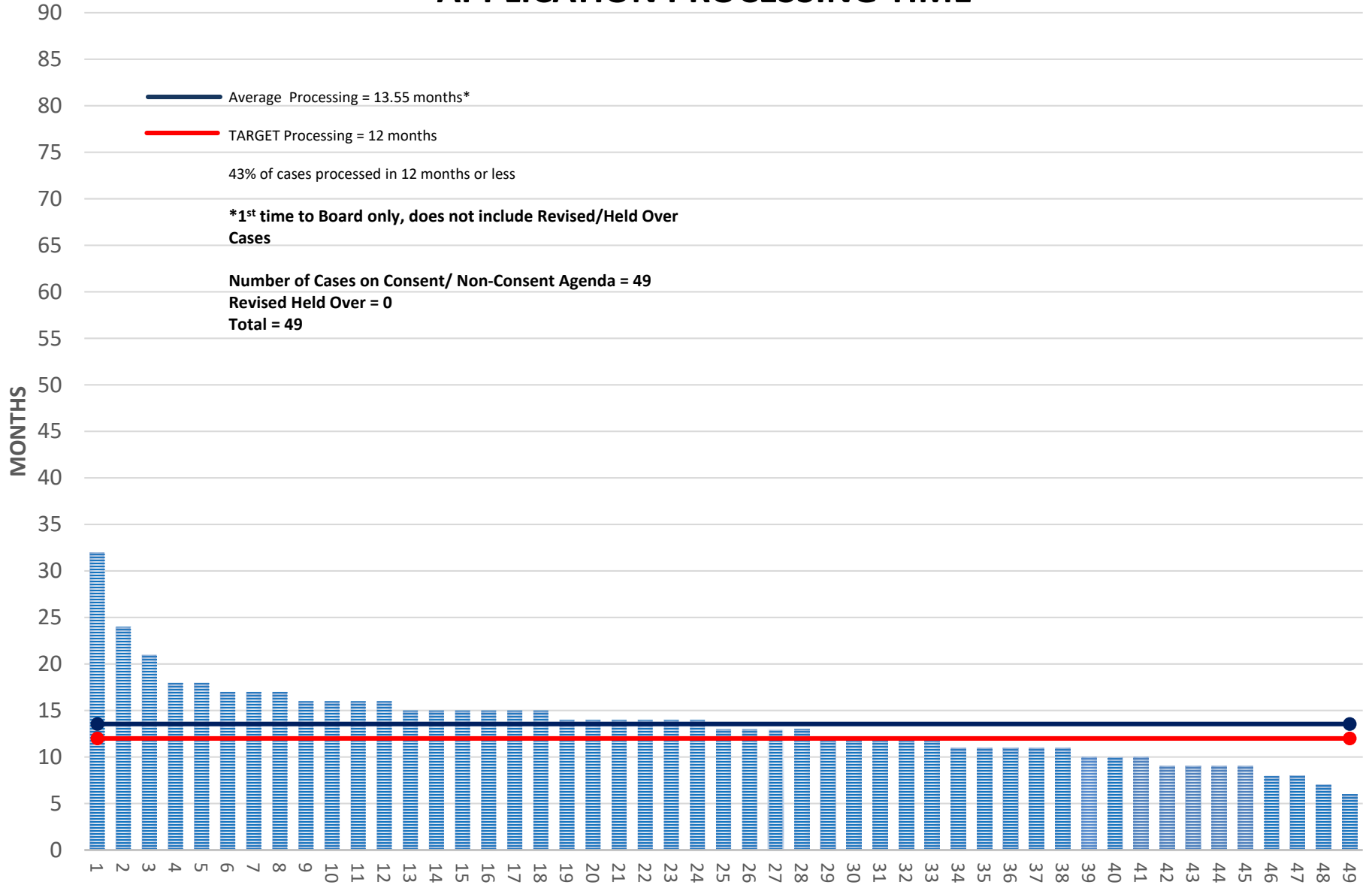
FOR: October 15, 2020 Board of Retirement Meeting

SUBJECT: **Application Processing Time Snapshot Reports**

The following chart shows the total processing time from receipt of the application to the first Board action for all cases on the October 15, 2020 Disability Retirement Applications Agenda.

<b>Consent &amp; Non-Consent Calendar</b>	
Number of Applications	49
Average Processing Time (in Months)	13.55
<b>Revised/Held Over Calendar</b>	
Number of Applications	0
Processing Time Per Case (in Months)	/
<b>Total Average Processing Time All <u>49</u> Cases on Agenda</b>	
	13.55

# DISABILITY RETIREMENT SERVICES APPLICATION PROCESSING TIME



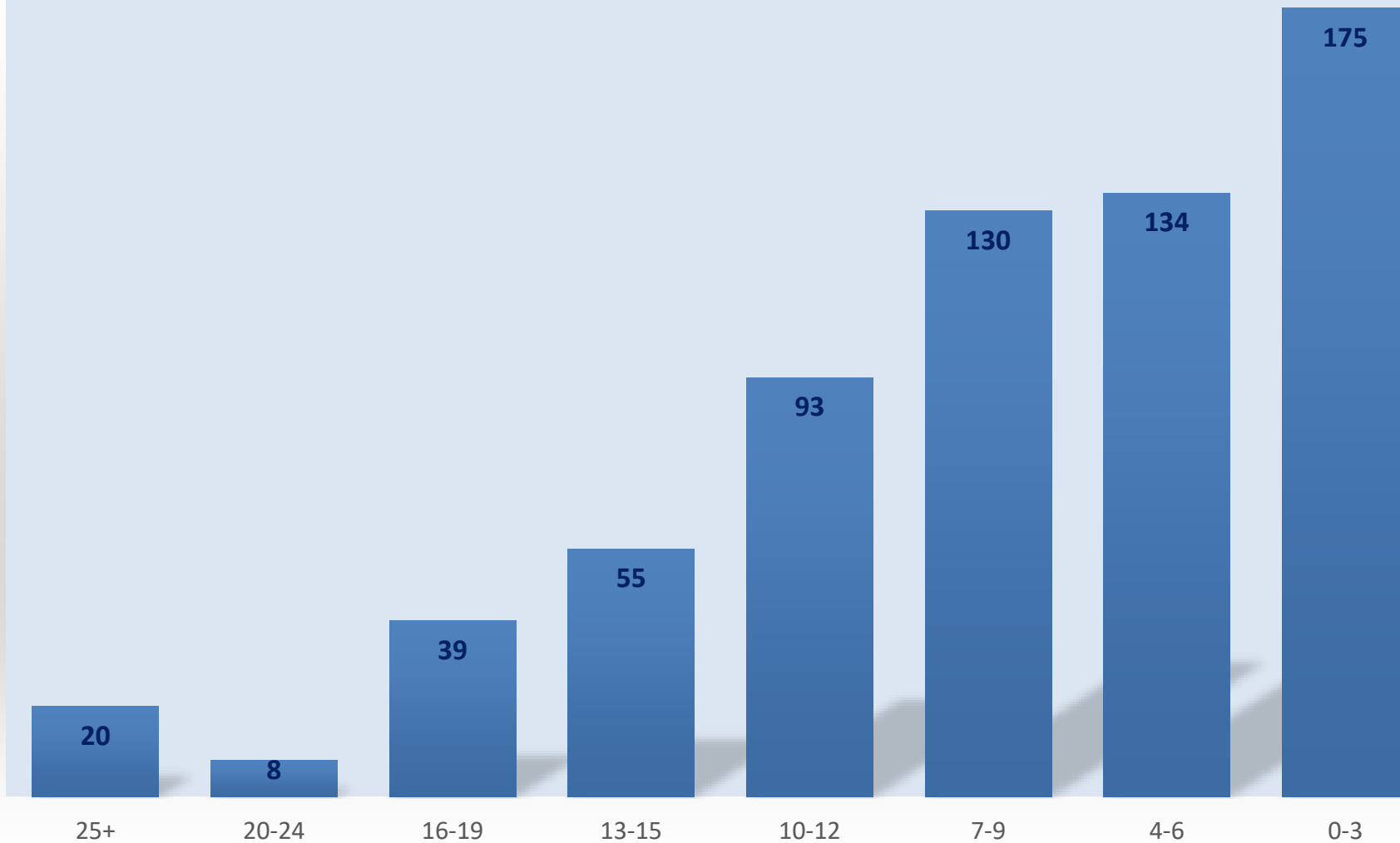
As of September 30, 2020

October 15, 2020 AGENDA

# DISABILITY RETIREMENT SERVICES PENDING APPLICATIONS/TIME INTERVALS

Total Pending Cases = 645

NUMBER OF PENDING APPLICATIONS



As of September 30, 2020



---

**Documents not attached are exempt from disclosure under the California Public Records Act and other legal authority.**

**For further information, contact:  
LACERA  
Attention: Public Records Act Requests  
300 N. Lake Ave., Suite 620  
Pasadena, CA 91101**



---

**Documents not attached are exempt from disclosure under the California Public Records Act and other legal authority.**

**For further information, contact:  
LACERA  
Attention: Public Records Act Requests  
300 N. Lake Ave., Suite 620  
Pasadena, CA 91101**